Cerebral Abscess and Extraaxial Empyema in a Patient with Kartagener Syndrome

Kartagener Sendromlu Hastada Gelişen Serebral Abse ve Ekstraaksiyel Ampiyem

Kartagener Sendromunda Komplikasyonlar / Complications in Kartagener Syndrome

Idil Gunes Tatar, Serdar Korkmaz, Hasan Aydin, Baki Hekimoglu
Diskapi Yildirim Beyazit Training and Research Hospital, Department of Radiology, Ankara, Turkey

Bu vaka 18. Ulusal MR Derneği Toplantısı'da (2013) poster olarak sunulmuştur.

Özet

Situs inversus totalis, bronşektazi ve sinüzit triadı Kartagener sendromu olarak tanımlanmış olup siliopatiler olarak bilinen hastalık gurubundadır. Bu vaka ile 10 yıllık madde bağımlılığı hikâyesi olan Kartagener sendromu tanılı 21 yaşındaki erkek hastada saptanan serebral abse ve ekstraaksiyel ampiyem olgusunu paylaşmaktayız. Hastanın preoperatif BT, MRG bulguları ve postoperatif komplikasyonları sunulmakta olup, primer silier diskineziler klinik ve radyolojik olarak gözden geçirilmektedir. Çocuklarda sık tekrarlayan öksürük, rinit ve otitis media durumunda primer silier diskinezinin ayırıcı tanıda düşünülmesi önemli olup hastalığın erken tanısı kısa ve uzun dönem morbiditeyi etkilemektedir.

Anahtar Kelimeler

Kartagener Sendromu; Siliopati; Serebral Abse; BT; MRG

Abstract

The triad of situs inversus totalis, bronchiectasis and sinusitis is known as Kartagener syndrome which is among the diseases with ciliopathies. Herein we present a case of cerebral abscess and extraaxial empyema detected in a 21-year-old male patient with Kartagener syndrome and a 10-year history of substance abuse. Preoperative CT, MRI findings and postoperative complications are presented with clinical and radiological review of primary ciliary dyskinesia. The consideration of primary ciliary dyskinesia in the differential diagnosis of frequent occurence of cough, rhinitis and otitis media in children is crucial since early diagnosis is known to affect the short term and long term morbidity.

Keywords

Kartagener Syndrome; Ciliopathy; Cerebral Abscess; CT; MRI

DOI: 10.4328/JCAM.2290 Received: 15.01.2014 Accepted: 18.02.2014 Printed: 01.11.2013 J Clin Anal Med 2013;4(suppl 3): 327-9
Corresponding Author: Idil Gunes Tatar, Department of Radiology, Ankara Diskapi Training and Research Hospital, 06110, Diskapi, Altındag, Ankara, Turkey.
T.: +90 3125962600 E-Mail: idilttr@yahoo.com

Introduction

Primary ciliary dyskinesia is an autosomal recessive disorder in which neonatal respiratory stress, recurrent upper and lower respiratory tract infections are common as a result of the disturbance in the mucociliary clearence. Situs inversus totalis and other lateralization anomalies can be seen with half of the cases with primary ciliary dyskinesias [1]. The presence of situs inversus totalis, bronchiectasis and sinusitis triad is known as Kartagener syndrome.

Herein we report a case of 21-year-old male patient diagnosed with Kartagener syndrome who has a 10-year history of substance abuse. The patient was diagnosed with cerebral abscess and extraaxial empyema as a complication of recurrent otitis media.

Case Report

A 21 year-old male patient diagnosed with Kartagener syndrome eight years ago was admitted to the emergency service with fever and loss of consciousness following a recent otitis media attack. The patient had a ten-year history of substance abuse.

The patient underwent cranial CT and MRI. In the cranial CT,subdural effusion with a thickness of 6 mm was detected in the left parietal lobe. Effacement of the cortical sulci in the left cerebral hemisphere and compression of the left lateral ventricle suggestive of brain edema were observed. There was a 5 mm shift of the midline to the right (Figure 1). In the cranial MRI, extraaxial empyema in the left side causing compression to the left lateral ventricle and abscess formations with peripheral contrast enhancement were detected in the left temporal lobe as well as dural contrast enhancement (Figure 2).

The condition was accepted as emergent and the patient underwent surgery in the neurosurgery department. The pathology of the excised lesions in the left temporal lobe was in accordance with abscess and exudative-fibrinous material. After three weeks of postoperative antibiotic treatment cranial MRI was repeated for follow-up. Late subacute phase subdural and cephal hematoma in the left frontotemporoparietal lobe which were communicated with a dural defect were detected. There was also a intraparenchymal hematoma in the left temporal lobe which caused compression of the left lateral ventricle (Figure 3). The patient was discharged when the infection was treated with the suggestion of follow up. At the time of the discharge sensorial aphasia was present.



Figure 1.In the cranial CT subdural effusion with a thickness of 6 mm is detected in the left parietal lobe. Effacement of the cortical sulci in the left cerebral hemisphere and compression of the left lateral ventricle are observed. There is a 5 mm shift of the midline to the right

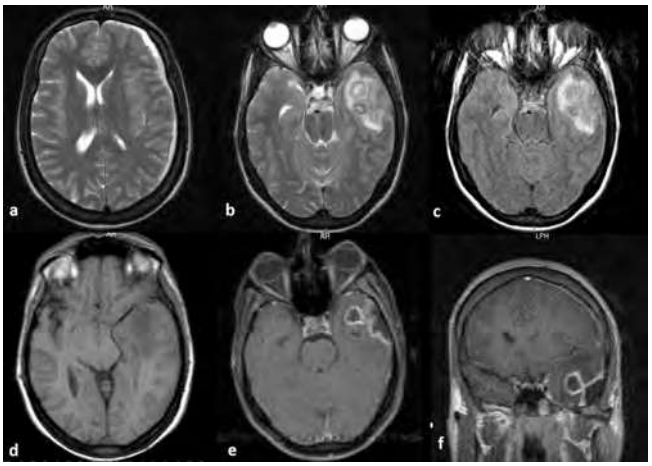

Figure 2.In the preoperative cranial MRI, extraaxial empyema in the left side causing compression to the left lateral ventricle in the axial T2 weighted sequence (a), two hyperintense lesions in the left temporal lobe with a hypointense rim of peripheral edema suggestive of abscess (b) are observed. In axial FLAIR sequence the lesions in the left temporal lobe are hypointense with peripheral edema (c). In the axial T1 weighted sequence hypointensity is seen in the temporal lobe (d), while hypointense lesions with peripheral contrast enhancement and dural contrast enhancement are detected in postcontrast axial (e) and coronal (f) sequences.

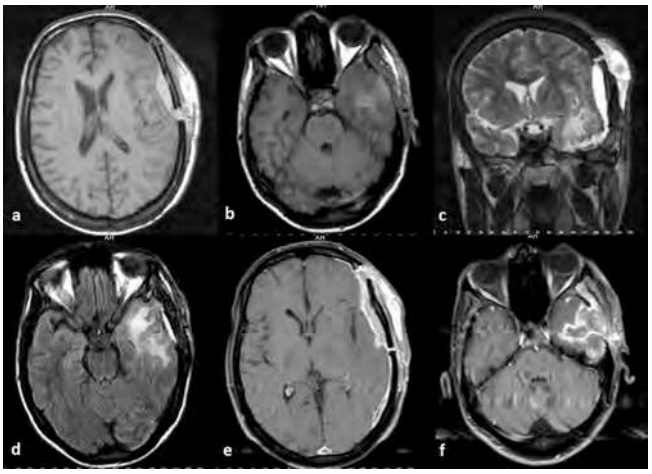

Figure 3.In the postoperative cranial MRI, axial T1 weighted (a,b), coronal T2 weighted (c), axial FLAIR (d) sequences reveal craniectomy defect in the left cerebral hemisphere, hyperintense subdural and cephal hematoma in the left frontotemporoparietal lobe which are communicated with a dural defect and hyperintensity in the left temporal lobe and compression of the left lateral ventricle are detected. In postcontrast T1 weighted axial (e) and coronal (f) sequences contrast enhancement is detected in the extraaxial hematoma, intraparenchymal and cephal hematoma in the left temporal lobe.

Discussion

Cilia play a key role in the cellular movement, diffusion and reproduction. Disturbance in the ciliary structure and function are seen in a group of disorders called ciliopathies. Primary ciliary dyskinesia, which is the prototype of the ciliopathies, is estimated to be affecting 1 in 15–30 000 live births [2]. Most patients with primary ciliary dyskinesia are presented with neonatal respiratory failure and hypoxemia. Insufficient mucociliary

clearence leads to recurrent upper and lower respiratory tract infections such as otitis media, sinonasal polyposis, sinusitis, pneumonia, bronchitis and atelectasis [3,4].

Radiological signs of primary ciliary dyskinesia are peribronchial thickening, air trapping, atelectasis and brochiectasis which are mostly seen in the middle and lower zones of the lungs. The distribution of these signs are valuable in the differential diagnosis of cystic fibrosis which has a predilection of the upper lobes [5,6]. Analysis of the cilia obtained by nasal scrape or brush is the gold standard in the diagnosis of primary ciliary dyskinesia. Many patients are diagnosed with their clinical phenotype, abnormal ciliary structure detected by electron microscopy and disturbed ciliary function observed by microscopic techniques [7].

Primary ciliary dyskinesia is usually diagnosed late due the frequent occurrence of cough, rhinitis and otitis media in children. In this case report,complications related to recurrent otitis media were emphasized in a patient with delayed diagnosis of Kartagener Syndrome. Dissemination of infection from the ear and temporal bone causes several intracranial and extracranial complications. Infection spreads mainly by three routes, which are direct extension, thrombophlebitis, and hematogenous dissemination. The intracranial complications of poorly treated and untreated otitis media are intracranial abscess, meningitis and lateral sinus thrombosis. Extracranial complications are mastoiditis, petrositis, facial nerve paralysis, labyrinthitis and persistent effusion with hearing loss, cholesteatoma and Bezold's abscess. A multidisciplinary approach with early diagnosis, antibiotic and surgical treatments have caused a significant reduction in the number of complications due to otitis media [8].

Consideration of primary ciliary dyskinesia in the differential diagnosis is crucial since early diagnosis is known to affect the short term and long term morbidity.

Competing interests

The authors declare that they have no competing interests.

References

1. Bush A, Cole P, Hariri M, Mackay I, Phillips G, O'Callaghan C, et al. Primary ciliary dyskinesia: diagnosis and standards of care. Eur Respir J 1998;12:982–8.
2. Bush A, Chodhari R, Collins N, Copeland F, Hall P, Harcourt J, et al. Primary ciliary dyskinesia: current state of the art.Arch Dis Child. 2007;92(12):1136-40.
3. Noone PG, Leigh MW, Sannuti A, Minnix SL, Carson JL, Hazucha M, et al. Primary ciliary dyskinesia: diagnostic and phenotypic features. Am J Respir Crit Care Med. 2004; 169:459–67.
4. Coren ME, Meeks M, Morrison I, Buchdahl RM, Bush A. Primary ciliary dyskinesia: age at diagnosis and symptom history. Acta Paediatr. 2002; 91:667–9.
5. Jain K, Padley SP, Goldstraw EJ, Kidd SJ, Hogg C, Biggart E, et al. Primary ciliary dyskinesia in the paediatric population: range and severity of radiological findings in a cohort of patients receiving tertiary care. Clin Radiol 2007;62:986–993.
6. Kennedy MP, Noone PG, Leigh MW, Zariwala MA, Minnix SL, Knowles MR, et al. High-resolution CT of patients with primary ciliary dyskinesia. AJR Am J Roentgenol 2007;188:1232–1238.
7. Leigh MW, Zariwala MA, Knowles MR. Primary ciliary dyskinesia: improving the diagnostic approach. Curr Opin Pediatr 2009;21:320– 325.
8. Yorgancılar E, Yildirim M, Gun R, Bakir S, Tekin R, Gocmez C, et al.Complications of chronic suppurative otitis media: a retrospective review.Eur Arch Otorhinolaryngol. 2013;270(1):69-76.

How to cite this article:
Tatar IG, Korkmaz S, Aydin H, Hekimoglu B. Cerebral Abscess and Extraaxial Empyema in a Patient with Kartagener Syndrome. J Clin Anal Med 2013;4(suppl 3): 327-9.