# Percutaneous Removal of a Fractured Central Venous Catheter Fragment in the Right Ventricle

# Sağ Ventriküldeki Kopmuş Santral Venöz Kateter Parçasının Perkütan Yolla Çıkartılması

Kateter Parçasının Çıkartılması / Removal of Catheter Fragment

Zeydin Acar[1], Murat Ziyrek[1], Fatih Kahraman[2]
[1]Karadeniz Hospital Division of Cardiology,
[2]Yıldızlı Güven Hospital Division of Anesthesia and Reanimation, Trabzon, Türkiye

**Özet**

Kalıcı santral venöz kateter sistemleri çeşitli nedenlerle sıkça kullanılan medikal cihazlardır. Santral venöz kateterin klavikula ve 1. kosta arasında sıkışması sonucunda travmatize olarak kopması "pinch-off sendromu" olarak adlandırılır. Santral venöz kateterlerin kopması ve distal embolizasyonu nadir görülen fakat yüksek morbidite ve mortalite oranları nedeniyle oldukça önemli bir komplikasyondur. Bu vaka sunumunda, 58 yaşındaki bir bayan hastada uzun süreli kemoterapi uygulaması amacıyla takılmış ve takılışının 27. ayında koparak sağ ventriküle embolize olmuş bir kalıcı santral venöz kateter parçasının perkütan yöntemle başarılı bir şekilde çıkarılması anlatılmıştır.

**Anahtar Kelimeler**

Kalıcı Santral Venöz Kateter; Pinch-Off Sendromu; Distal Embolizasyon

**Abstract**

Permenant central venous catheter systems are frequently used vascular access devices for various purposes. Fracture of a central venous catheter due to pinching effect between clavicle and the first rib is called " pinch-off syndrome". Because of high morbidity and mortality rates fracture and distal embolization of a central venous catheter is a rare but important complication. In this case report, we present successful percutaneous removal of a central venous catheter fragment from the right ventricle which was implanted 27 months ago for longterm administration of chemotherapeutic agents in a 58 years old woman.

**Keywords**

Permenant Central Venous Catheter; Pinch-Off Syndrome; Distal Embolization

DOI: 10.4328/JCAM.2353 Received: 20.02.2014 Accepted: 02.03.2014 Printed: 01.11.2013 J Clin Anal Med 2013;4(suppl 3): 338-9
Corresponding Author: Murat Ziyrek, Karadeniz Hastanesi Yavuz Selim Bulvarı No: 290 Merkez, Trabzon, Türkiye.
T.: +90 4622297070 F.: +90 4622297074 E-Mail: muziyrek@yahoo.com

## Introduction

Permenant central venous catheter systems (PVC) are frequently used vascular access devices for various purposes such as hemodialysis, urgent volume replacement, parenteral nutrition, central venous pressure monitoring, longterm administration of chemotherapeutic agents. Annual exposure to PVC in intensive care units has been estimated to total 15 million days in a year in the United States of America [1] Central venous catheters are placed through internal jugular vein or subclavian vein. Distal embolization of a fractured PVC is a rare but challenging complication. In this case report we present a central venous catheter fracture which was percutaneously removed from the right ventricle.

## Case Report

A 58 year old woman, who had breast cancer, undergone right side radical mastectomy on 10 July 2011. Afterwards a PVC was implanted through left subclavian vein to allow administration of adjuvant chemotherapy. Before the last chemotherapy session on 25 October 2013 PVC was occluded. They decided to change PVC. Although it was easily pulled back with no resistance anesthesiologist realized that the PVC was fractured and the tip of it was remained somewhere in the heart. The patient referred to our hospital. In fluoroscopic examination we detected a mobile radiopaque catheter tip in right ventricle (video 1). We decided to remove it percutaneously. Because vertical access to the right ventricle was thought to ease the procedure a 7 french percutaneous catheter introducer sheath (Medtronic, Minneapolis USA), was inserted to the right jugular vein. A 7 french right guiding catheter (Launcher JR4 guiding catheter Medtronic, Minneapolis USA) over 0.038 inch hydrophilic guidewire (Radifocus Terumo, Japan) was inserted to the right ventricle under fluoroscopic guidance. To avoid papillary muscle or chorda tendinea rupture we did not grasp the fractured catheter in right ventricle. Therefore, catheter successfully wrapped and pulled back to the right atrium with the help of 0.038 inch hydrophilic guidewire (video 2). Afterwards we successfully grasped the fragmented catheter with multisnare catheter (pfm medical mepro gmbh, Germany) (video 3) in right atrium and retrieved it out (video 4).

## Discussion

Permenant central venous catheter systems are frequently used prolonged vascular access devices. Although numerous complications associated with PVC are documented, fracture is one of the rarest complications with an estimated rate of 0.1-1 % [2]. Fractured catheters are usually presented with PVC obstruction. Catheter fracture is not the only cause of obstruction but also thrombosis, impingement against a vein wall, pinching effect between clavicle and first rib could cause obstruction [3,4]. The latter has been referred as pinch-off syndrome [3]. Chronic compression of a PVC between clavicle and first rib, that occurs when the PVC is positioned more medially, causes fracture of the PVC. Classification of radiological distortion of PVC was done by Hinke and colleagues [5]. grade 0: no narrowing in the catheter's course, grade 1: no luminal catheter narrowing, but deviation, grade 2: luminal narrowing as the catheter passes under the clavicle (true pinch-off sign), grade 3: catheter transection between the clavicle and the first rib that is accompanied by embolization of the distal catheter. Even though rarely seen, embolised catheters could cause serious complications including death in %71 of pinch-off syndrome patients [6].

The average time interval from the time of catheter insertion to pinch-off syndrome was 5 months, and the longest interval was 60 months [7]. In our case, embolization of fractured catheter was realised 27 months after insertion. Although we could not reach prior chest X-rays of the patient to see pinch-off sign, tapered tip of the catheter is easily realised in figure 1.

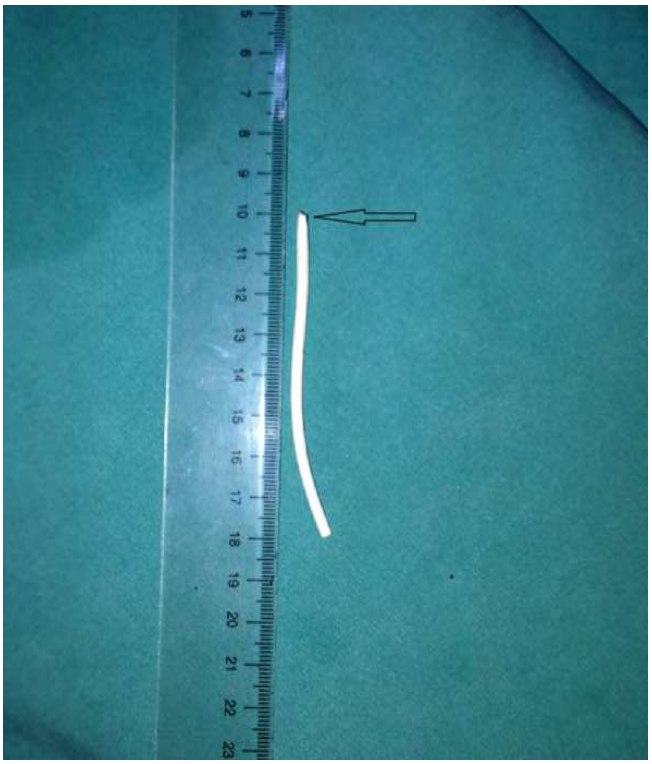

Figure 1. Nearly 9 cm long catheter fragment after successful retrieval. Arrow head indicates tapered tip of the catheter which results from the pinching effect between clavicle and first rib

## *Conclusion*

In conclusion, percutaneous removal of a fractured catheter under flouroscopic guidance is a reliable procedure usually without any complication.

## *Competing interests*

The authors declare that they have no competing interests.

**References**

1. Naomi P. O'Grady, Mary Alexander, Lillian A et al. Summary of Recommendations: Guidelines for the Prevention of Intravascular Catheter-related Infections. Clin Infect Dis. 2011: 52 (9);1087-99.
2. Yildizeli B, Lacin T, Baltacioglu F, Batirel HF, Yuksel M. Approach to fragmented central venous catheters. Vascular 2005; 13:120-3.
3. Aitken DR, Minton JP. The "pinch-off sign": a warning of impending problems with permanent subclavian catheters. Am J Surg 1984; 148:633-6.
4. Gowda MR, Gowda RM, Khan IA et al. Positional ventricular tachycardia from a fractured mediport catheter with right ventricular migration. Angiology 2004; 55:557-60.
5. Hinke DH, Zandt-Stastny DA, Goodman LR, Quebbeman EJ, Krzywda EA, Andris DA. Pinch-off syndrome: a complication of implantable subclavian venous access devices. Radiology 1990; 177:353- 6.
6. Fisher RG, Ferreyro R. Evaluation of current techniques for nonsurgical removal of intravascular iatrogenic foreign bodies. AJR Am J Roentgenol 1978;130:541-8.
7. Jin-Beom Cho, Il-Young Park, Ki-Young Sung, Jong-Min Baek, Jun-Hyun Lee, Do-Sang Lee. Pinch-off syndrome. J Korean Surg Soc 2013;85:139-44.

*How to cite this article:*
Acar Z, Ziyrek M, Kahraman F. Percutaneous Removal of a Fractured Central Venous Catheter Fragment in the Right Ventricle. J Clin Anal Med 2013;4(suppl 3): 338-9.