Multiple Lung Metastases From Parotid Adenoid Cystic Carcinoma with Respiratory Failure

Parotis Adenoid Kistik Karsinomlu Olguda Multipl Akciğer Metastazı ve Solunum Yetmezliği

Parotid Adenoid Kistik Karsinoma Akciğer Metastazı / Lung Metastasis of Parotid Adenoid Cystic Carcinoma

Hülya Günbatar[1], Selami Ekin[1], Bunyamin Sertogullarindan[1], Alpaslan Yavuz[2], Gülay Bulut[3]
[1]Department of Pulmonary and Critical Care, [2]Department of Radiology, [3]Department of Pathology,
Yuzuncu Yil University Medical Faculty, Van, Turkey

Özet

Adenoid kistik karsinom (ACC) salgı bezlerinin, en yaygın malignitelerden biridir. Bu tükürük bezi karsinomlarının yaklaşık% 15% -25% oluşturmaktadır. Tipik olarak ACC yavaş büyüyen tümörlerdir,sık hematojen yolla uzak metastaz yapar. Solunum yetmezliği ve çoklu metastaz ile başvuran bir olguyu sunduk. 52 yaşında erkek, postoperatif radikal sağ parotis bezi rezeksiyonu ardından, kraniofasiyal radyoterapi uygulandı. 5 yıl içinde yıllık kranial tomografi ile bölgesel nüks bulgusu olmadan takip edildi. Fizik muayene normaldi. Kan gazı analizi orta derecede hipoksemi ile uyumlu idi. pH; 7,49 pCO2; 31,8 Po2; 38,9 HCO3; 24,1 sat O2; 79,1. Toraks CT 5 mm 'den 4 cm arasında değişen çok sayıda her iki akciğerde diffüz dağılan lezyonlar gösterdi. Lezyona BT eşliğinde ince iğne aspirasyon biyopsisi yapıldı. Patolojik analiz adenoid kistik karsinom olarak raporlandı. Multiple akciğer metastazları solunum yetmezliğine neden olabilir ve hekimler tarafından sürekli dikkat gerektirir.

Anahtar Kelimeler

Adenoid Kistik Karsinom; Metastaz; Solunum Yetmezliği

Abstract

Adenoid cystic carcinoma (ACC) is one of the most common malig¬nancy in secretory glands. It accounts for about 15% -25% of all malignant salivary gland carcinomas. Typically, ACC is slow growing tumors and develops distant metastasis via haematogenous. We report a case who presented with respiratory failure and multiple metastases. A 52-year-old male, underwent a radical craniofacial resection for a right parotid gland, followed by postoperative radiotherapy. He was followed-up with head CT scans for 5 years with no signs of locoregional recurrence. Physical examination was normal. Blood gases analyses showed moderate hypoxemia. pH; 7,49 pCO2; 31,8 Po2; 38,9 HCO3; 24,1 sat O2; 79,1. Thorax CT showed multiple lesions ranging in size from 5 mm to 4 cm distributed diffusely in both lungs. CT-guided fine-needle aspiration of the lung lesion was performed. Pathological analysis reported adenoid cystic carcinoma. Multiple pulmonary metastases may cause respiratory failure and requires constant vigilance by medical practitioners.

Keywords

Adenoid Cystic Carcinoma; Metastasis; Respiratory Failure

DOI: 10.4328/JCAM.2332 Received: 07.02.2014 Accepted: 11.03.2014 Printed: 01.08.2013 J Clin Anal Med 2013;4(suppl 4): 372-4
Corresponding Author: Hülya Günbatar, Y.Y.U. D. Odabas Tip Merkezi, Kampüs, Van, Turkey.
T.: +90 4322150470-6135 GSM: +905065118827 E-Mail: hulyagunbatar@hotmail.com

Introduction

Adenoid cystic carcinoma (ACC) is one of the most common malig¬nancy that arises in secretory glands, particularly the major and minor salivary glands [1]. It accounts for about 15% -25% of all malignant salivary gland carcinomas [1]. Pulmonary adenoid cystic carcinoma is a rare salivary gland-type malignant neoplasm of respiratory tract that is usually located in the central airways such as trachea and main bronchus. Adenoid cystic carcinoma arising from the peripheral lung is quite rare. [2] Typically, ACC is slow growing tumors with five-year survival rate, but it spreads into adjacent tissues and develops distant metastasis via haematogenous frequently to the lungs, bone, and soft tissues. [3] Most patients with ACC (80 %–90 %) die within 10–15 years after being diagnosed due to high rates of recurrence and distant metastasis [4]. Adenoid cystic carcinoma is unique forthe reason that patients have been known to survive for 10 to 15 years despite pulmonary metastases [5]. Metastatic lesions of ACC may display radiological features indefinite from other patholo¬gies. The correct diagnosis involves correlation of the clinical history, progress, radiological features and histological findings.

We report a case of a 52-year-old man who presented with respiratory failure and multiple metastases with a diagnosed adenoid cystic carcinoma resected parotid gland five years before.

Case Report

A 52-year-old male, underwent a radical cranio-facial resection for a right parotid gland adenoid cystic carcinoma, followed by postoperative radiotherapy. He was followed-up with annual head CT scans for 5 years with no signs of loco-regional recurrence.

He presented with gradually progressive shortness of breath on exertion and cough with mucoid expectoration for the last two months. He had no any history of fever, chest pain, or haemoptysis. He had 30 packet-year tobacco use. There was no past history of, or history of contact with, tuberculosis.

Physical examination respiratory system was normal, head examination revealed no sign of local recurrence. His routine blood laboratory results also were within normal ranges. Blood gases analyses showed severe hypoxemia. pH; 7,49 pCO2; 31,8 Po2; 38,9 HCO3; 24,1 sat O2; 79,1. Multiple nodular shadows were detected on chest radiograph. CT of the thorax showed multiple lesions ranging in size from 5 mm to 4 cm distributed diffusely in both lungs (Figure 1) No mediastinal lymphadenopathy or pleural effusion was detected.

CT-guided fine-needle aspiration (FNA) of the lung lesion was performed. Pathological analysis showed multiple cystic structures with cribriform pattern on different sizes intervening hyaline stroma of the biopsy specimens reported adenoid cystic carci-noma. (Figure 2). In view of his past medical history of right parotid mass excision, the clinical picture was consistent with primary salivary gland ACC with multiple lung metastases. Patient have frequent emergency admission, he was evaluated with long term oxygen therapy, still being followed with oxygen therapy.

Discussion

ACC is a rare malignant tumour, with a unique malignant profile

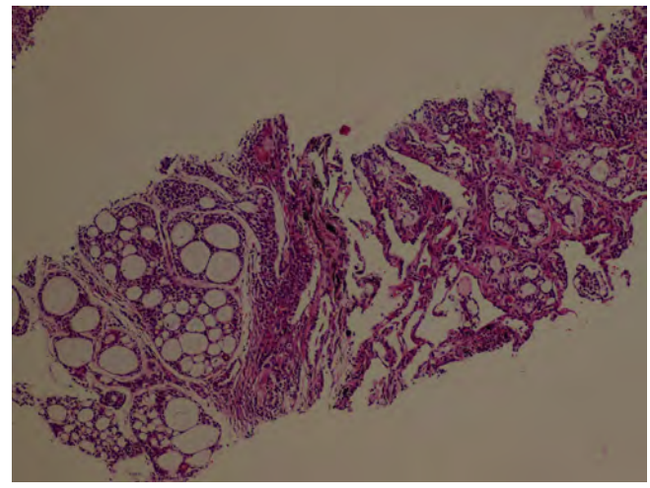

Figure 1. Multiple metastatic lesions ranging in size from 5 mm to 4 cm dstributed diffusely in both lungs.

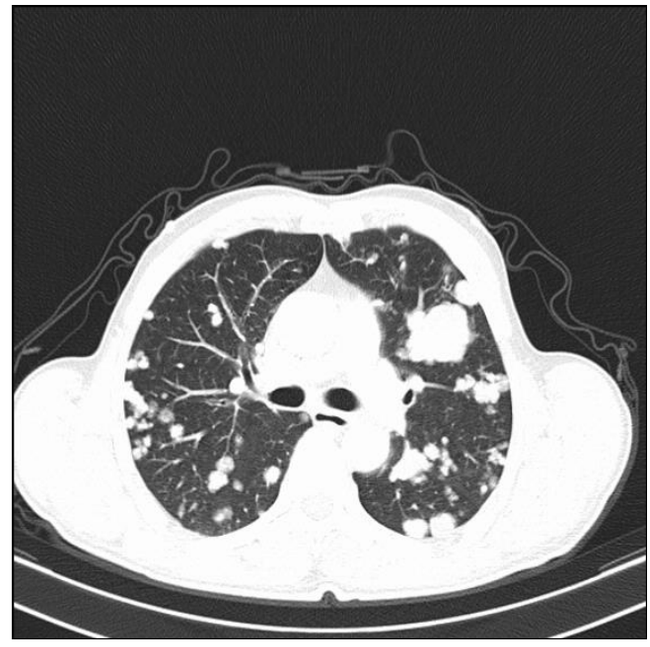

Figure 2. multiple cystic structures with cribriform pattern on different sizes intervening hyaline stroma

which accounts for approximately 10% of all salivary glands neoplasms.[6] Adenoid cystic carcinoma can arise in other sites, such as the trachea, lacrimal gland, breast, external auditory canal, cervix and vulva. Adenoid cystic carcinoma has a comparatively lazy course and rarely lymph node metastases but is well-known for its deposition for neurotropic spread, late local recurrences and distant metastatic spread. The three major histological patterns of growth pattern have been described: cribriform, tubular and solid. Combinations of the patterns are extensive. The prognosis of adenoid cystic carcinoma is greatly affected by the pattern of growth. The tubular pattern is reported to have the best prognosis while the solid is associated with a worse prognosis.[7] No solid or high-grade component was seen in the lung metastasis of this patient.

Distant metastasis was the most common type of treatment failure. In the study of Spiro 196 patients followed up for at least 10 years reported different form of treatment failure in 68%, distant metastasis in 38%, and lung involvement either alone or in addition to other sites in 34 percent. Disease-free interval varied from one month to as long as 19 years (me-

dian 36 months) [3]. Wal van der et all reported that 54.9% of their 51 patients had distant metastasis, the average time between the diagnosis of the primary lesion and the detection of metastasis was 36.8 months (median 28.5 months).[8] Sakes et al reported that disease repetition, either loco-regional or metastatic occurred up to 156 months after radiotherapy [9]. A generalization acknowledge in the treatment of cancer undertakes that a cure is present if there is liberty from disease for 5 years. The notion of cure in patients with ACC may be difficult to assess until the patient is disease free for 10 years or longer. Neverthless there are reported cases recurrences of ACC of the submandibular gland 14and 20 years after the initial therapy.[10]

Late onset of pulmonary metastases from ACC is identified, and the metastatic lesions can remain relatively stable and asymptomatic for more than 10 years. [11] But in this patient progressive deterioration on the blood gases was vieved on the fifth year .

Conclusion It should be recognized that follow-up needs to be long term to identify all late recurrence and that complete resection does not always mean cure. ACC of the parotid gland may be indicate a life-long threat to some patients also may cause respiratory failure and requires constant vigilance by medical practitioners.

Competing interests

The authors declare that they have no competing interests.

References

1. Ellington CL, Goodman M, Kono SA, Grist W, Wadsworth T, Chen AY et al. Adenoid cystic carcinoma of the head and neck: Incidence and survival trends based on 1973–2007 Surveillance, Epidemiology, and End Results data. Cancer 2012 ;118(18):4444-51

2. Yetim TD, Cokmert S, Bahadir F, Davran R, Erdem EŞ. Primary Pulmonary Adenoid Cystic Carcinoma Located at the end of the Terminal Bronchiolus: Case Report. J Clin Anal Med 2012;3(3): 361-3

3. Spiro RH, Huvos AG: Stage means more than grade in adenoid-cystic carcinoma. Am J Surg1992; 164(6):623-8.

4. Persson M, Andren Y, Mark J, Horlings HM, Persson F, Stenman G. Recurrent fusion of MYB and NFIB transcription factor genes in carcinomas of the breast and head and neck. Proc Natl Acad Sci U S A 2009;106(44): 18740–4.

5. Wal van der JE, Snow GB, Waal van der I. Intraoral adenoid cystic carcinoma: the presence of perineural spread in relation to site, size, local extension, and metastatic spread in 22 cases. Cancer 1990;66(9):2031-3

6. Barnes L, Eveson JW, Reichart P, Sidransky D. Tumors of the salivary glands: WHO and TNM classification. In: Barnes L, Eveson JW, Reichart P, Sidransky D, editors Pathology and Genetics: Head and Neck Tumours. Lyon. IARC Press; 2005:pp210-1.

7. Fordice J, Kershaw C, El-Naggar A, Goepfert H. Adenoid cystic carcinoma of the head and neck: predictors of 110 morbidity and mortality. Arch Otolaryngol Head Neck Surg 1999;125(2):149-52.

8. Wal van der JE, Becking AG, Snow GB, Waal van der I. Distant metastasis of adenoid cystic carcinoma of the salivary glands and the value of diagnostic examinations during follow-up. Head Neck 2002;24(8):779-83.

9. Sakes AJ, Slevin NJ, Birzgalis AR, Gupta NK. Submandibular gland carci-noma: an audit of control and survival following adjuvant radiotherapy. Oral Oncol 1999;35(2):187-90

10. Kömürcü S, Özet A, Safali M et al. Delayed pulmonary metastasis of adenoid cystic carcinoma originated from external earway: case report. Turkish J Cancer. 2005;35(2):93-5.

11. Bradley PJ. Adenoid cystic carcinoma of the head and neck: a re¬view. Curr Opin Otolaringol Head Neck Surg 2004;12(2):127-32.

How to cite this article:

Günbatar H, Ekin S, Sertogullarindan B, Yavuz A, Bulut G. Multiple Lung Metastases From Parotid Adenoid Cystic Carcinoma with Respiratory Failure. J Clin Anal Med 2013;4(suppl 4): 372-4.