Syringocystadenoma Papilliferum in an Unusal Location on Vulva: A Case Report

Vulvada Yerleşmiş Siringokistadenoma Papilliferum: Olgu Sunumu

Siringokistadenoma Papilliferum / Syringocystadenoma Papilliferum

Muzeyyen Duran, Emin Ustunyurt, Alper Turgut, Narter Yeşildağlar
Sevket Yılmaz Education and Research Hospital, Department of Obs/Gyn, Bursa, Turkey

Özet

Siringokistadenoma papilliferum benign bir deri tümörüdür. Tipik lezyon genellikle skalpta ve yüzde yumuşak doku kitlesi veya papül olarak görülür. Nadir olarak abdominal duvar, vulva, skrotum, göz, dış kulak yolu, meme ucu, koltuk altı ve sırtta görülebilmektedir. Bu hastalığın kaynağı halen net olarak bilinmemektedir. Burada sunduğumuz olguda hasta (30 yaşında bayan hasta) siringokistadenoma papilliferum için sık rastlanmayan bir lokalizasyon olan vulvanın sağ tarafında yerleşmiş yaklaşık 3 cm çaplı yumuşak doku kitlesi sebebi ile polikliniğimize başvurmuştur. Yumuşak doku kitlesinin eksize edilmesi ile çıkarılan materyal patolojik incelemeye gönderilmiştir. Patolojik inceleme neticesinde kitlenin siringokistadenoma papilliferum olduğu saptanmıştır. Hasta onamı alınamadığı için makroskopik resim paylaşılamamıştır. Takipte 6 ay sonra nüks izlenmiş ve eksizyon tekrar edilmiş olup, patolojik sonuç siringokistadenoma papilliferum olarak bildirilmiştir. Bu lokalizasyonda nadiren görülen siringokistadenoma papilliferum olgusunu sunmayı amaçladık. Siringokistadenoma benign bir deri tümörüdür ve hastalar genellikle başka bir semptoma yol açmayan yumuşak doku kitlesi varlığı yakınması ile başvurmaktadır. Tedavide kitlenin total eksizyonu yeterli olmakta olup, malign olgulardan ayrımının yapılması önemlidir.

Anahtar Kelimeler

Siringokistadenoma; Vulvar Kitleler

Abstract

Syringocystadenoma papilliferum (SCAP) is a benign skin tumor. It usually presents as a soft tissue mass or a papule on the scalp and face. Other uncommon reported locations of SCAP are abdominal wall, vulva, scrotum, eyelid, outer ear canal, nipple, axilla and back. The histogenesis of SCAP is still enigmatical. A 30-year-old woman was admitted to the emergency room of the Department of Obstetrics and Gynecology with a soft tissue mass on the right side of vulva, which was approximately 3 cm in diameter. The mass was removed by excision and histopathological diagnosis of the specimen was syringocystadenoma papilliferum. Consent of the patient can not be taken for macroscopic picture. A recurrence was observed after 6 months following excision of the mass; re-excision of the mass was performed and histopathological evaluation identified the same diagnosis. Here we present a case of syringocystadenoma papilliferum located in a relatively unusual site, in which total excision and re-excision of the mass is sufficient for cure. It is essential to make an appropriate differential diagnosis to exclude malign cases in patients who present with an asymptomatic solitary lesion.

Keywords

Syringocystadenoma; Vulvar Masses

DOI: 10.4328/JCAM.2361 Received: 21.02.2014 Accepted: 23.03.2014 Printed: 01.08.2013 J Clin Anal Med 2013;4(suppl 4): 392-3
Corresponding Author: Muzeyyen Duran, 100. Yıl Mah. Saygınkent Sitesi, A blok D:16 Özlüce Nilüfer, Bursa, Turkey.
GSM: +905438090882 E-Mail: drmuzbur@yahoo.com.tr

Introduction

Syringocystadenoma papilliferum (SCAP) is characterized by papules or plaques, most commonly located on the scalp and face during childhood. Other uncommon reported locations of SCAP are abdominal wall, vulva, scrotum, eyelid, outer ear canal, nipple, axilla and back. The histogenesis of SCAP is still unknown. SCAP occurs either de novo or within a nevus sebaceous. It usually presents as an asymptomatic soft tissue mass. We present an uncommon case of SCAP in a 30-year-old woman, appearing on the right vulva, recurring in the same location after 6 months following excision of the mass in the same location.

Case Report

A 30-year-old woman presented to the outpatient ward of the Department of Obstetrics and Gynecology with an asymptomatic vulvar mass, which occurred two months before. On vaginal ultrasound examination a mass (2x3 cm) on right vulva was diagnosed. Total excision of the mass was performed and the histopathological evaluation of the specimen revealed hyperkeratosis, acanthosis and papillomatosis. The papillae were extended to both layers of epithelium. The deeper layer was consisted of cuboidal cells, whereas the superficial layer was consisted of columnar cells, some of which showing decapitation secretion. The fibrous tissue essence was invaded by plasma cells (Figure 1). The histopathological findings identified the diagnosis of SCAP. In the follow-up period, a recurrence was observed after 6 months in same location. Re-excision of the mass was performed and histopathological evaluation identified the same diagnosis.

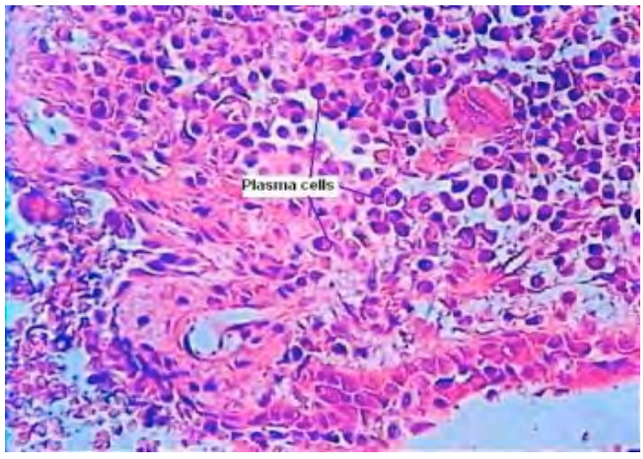

Figure 1. The fibrous stromal core demonstrated plasma cell infiltration.(HαE, X40)

Discussion

SCAP was first defined by Stokes in 1917 [1]. It commonly presents as a papule or a plaque on the scalp and most of the cases are reported in the head and face [1,2]. Other uncommon reported locations of SCAP are abdominal wall, vulva, scrotum, eyelid, outer ear canal, nipple, axilla and back. In the relatively rare cases of SCAP diagnosed in histopathological evaluation, SCAP originates from the pluripotent cells [3,4,5]. It may spring up within a nevus sebaceous. SCAP present in different clinical forms: as a solitary nodule or a plaque, or in a linear pattern. Linear pattern is very rare [6,7]. SCAP was reported in other locations but it was rarely reported in the vulva [5, 8]. It commonly presents as an asymptomatic solitary nodule.

It was reported that 10% of SCAP cases grew into basal cell carcinoma [9]. This relation is similar to allelic deletions of human homologue of the Drosophila patched gene (PTCH) and P16 tumor suppressor gene has been showed in some cases of SCAP [9,10,11]. It is related with malignant tumors such as basal cell carcinoma, ductal carcinoma, verrucous carcinoma, sebaceous carcinoma [2,6,12]. SCAP has also been reported in other locations but it has seldom been reported in the vulva [5, 6] and it commonly presents as an asymptomatic solitary nodule; it should be kept in mind that it is essential to make an appropriate differential diagnosis to exclude malign cases in patients who present with an asymptomatic solitary lesion.

Competing interests

The authors declare that they have no competing interests.

References

1. Stokes JH. A clinico- pathologic study of an unusual cutaneous neoplasm combining nevus syringadenomatosus papilliferus and a granuloma. J Cutan Dis 1917;35:411-9.
2. Ghosh SK, Bandyopadhyay D, Chatterjee G, Bar C. Syringocystadenoma papilliferum: An unusual presentation. Pediatr Dermatol 2009;26(6):758-9.
3. Malhotra P, Singh A, Ramesh V. Syringocystadenoma papilliferum on the thigh: An unusual location. Indian J Dermatol Venereol Leprol 2009;75:170-2.
4. Dong Xu, Tienan Bi, Huanrong Lan, Wenjie Yu. Syringocystadenoma papilliferum in the right lower abdomen: a case report and review of literature. Onco Targets and Therapy 2013;6:233-6.
5. Nabeel Al-Brahim, Dean Daya, Salem Alowami. A 64-year-old woman with vulvar papule. Arch Pathol Lab Med 2005;129:126-7.
6. Yap FB, Lee BR, Baba R. Syringocystadenoma papilliferum in an unusual location beyond the head and neck region: A case report and review of literature. J Online Dermatol 2010;16: 4.
7. Pahwa P, Kaushal S, Gupta S, Khaitan BK, Sharma VK, Sethuraman G. Linear syringocystadenoma papilliferum: An unusual location. Pediatr Dermatol 2011;28:61-2.
8. Stewart CJ. Syringocystadenoma papilliferum -like lesion of the vulva. Pathology 2008; 40(6):638-9
9. Helwig EB, Hackney VC. Syringoadenoma papilliferum. Arch Dermatol 1955; 71:361
10. Böni R, Xin H, Hohl D, Panizzon R, Burg G. Syringocystadenoma papilliferum: a study of potential tumor suppresor gene. Am J Dermapathol 2011;23:87-9.
11. Calonje E. Tumors of the skin appendages. Rook's textbook of Dermatology. UK: Wiley Blackwell; 2010. p.19-20.
12. Abdulla AN, Covert AA, Grantmyre JE. Scrotal syringocystadenoma papilliferum: case report. Can J Urol 2009; 16(3): 4684-6.

How to cite this article:
Duran M, Ustunyurt E, Turgut A, Yeşildağlar N. Syringocystadenoma Papilliferum in an Unusal Location on Vulva: A Case Report. J Clin Anal Med 2013;4(suppl 4): 392-3.