A Rare Non-Small Cell Lung Tumor; Lymphoepithelioma Like Carcinoma

Akciğerin Nadir Görülen Küçük Hücreli Dışı Tümörü; Lenfoepitelyoma Benzeri Karsinom

Nadir Görülen Bir Tümör: Lenfoepitelyoma Benzeri Karsinom / A Rare Tumor: Lymphoepithelioma Like Carcinoma

Mustafa Kuzucuoğlu[1], Yekta Altemur Karamustafaoğlu[2], Fazlı Yanık[2], Yener Yörük[2]
[1]Nevşehir Devlet Hastanesi, Göğüs Cerrahisi Kliniği, Nevşehir,
[2]Trakya Üniversitesi Tıp Fakültesi, Göğüs Cerrahisi Ana Bilim Dalı, Edirne, Türkiye

Özet

Lenfoepitelyoma benzeri karsinom küçük hücreli dışı akciğer kanserlerinin alt grubunda yer alan ve morfolojik olarak nazofarenks yerleşimli lenfoepitelyomaya benzerlik gösteren, akciğerin nadir görülen bir tümörüdür. İlk olarak 1987 yılında Begin ve arkadaşları tarafından tanımlanmıştır. Biz de kliniğimizde cerrahi uygulanan iki olguyu literatür eşliğinde irdeledik.

Anahtar Kelimeler

Akciğer Kanseri; Lenfoepitelyoma; Epstein Barr Virus

Abstract

Lymphoepithelioma-like carcinoma, which belongs to a subgroup of non-small cell lung cancer and morphologically resembles to lymphoepithelioma located in the nasopharynx, is a rare tumor of the lung. It was first described by Begin and others in 1987. We evaluated two patients who underwent surgery in our clinic after reviewing medical literature.

Keywords

Lung Cancer; Lymphoepithelioma; Epstein Barr Virus

DOI: 10.4328/JCAM.2368 Received: 26.02.2014 Accepted: 19.03.2014 Printed: 01.08.2013 J Clin Anal Med 2013;4(suppl 4): 386-8
Corresponding Author: Mustafa Kuzucuoğlu, Nevşehir Devlet Hastanesi Göğüs Cerrahisi Kliniği, Nevşehir, Türkiye.
GSM: +905334935864 E-Mail: mustafakuzucuoglu@hotmail.com

Introduction

Lymphoepithelioma-like carcinoma (LLC), which belongs to a subgroup of non-small cell lung cancer and morphologically resembles to lymphoepithelioma located in the nasopharynx, is a rare tumor of the lung. It was first described by Begin et al in 1987 [1-3]. It is mostly found among young, non-smoking male patients in Southeast Asia countries and frequently in Hong Kong, Taiwan and Guangdong regions of China [4]. Although Epstein Barr Virus (EBV) infection is thought to play a major role in its etiology, according to medical literature, its relationship with EBV has not been demonstrated in studies conducted among few non-Asian patients [5]. We evaluated two patients who underwent surgery in our clinic after reviewing medical literature.

Case Report I

Sixty four years old male patient with a history of cigarette use applied to our hospital on detection of opacity at the right upper zone in the routine control chest X-ray. Thoracic computerized tomography (CT) revealed a soft tissue mass about 2 cm extending through the right upper bronchus and affected several lymph nodes in the mediastinal region with the largest being 11 mm (Figure-1A). Endobronchial lesion was not seen during fiberoptic bronchoscopic examination. With preliminary diagnosis of pulmonary malign neoplasm, a computerized tomography integrated positron emission tomography (PET/CT) was conducted for the aim of staging; results revealed a 4x1.5 cm soft tissue mass at the apex, SUVmax was 16.2, 1cm lymph node at right hilum SUVmax was 3.2 and a SUVmax of 0.9 in the sub-centimeter lymph nodes at inferior lobe of superior segment of the right lung (Figure-1B). Right upper lobectomy and mediastinal lymph node dissection were performed.

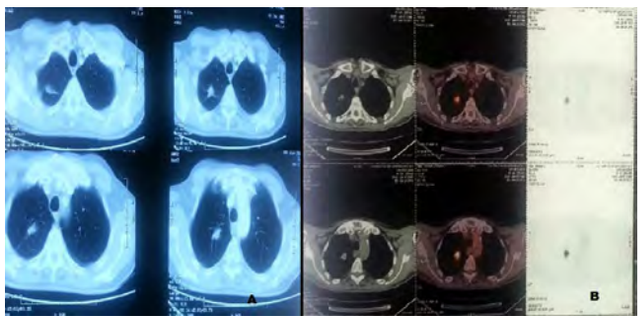

Figure 1. 2-cm mass in the right upper lobe on thorax CT (A), SUVmax 16.2 mass in the right upper lobe on preoperative PET-CT (B).

In the histopathologic evaluation; the macroscopic gross tumor was 2.5x2x2 cm in size, closely related to bronchus, hard, bleeding and had irregular contours. Immunohistochemical studies revealed CD8 positivity in the keratinic, epithelial as well as lymphoid areas of the tumor. The areas were negative for CD1a, S100, CK7 and EBV where as CD68, CD3 and CD20 stained heterogeneously. The lymph nodes numbered 7, 8 and 10 were evaluated as reactive hyperplasia. At the end of the histopathologic assessments, the result was reported as LLC; stage T1bN0M0. There was no need for adjuvant therapy. No recurrence or metastasis was detected in the PET/CT performed at the end of the first year (Figure-2).

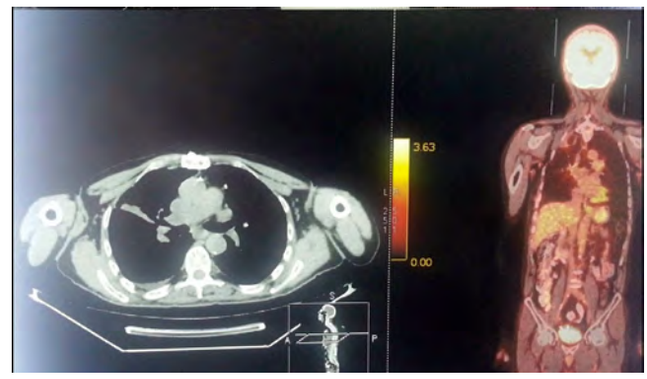

Figure 2. PET-CT appearance of the postoperative first year control

Case Report II

Sixty years old male patient, a smoker without any complain administered to our clinic on detection of a suspected mass in his chest X-ray at right upper zone of the lung and a 3 cm mass on thoracic CT examination. The PET/CT was reported a malign lesion, 48x57mm oat right lung upper lobe anterior segment with SUVmax:18.5 (Figure-3). Although there was not

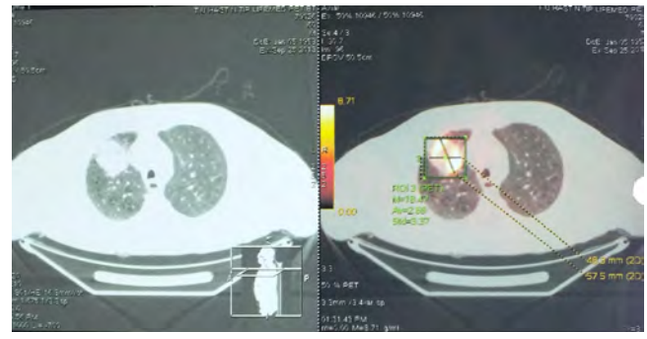

Figure 3. Malign lesion in right upper lobe anterior segment on PET-CT

any endobronchial lesion detected as a result of bronchoscopic investigation, the results of transthoracic fine needle aspiration biopsy were reported as reactive inflammation. The patient whose radiological examination suggested malignity, but no definitive diagnosis had the lymph nodes numbered 2, 4 and 7 excised mediastinoscopically. All lymph nodes were reported as reactive hyperplasia. Right upper lobectomy and mediastinal lymph node dissection was performed.

Result of the histopathologic evaluation; reported a macroscopic tumor 3 cm sized with negative surgical margins. All of the lymph nodes excised from station number 9, 10, and 11 were evaluated as reactive hyperplasia. The result of pathologic evaluations was reported as LLC; stage T1bN0M0. The patient who at this point was on his postoperative 2nd month, was discussed at the oncological meeting and subsequent radiological follow up was planned.

Discussion

Besides the fact that pulmonary LLC is a rare non-small cell pulmonary carcinoma, interestingly it is more common in Asian patient population and particularly at the south of China. In a study with 32 patients conducted by Han et al [6], LLC has been demonstrated to be related with EBV cover RNA-1 antigen positivity and EBV infection playing a role in the pathogenesis of the tumor.

Lymphoepithelioma like carcinoma (LLC) is histologically highly similar with the lymphoepithelioma of nasopharynx. Up to now, similar histological characteristics were detected in the stomach, skin, thymus, secretory glands, uterus, cervix, urinary system and lungs. Since the relationship of nasopharyngeal lymphoepitheliomas with EBV is demonstrated, serological, immunohistochemical or gene studies should be performed in LLC of other sites [7]. Bildirici et al. [3] reported that histologically the pulmonary LLC cannot be distinguished from undifferentiated nasopharynx carcinoma and for this reason nasopharynx carcinoma and lymphoma should be ruled out by tissue biopsies. Detection of strong positivity for cytokeratin and epithelial membrane antigen in neoplastic cells supports diagnosis. Castro et al. [8] have also studied tissue leukocyte common antigen staining for the differential diagnosis with lymphoma.

Findings of previous research studies and case reports demonstrate that the tumors are neoplasm with specific clinical and pathological characteristics. Although it is seen in adult patients without differences between genders, in only one case pulmonary LLC of childhood age has also been reported in the medical literature. In a study by Curcio et al.[9], an 8 year old Chinese girl was diagnosed with pulmonary LLC and right upper lobectomy was performed.

Pulmonary LLC is usually not associated with smoking and in contrast to other tumors, cigarette does not play role in its etiology [3,10]. Both of our cases were adult males and were heavy smokers.

In general cases of LLC are diagnosed via surgical operations. Results of minimally invasive procedures may provide information on whether the diagnosis is uncertain or it is a non-small cell pulmonary malignancy of different histopathologic character. Differential diagnosis from the lymphoepithelioma of nasopharynx is difficult. In early stages, curative surgical treatment of lymphoepitheliomas has a better prognosis than other non-small cell pulmonary cancers. Early stage survival results are gratifying in patients who had surgery [3,5,6]. In our cases the diagnosis was only possible by explorative surgery and in both cases lobectomy was performed .

In the study conducted by JC.Ho et al. [11]; the cases with LLC and non-small cell pulmonary carcinomas were compared for prognosis and after 5 years of follow up survival was significantly higher in Stages II,III,IV in cases of LLC, whereas there was no difference between the two groups in Stage I case.

Although lymph node metastasis was discovered in about 25 % of the previous studies, hematogenous metastasis is rarely seen. Hematogenous metastases are only seen in the skeletal system [3].

Adjuvant chemotherapy was beneficial in advanced stage or nonresectable LCC tumors. In chemotherapy, chemotherapy regimens such as Cisplatin + 5-fluorouracil, Gemcitabine + Cisplatin, 5-fluorouracil + Cisplatin + Leucovorin were used in both adjuvant and neo-adjuvant treatments [11,12].

Consequently, pulmonary LLC is a malignancy rarely seen outside Far Eastern Asian countries, not related with EBV and needed to be treated as non-small cell pulmonary cancers. However, in order to determine the causes and responses to treatment of the LLC more case reports and genomic studies are needed.

Competing interests

The authors declare that they have no competing interests.

References

1. Begin LR, Eskandari J, Joncas J, Panasci L. Epstein-Barr virus related lymphoepithelioma-like carcinoma of lung. J Surg Oncol 1987;36(4):280-3.
2. Chan JK, Hui PK, Tsang WY, Law CK, Ma CC, Yip TT, et al. Primary lymphoepithelioma- like carcinoma of the lung: a clinicopathologic study of 11 cases. Cancer 1995;76(3):413-22.
3. Bildirici K, Ak G, Peker B, Metintaş M, Alataş F, Erginel S, ve ark. Primary lymphoepithelioma-like carcinoma of the lung. Tüberküloz ve Toraks Dergisi 2005;53(1):69-73.
4. Huang CJ, Chan KY, Lee MY, Hsu LH, Chu NM, Feng AC, et al. Computed tomography characteristics of primary pulmonary lymphoepithelioma-like carcinoma. Br J Radiol 2007;80(958):803-6.
5. Gözübüyük A, Kavakli K, Çaylak H, Genç O. Akciğer Yerleşimli Lenfoepitelyoma Benzeri Karsinomlu Bir Olgu. Tur Toraks Der 2009;10:201-3.
6. Han AJ, Xiong M, Gu YY, Lin SX, Xiong M. Lymphoepithelioma-like carcinoma of the lung with a beter prognosis. A clinicopathologic study of 32 cases. Am J Clin Pathol 2001;115(6):841-50.
7. Higashiyama M, Doi O, Kodama K, Yokouchi H, Horiuchi K, Mishima K. Lymphoepitelioma-like carcinoma of the lung: analysis of two cases for Epstein-Barr virus infection. Hum Pathol 1995;26(11):1278-82.
8. Castro CY, Osrtrowski ML, Barrios R, Green LK, Popper HH, Cagle PT, et al. Relationship between Epstein-Barr virus and lymphoepithelioma-like carcinoma of the lung: a clinicopathologic study of 6 cases and review of the literature. Hum Pathol 2001;32(8):863-72.
9. Curcio LD, Cohen JS, Grannis FW, Paz IB, Chilcote R, Weiss LM. Primary lymphoepithelioma-like carcinoma of the lung in a child. Report of an Epstein-Barr virus-related neoplasm. Chest 997;111(1):250-1.
10. Hammar SP. Common neoplasms. In: Dail DH, Hammar SP (Eds). Pulmonary Pathology. 2nd ed. New York: Springer-Verlag; 1994.p.1123-7.
11. JC Ho, Wong MP, Lam WK. Lymphoepithelioma-like carcinoma of the lung. Respirology 2006;11:539–45.
12. Chang Y-L, Wu CT, Shih JY, Lee YC. New aspects in clinicopathologic and oncogene studies of 23 pulmonary lymphoepithelioma like carcinomas. Am Surg Pathol 2002;26:715.

How to cite this article:

Kuzucuoğlu M, Karamustafaoğlu YA, Yanık F, Yörük Y. A Rare Non-Small Cell Lung Tumor; Lymphoepithelioma Like Carcinoma. J Clin Anal Med 2013;4(suppl 4): 386-8.