Asymptomatic Left Atrial Myxoma in Elderly Patient: A Case Report

Yaşlı Hastada Asemptomatik Sol Atrial Miksoma: Olgu Sunumu

Asemptomatik Sol Atrial Miksoma / Asymptomatic Left Atrial Myxoma

Seyhan Yilmaz[1], Serdar Gunaydin[2]
[1]Hitit University, Corum Education and Research Hospital, Department of Cardiovascular Surgery, Corum,
[2]Medline Hospital, Department of Cardiovascular Surgery, Eskisehir, Turkey

Özet

Kardiak tümörlerin yaklaşık %75'i benign olup yaklaşık %50'sini miksomalar oluşturmaktadır. Miksomalar kadınlarda daha sıktır ve genellikle hayatın üçüncü ve altıncı dekatları arasında gözlenirler. En sık görülen semptomu obstruksiyona bağlı solunum zorluğudur. Kardiyak miksomaların cerrahisinde ana prensip kardiyopulmoner bypass eşliğinde tümörün minimal manipülasyonla ve parçalanma olmadan tam eksizyonudur. Bu olgu sunumu, son yedi yıl içerisinde farklı zamanlarda genel anestezi eşliğinde iki kez cerrahi geçirmiş ve kardiak miksoma tanısı konulamamış, yetmiş bir yaşında, asemptomatik kardiak miksomalı yaşlı bir hastayı bildirmektedir.

Anahtar Kelimeler

Kalp Tümörleri; Miksoma; Atrial Septal Defekt; Siyanoz; Anjiografi

Abstract

Approximately 75% of cardiac tumors are benign and approximately 50% are constituted of myxomas. Myxomas are more common among women, and generally appear between the third and sixth decade of life. The most common symptom of myxomas is respiratory distress associated with obstruction. The main goal in the surgery of cardiac myxomas is the full excision of the tumor with minimal manipulation and disruption/fragmentation together with the aid of a cardiopulmonary bypass. This case report is reported a seventy years old patient with asymptomatıc cardiac myxoma whom undergoing surgery with general anesthesia twice at different times and undiagnosed cardiac myxoma in past seven years.

Keywords

Cardiac Tumor; Myxoma; Atrial Septal Defect; Cyanosis; Angiography

DOI: 10.4328/JCAM.2410 Received: 17.03.2014 Accepted: 31.03.2014 Printed: 01.08.2013 J Clin Anal Med 2013;4(suppl 4): 401-3
Corresponding Author: Seyhan Yılmaz, Çamlık Sok. No:2, Çorum, Türkiye.
GSM: +905336838186 E-Mail: drlabarna@gmail.com

Introduction

The incidence of primary cardiac tumors, which are uncommon in all age groups, is 1.7-10 in 100,000 within the population. Approximately 75% of these tumors are benign, and approximately 50% are constituted of myxomas.[1] Myxomas are more common among women, and generally appear between the third and sixth decade of life.[2] Myxomas are pathologies that may have fatal outcomes due to their associated complications, and most patients with this condition experience embolization, cardiac symptoms associated with obstruction, and structural symptoms.[1,3] The most common symptom is respiratory distress associated with obstruction. The clinical features of myxomas varies according to tumor localization, size and motility, and tumors are generally observed on the left side of the heart (75% in the left atrium).[3,4] Transthoracic and transesophageal echocardiography tests are the most accurate, reliable and commonly used diagnostic tools, and provide important information regarding the imaging and characteristics of the tumor. The first surgical excision of a myxoma was reported by Bahnson in 1952. The main goal in the surgery of cardiac myxomas is the full excision of the tumor with minimal manipulation and disruption/fragmentation together with the aid of a cardiopulmonary bypass.

Case Report

71-year-old female patient admitted to the hospital with complaints one times fainting temporarily and dizziness at the last two weeks of sometimes . Connective tissue disease, cerebrovascular disease, malignancy, rheumatic fever, radiation exposure, renal failure, metabolic disorders, peripheral embolism and chest trauma haven't be at resume questioning of patient and there isn't palpitation, chest pain, weight loss and respiratory distress story. In the last seven years,patient has a history of two operations because of the bile duct stone and ileus that made under general anesthesia and examinations and preparation tests conducted before these operations had not received the diagnosis of cardiac myxoma. At physical examination, blood pressure was 110/70 mmHg, pulse was 78/sec, fever was 36.6 degree and respiratory rate 20/min respectively. On inspection there were no examination findings other than hemorrhagic rash outside of the chest wall and abdominal operation scars. Evident on palpation of peripheral pulses. There was no sound except for the pathological murmur apical 1-2/6 presistolik at auscultation. Chest X-ray showed an increase in vascularity in the lungs. Electrocardiography were in sinus rhythm. There was not the result of abnormal hematology and biochemical tests (WBC: 5300, CRP: 0.6 mg / dl and Sedimentation: 22/ hour). Echocardiography were used in preoperative diagnosis. İn the left atrium a mass was found with transesophageal echocardiography after transthoracic echocardiography which depending on the size 31x22mm,connected interatrial septum with a handle about 1 cm length and showing calcifications (Figure 1). Ejection fraction of patient was 67% with echocardiography. Due to the advanced aged patient coronary angiography was built and there was no significant coronary artery disease. The patient was operated under general anesthesia with a midline sternotomy, cardiopulmonary baypass has been entered following assending aorta and bicaval cannulation. Moderate



Figure 1. Transesophageal echocardiography view of the left atrial myxoma.

hypothermia and cardiac arrest was achieved with blood cardioplegia. The left and right atria were opened and followed yellowish gelatinous mass in the left atrium, stem and base of origin with the interatrial septum was excised. Interatrial septal defect was closed using a PTFE patch. After excision of the tumor mass the cardiac chambers were checked and due to absence of any mass, cardiac chambers were irrigated with cold saline over and over again. The mitral valve was found to be normal. The patient was not made an additional attempt. The histopathological examination of the excised mass which sized 50X40X30mm was built and is compatible with myxoma (Figure 2, 3). Postoperative period was uneventful and the patient was discharged on the fifth postoperative day. Patients were followed up without recurrence for a year without any problems.



Figure 2. Surgical specimen of the resected mass; size 5×4 × 3 cm.

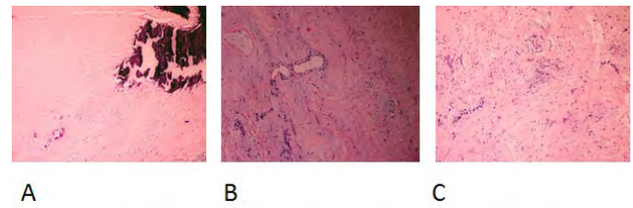

Figure 3. Histolopathological specimen in the hematoxylin–eosin stain (magnification ×100) showing; myxoma cells, inflammation and calcification.

Discussion

Cardiac myxomas are more common among women and between the ages of 30-60, and are frequently localized to the left atrium .[1,3] Our patient was a 70 years-old women with a left atrial myxoma rooted in the fossa ovalis of the interatrial septum. Histologically, myxomas are formed of polygonal myxoma cells and small capillary canals within a mucopolysaccharide-rich matrix.[3] However, the cellular structure of myxomas is still a matter of debate.[3] Histopathological tests of the tumor mass excised from our case demonstrated that the tumor had myxoma characteristics. Cardiac myxomas are the primary cardiac tumors with the most variable clinical symptoms; their major symptoms include complications associated with embolization, and hemodynamic complications secondary to the obstruction of blood flow into the chambers of the heart. Non-cardiac symptoms that are not associated with the tumor localization include constitutional symptoms such fever, weight loss, myalgia, erythematous eruptions and lethargy.[1,3] No embolic lesions were identified in our patient, and complaints of tachycardia and dyspnea were also absent. However, the patient had complaints of short-duration syncope attacks, myalgia, and erythematous eruptions. Auscultation of left atrial myxomas generally reveals auscultatory findings of mitral stenosis, which includes hardened primary heart sounds and diastolic murmur in the apical region.[3] Auscultatory findings indicative of mitral stenosis were also identified in our patient. The electrocardiography findings of myxomas are nonspecific, while telecardiography can identify and show generalized cardiomegaly, enlargement in the relevant heart chambers, and pulmonary congestion findings associated with pulmonary venous hypertension in the lungs.[3] Our patient had a sinus rhythm, as well as increased vascularity in the lungs. Nowadays, echocardiography represent the most commonly used and accurate diagnostic tool for the diagnosis of cardiac myxomas. Transesophageal echocardiography provides very useful information, and is superior to transthoracic echocardiography in fully demonstrating the relationship between the tumor and the cavity wall, and also for the planning of surgery. Our patient underwent two surgeries under general anesthesia on two different occasions within the past seven years; however, her cardiac myxoma was not identified during the preoperative physical examinations and preparatory tests that were performed for these surgeries. Definite diagnosis in our patient was established with the aid of transesophageal echocardiography performed after transthoracic echocardiography. In addition, as our patient was of advanced age, coronary angiography was also performed to evaluate the coronary arteries. Myxomas are generally benign and rarely metastasize. No metastasis was identified in any of the tests performed on our case.[5] Myxomas that are not treated with surgery generally have poor mid and long-term prognosis. They must hence be removed after diagnosis, even if they are asymptomatic. Surgical excision is the most effective treatment method, and provides fairly good outcomes.[5,6] In our case with left atrial myxoma, the tumor was excised as a whole and without fragmenting, along with the endocardial portion to which the tumor was attached, by using biatrial incision. The resulting atrial septal defect was closed with a patch. No mortality developed in our case. Our case was followed for a period 12 months with periodic echocardiographies, and no recurrence of myxoma was identified during this period.

Conclusion

Cardiac myxomas are generally benign tumors, with surgical excision being the most effective method for their treatment. The majority of patients who are operated following diagnosis with echocardiography continue their lives asymptomatically. Against the possibility of recurrence, patients should undergo periodic echocardiography controls at certain time intervals.

Competing interests

The authors declare that they have no competing interests.

References

1. Keçeligil HT, Demir Z, Kolbakır F, Demirağ MK, Akar H. [Cardiac myxoma and surgical treatment] Kardiyak miksoma ve cerrahi tedavisi. Türk Göğüs Kalp Damar Cer Derg 1999;7:210-6.
2. A Özen, Ü Kervan, U Ünal, AK İrdem, E Yücel. Case Report of a Left Atrial Myxoma Associated with Carney's Syndrome. Journal of Clinical and Analytical Medicine 2013. DOI: 10.4328/JCAM.1693
3. Şirin H. [Cardiac Tumors] Kalp Tümörleri. In: Duran E.Kalp ve Damar Cerrahisi, Cilt 2, 2004; Çapa Tıp Kitabevi ve Yayıncılık, Edirne, 1751-1764
4. Kaplan M , Demirtaş MM, Çimen S, Gerçekoğlu H, Yapıcı F, Özler A. [Cardiac myxoma:] Kardiyak Miksoma: 45 Olguluk Deneyim. Turkish J Thorac Cardiovasc Surg 2002;10:11-14
5. Kirklin JW, Barratt-Boyes. Cardiac tumor. In: Kirklin JW, Barratt-Boyes BG. Cardiac Surgery, Vol 2, 1993; 2nd edition, New York, Churchill Livingstone, 1635-1654.
6. Nurözler F, Tandoğan A, Birol Y. Huge Left Atrial Myxoma With Minimal Symptoms: Case Report. Turkish J Thorac Cardiovasc Surg 2003;11: 52-53.

How to cite this article:
Yilmaz S, Gunaydin S. Asymptomatic Left Atrial Myxoma in Elderly Patient: A Case Report. J Clin Anal Med 2013;4(suppl 4): 401-3.