# Optical Coherence Tomography Findings in Unilateral Peripapillary Myelinated Retinal Nerve Fibers

# Tek Taraflı Peripapiller Miyelinli Retina Sinir Liflerinde Optik Koherens Tomografi Bulguları

Myelinli Sinir Liflerinde OCT Bulguları / OCT Findings in Myelinated Retinal Nerve Fibers

Alime Gunes[1], Seden Demirci[2], Mustafa Gunes[3]
[1]Department of Ophthalmology, [2]Department of Neurology, [3]Department of Urology,
Süleyman Demirel University Faculty of Medicine, Isparta, Turkey

**Özet**

On dokuz yaşında bir erkek hasta, erken çocukluğundan beri olan sağ gözünde görme azlığı ile başvurdu. Düzeltilmiş en iyi görme keskinliği, sağ gözde 10 cm' den parmak sayma ve sol gözünde 1.0 idi. Relatif afferent pupil defekti yoktu; refraksiyon değerleri, sağ gözde -6.50 -1.25 x 110 ve sol gözde -0.25 değerindeydi. Biyomikroskobik mueyene ve göz içi basıncı her iki gözde normaldi. Fundus muayenesinde, sağ gözde geniş, çukurlaşmış disk, üst vasküler arkuat boyunca uzanan aşırı myelinli peripapiller retina sinir lifleri mevcuttu. Optik koherens tomografi, sağ gözde üst kadranda incelme ile birlikte normal ortalama peripapiller retina sinir lifi tabakası kalınlığı (RSLT) ve anormal foveal kontur göstermekteydi. Myelinli retinal sinir lifleri, ortalama peripapiller RSLT kalınlığında değişikliklere neden olmasa da, anormal foveal morfoloji ve anizometrik miyopi ile ciddi görme kaybına neden olabilir.

**Anahtar Kelimeler**

Myelinli Retina Sinir Lifleri; Optik Kohorens Tomografi; Retina Sinir Lifi Tabakası Kalınlığı

**Abstract**

A 19-year-old male presented with low vision in the right eye since early childhood. Best corrected visual acuity was counting fingers at 10 cm and 1.0 in the right and left eyes. There was no relative afferent pupillary defect; refraction was -6.50 -1.25 x 110 and -0.25 in the right and left eyes. Biomicroscopic examination and intraocular pressures were normal in both eyes. On fundus examination, there was large, cupped disk, extensive peripapillary myelinated retinal nerve fibers extending along superior vascular arcade in the right eye. Optical coherence tomography showed normal average peripapillary retinal nerve fiber layer (RNFL) thickness with thinning in superior quadrant and abnormal foveal contour in the right eye. Although MRNF not cause changes in average RNFL thickness, may cause to serious vision loss by abnormal foveal morphology and anisometropic myopia.

**Keywords**

Myelinated Retinal Nerve Fibers; Optic Coherence Tomography; Retinal Nerve Fiber Layer Thickness

DOI: 10.4328/JCAM.2444 Received: 28.03.2014 Accepted: 11.04.2014 Printed: 01.08.2013 J Clin Anal Med 2013;4(suppl 4): 423-5
Corresponding Author: Alime Gunes, Department of Ophthalmology, Süleyman Demirel University Faculty of Medicine, 32260, Isparta, Turkey.
GSM: +905054828345 E-Mail: dralimesefer@hotmail.com

## Introduction

Myelination of the optic nerve begins at the 32nd pregnancy week from the lateral geniculate nucleus and finishes at term. It arrives the lamina cribrosa a short time after birth [1]. Myelinated retinal nerve fibers (MRNF) are not normally found in the human retina, but histopathologic studies have demonstrated that pieces of MRNF contain oligodendrocytes [2]. Williams suggested that a defect in the lamina cribrosa would cause entry of oligodendrocytes into the retina [2]. It was supported by extensive retinal myelination in animals with little or no lamina cribrosa [2].

Anisometropic myopia, strabismus, abnormal foveal morphology, amblyopia and reduced vision may be associated with MRNF [4,5].

In this report, we present optical coherence tomography (OCT) findings in a patient with unilateral peripapillary myelinated retinal nerve fibers.

## Case Report

A 19-year-old male presented with low vision in the right eye since early childhood. Best corrected visual acuity was counting fingers at 10 cm and 1.0 in the right and left eyes. Pupils did not show relative afferent pupillary defect; refraction was -6.50 -1.25 x 110 and -0.25 in the right and left eyes. Biomicroscopic examination and intraocular pressures were normal in both eyes. On fundus examination, there was large, cupped disk, extensive peripapillary MRNF extending along superior vascular arcade in the right eye (Figure 1). Optical coherence tomography (OCT) (Spectral OCT SLO, OPKO/OTI Instrumentation, Miami, FL, USA) showed normal average retinal nerve fiber layer (RNFL) thickness with thinning in superior quadrant (Figure 2) and abnormal foveal contour in the right eye (Figure 3). In addition, our patient has had epilepsy and chronic renal failure secondary to vesicoureteral reflux.

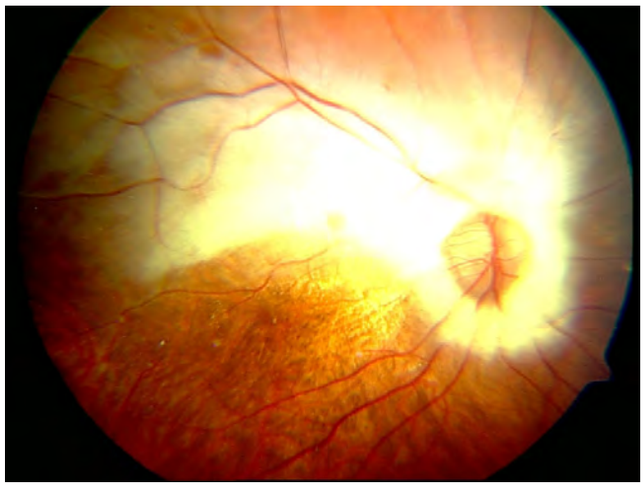

Figure 1. Fundus photography of the patient's right eye showed large, cupped disk, extensive peripapillary myelinated retinal nerve fibers extending along superior vascular arcade.

## Discussion

Peripapillary MRNF can be congenital or acquired. Congenital retinal myelination is a developmental anomaly and the incidence in the population is 0.3-0.6%. Coexistence of MRNF and ipsilateral high myopia, amblyopia, strabismus, optic disk hypoplasia and vision loss has been reported in the literature [4,5]. Gharai et al. evaluated MRNF with OCT and reported that peripapillary MRNF involving the macula can cause foveal ectopia, deprivation amblyopia and vision loss [6]. They suggested that foveal position can be detected only by OCT.

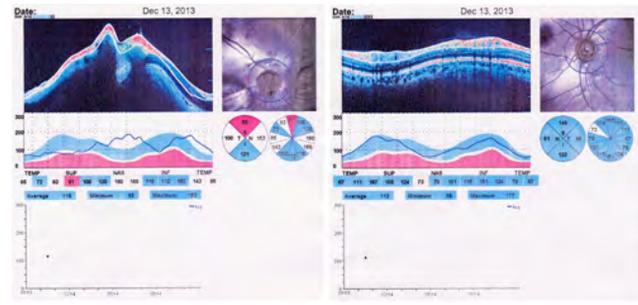


Figure 2. Optical coherence tomography showed normal average retinal nerve fiber layer thickness with thinning in superior quadrant in right eye and normal average retinal nerve fiber layer thickness in left eye.

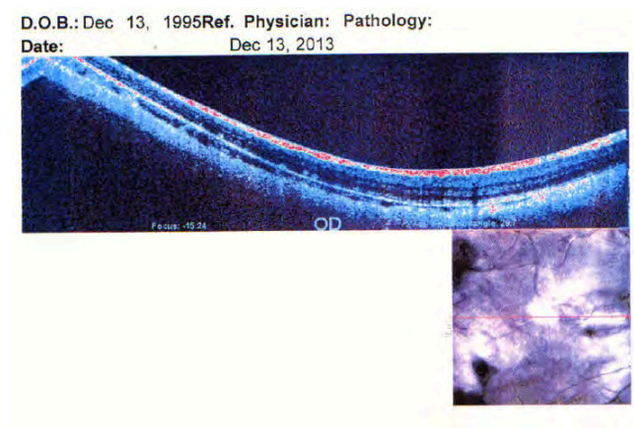


Figure 3. Optical coherence tomography showed abnormal foveal contour in right eye.

In our case, OCT showed normal average RNFL thickness with thinning in superior quadrant and abnormal foveal contour in the right eye. Peripapillary MRNF extending along superior vascular arcade can explain the decreased thickness of superior RNFL.

In addition, our patient has had epilepsy and chronic renal failure secondary to vesicoureteral reflux, but this association has never been reported in the literature.

In this case, low vision in the right eye with MRNF may have been due to foveal abnormality, anisometropic amblyopia, or optic disk hypoplasia.

To the best of our knowledge, this is the first report of the OCT findings including peripapillary RNFL in a patient with MRNF. Although MRNF not cause changes in average RNFL thickness, may cause to serious vision loss by abnormal foveal morphology and anisometropic myopia.

### *Competing interests*

The authors declare that they have no competing interests.

**References**

1. Magoon EH, Robb RM. Development of myelin in human optic nerve and tract. A light and electron microscopic study. Arch Ophthalmol 1981;99(4):655-9.
2. Straatsma BR, Foos RY, Heckenlively JR, Taylor GN. Myelinated retinal nerve fibers. Am J Ophthalmol 1981;91(1):25-38.
3. Williams TD. Medullated retinal nerve fibers: Speculation son their cause and presentation of cases. Am J Optom Physiol Opt 1986;63(2):142-51.
4. Lee MS, Gonzalez C. Unilateral peripapillary myelinizated retinal nerve fi-

bers associated with strabismus, amblyopia, and myopia. Am J Ophthalmol 1998;125(4):554-6.
5. Yalcın E, Balcı O, Akıngol Z. Association of extensive myelinated nerve fibers and high degree myopia: Case report. Indian J Ophthalmol 2013;61(10):606–7.
6. Gharai S, Prakash G, Ashok Kumar D, Jacob S, Agarwal A, Arora V. Spectral domain optical coherence tomographic characteristics of unilateral peripapillary myelinated retinal nerve fibers involving the macula. J AAPOS 2010;14(5):432-4.

*How to cite this article:*
Gunes A, Demirci S, Gunes M. Optical Coherence Tomography Findings in Unilateral Peripapillary Myelinated Retinal Nerve Fibers. J Clin Anal Med 2013;4(suppl 4): 423-5.