Radiologic Findings of Distal Ureter with Partially Double Lumen: First Case in the Literature

Parsiyel Çift Lümenli Distal Üreterin Radyolojik Bulguları: Literatürdeki İlk Olgu

Parsiyel Çift Lümenli Distal Üreter / Distal Ureter with Partially Double Lumen

Elif Karadeli[1], Şerife Nur Ulusan[1], Özgür Yaycıoğlu[2]
[1]Radyoloji Bölümü, [2]Üroloji Bölümü, Başkent Üniversitesi, Tıp Fakültesi, Ankara, Türkiye

Özet

Üriner sistemin en sık konjenital anomalisi üreter duplikasyonudur. Üreter duplikasyonu tamamıyla ayrı üreterden bifid pelvise kadar değişim göstermektedir. Rapor edilen insidans otopsi serilerinde %0.8, pyelografi incelemelerinde %40'a kadar değişmektedir. Tek taraflı form bilateral olana göre 6 kez daha sık gelişir, sol ve sağ taraf eşit olarak tutulur. Bilinen taş hastalığı olmayan 37 yaşında erkek olgu 3 saattir süren sağ yerleşimli kolik ağrı ile üroloji bölümümüze başvurdu. Ultrasonografi ve Bilgisayarlı Tomografi (BT) yapıldı. Biz parsiyel çift lümenli distal üreterin radyolojik bulgularını gösterdik. Bizim bilgilerimize göre, bu literatürde daha önce rapor edilmemiştir.

Anahtar Kelimeler

Üreter; Çift Lümen; Radyoloji; Bulgular

Abstract

Ureter duplication is the most common congenital anomaly of the urinary system. Ureteral duplication varies from a bifid pelvis to completely separate ureters. The reported incidence varies from 0.8% in an autopsy series, to 40% in a pyelography review, and displays a wide spectrum of imaging findings . The unilateral form occurs about 6 times more commonly than the bilateral form, with the left and right sides being almost equally involved. A 37 year old male with no previous history for stone disease presented to the urology department with right sided colicky pain for three hours. Ultrasonography and Computurized Tomography (CT) were performed. We demonstrated radiologic findings of distal ureter with partially double lumen. According to our knowledge, it has not been reported in the literature previously.

Keywords

Ureter; Double Lumen; Radiology; Findings

DOI: 10.4328/JCAM.2485 Received: 14.04.2014 Accepted: 05.05.2014 Printed: 01.08.2013 J Clin Anal Med 2013;4(suppl 4): 458-60
Corresponding Author: Elif Karadeli, Başkent Üniversitesi, Tıp Fakültesi, Radyoloji Bölümü, Fevzi Çakmak Cad. 10. Sok. No:45, 06490. Bahçelievler, Ankara, Türkiye.
T.: +90 3122126868 F.: +90 3122237333 E-Mail: elifkaradeli@gmail.com

Introduction

Ureter duplication is the most common congenital anomaly of the urinary system. Ureteral duplication varies from a bifid pelvis to completely separate ureters. The reported incidence varies from 0.8% in an autopsy series, to 40% in a pyelography review, and displays a wide spectrum of imaging findings [1-2]. The unilateral form occurs about 6 times more commonly than the bilateral form, with the left and right sides being almost equally involved [3].

We demonstrated radiologic findings of distal ureter with partially double lumen. According to our knowledge, it has not been reported in the literature previously.

Case Report

A 37 year old male with no previous history for stone disease presented to our hospital with right sided colicky pain for three hours. Ultrasonography revealed dilatation of the collecting system of the right kidney. The patient was admitted to the urology department since his pain did not respond to initial analgesic treatment. He was treated with parenteral narcotic analgesics and hydration. Non-contrast CT revealed a 4 mm stone in the right lower ureter. The patient was discharged with oral medication after his pain subsided for a trial of spontaneous passage. Two days later, he came back to the urology department with colicky pain. At this time, non-contrast CT showed that the stone was still in the right lower ureter. Thus, a decision was made for ureteroscopic removal. At right sided ureteroscopy the stone was located at the lower ureter and was removed with basket catheter. After the stone was removed it was seen that the ureteral lumen divided into two separate channels proximal to the location of the stone. Retrograde ureteropyelography was performed which showed that approximately 3 centimeters of lower ureter had double lumina which joined both proximally and distally. The remaining parts of the ureter and pyelocalyceal system were normal. No further interventions were performed. The patient was completely symptom-free after the operation and was discharged on postoperative day one. Intravenous pyelography was performed one month after surgery which showed similar findings with retrograde ureteropyelography (Figure 1A and1B)

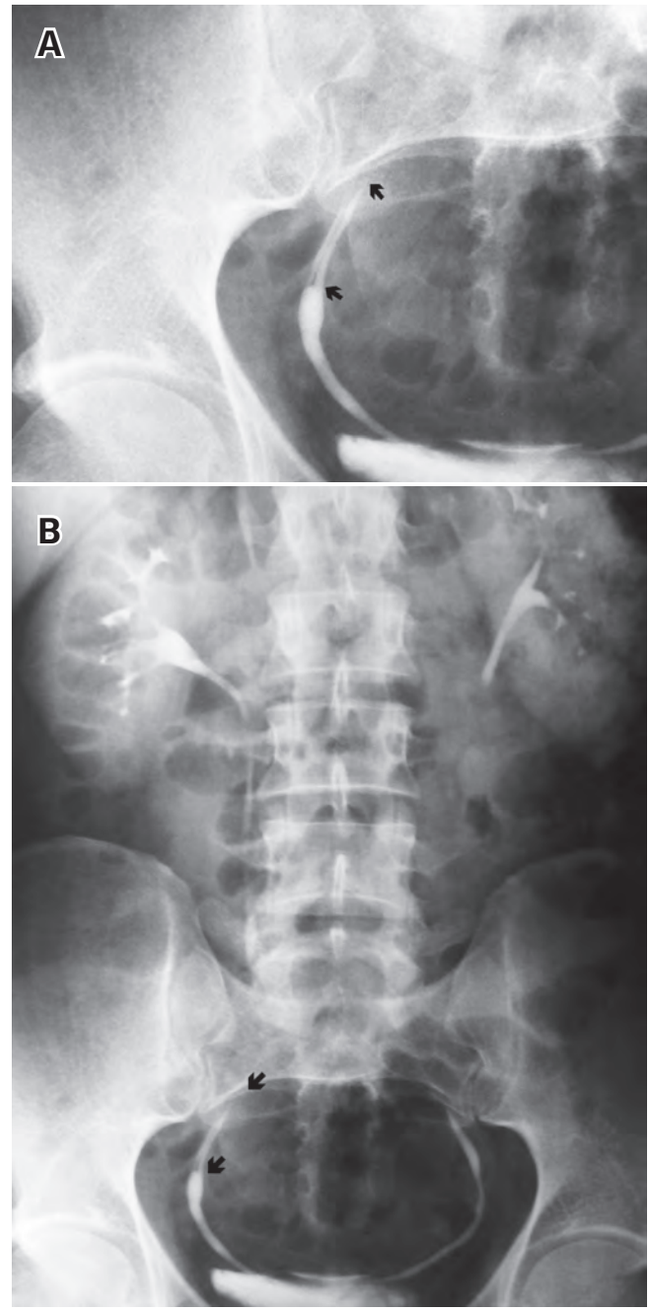

Figure1. (A,B) intravenous urography shows right ureter with partially double lumen (arrows) and shows normal left ureter and bladder.

Discussion

The unilateral ureter duplications are the most common anomaly of the urinary system. The unilateral form occurs about 6 times more commonly than the bilateral form, this anomaly are seen equally in the left and right sides [3].

It presents complete or incomplete ureteric duplication. Incomplete duplication is three times more common than complete duplication, which are 500 people [4].

The ureteric orifices are characteristically inverted, in relation to the renal unit they drain. The ureter of the lower renal unit drains to the normal ureteric insertion, while the ureter of the upper renal unit drains ectopically [5].

Our patient had unilateral ureter duplication. Interestingly, single ureter lumen was separated into pieces lumen in the distal ureter and then it was fused at end of the split, which located distal of the 3-4 cm. There was one ureter opening to bladder.

Unfortunately, there is small amount of information about ureter development and these knowledges base on speculative theories related the molecular mechanism of smooth muscle cell and urethelial differentiation. Morphologically, the ureter begins as a simple cuboidal epithelial tube surrounded by loose mesenchymal cells, which acquires a complete lumen at 28 days of gestation in humans. It was suggested that the developing ureter undergoes a transient luminal obstruction between 37 and 40 days and subsequently recanalizes[6]. It appears that this recanalization process begins in the midureter and extends in a bidirectional manner both cranially and caudally. In addition, another source of physiologic ureteral obstruction may exist as Chowilla's membrane, a two-cell-thick layer over the ureteric orifice that is seen between 37 and 39 days of gestation [7]

In our patient, the partial duplication of the ureteral lumen might have been caused by intraluminal attachments' formed during the recanalization process.

These patients may be accompanied by other ureteral anoma-

lies such as ectopic ureter and have an increased risk of developing urinary tract infection, pain, hydronephrosis and stone formation. Incomplete duplication is most often associated with ureteroureteral reflux or ureteropelvic junction obstruction of the lower pole of the kidney. Complete duplication is most often associated with vesicoureteral reflux, ectopic ureterocele, or ectopic ureteral insertion, all of which are more common in girls than in boys. Vesicoureteral reflux affects the lower pole and can be outgrown, as in no duplicated systems [8]

Similarly, our patient had pain and stone formation. In conclusion, we want to report radiologic findings of distal ureter with partially double lumen. To the best our knowledge, there are no published in the literature previously.

Competing interests

The authors declare that they have no competing interests.

References

1. Nation EF. Duplication of the kidney and ureter: a statistically study of 230 new cases. J Urol 1944; 51: 456-65 .
2. Nordmark B. Double formations of the pelves of the kidneys and the ureters: embryology, ossurrence and clinical significance. Acta Radiol 1948; 30(4):267-77.
3. Stuart BB. Anomalies of the upper urinary tract. In: Walsh PC, Retik AB, editors. Campbell's Urology. 8nd ed. Philadelphia:W.B.Saunders; 2002. p 1885-924.
4. Cronan JJ, Amis ES, Zeman RK, Dorfman GS. Obstruction of the upper pole moiety in renal duplication in adults: CT evaluation. Radiology 1986: 161(1);17-21.
5. Mackie GG, Stephens FD. Duplex kidneys: a correlation of renal dysplasia with position of the ureteral orifice. J Urol 1975;114(2):274-80.
6. Alcaraz A, Vinaixa, F, Tejedo-Mateu A , Forest MM, Gotzens V, Mestres CA, et al. Obstruction and recanalization of the ureter during embryonic development. J Urol 1991; 145(2): 410–6.
7. Baker LA, Gomez RA. Embryonic development of the ureter. Semin Nephrol 1998; 18(6): 569-84.
8. Fernbach SK, Zawin JK, Lebowitz RL. Complete duplication of the ureteropelvic junction obstruction of the lower pole of the kidney: imaging findings. AJR 1995; 164(3):701-4.

How to cite this article:
Karadeli E, Ulusan ŞN, Yaycıoğlu Ö. Radiologic Findings of Distal Ureter with Partially Double Lumen: First Case in the Literature. J Clin Anal Med 2013;4(suppl 4): 458-60.