Optic Neuropathy Secondary to an Onodi Cell Mucocele in a Child

Bir Çocukta Onodi Hücreli Mukosele İkincil Oluşan Optik Nöropati

İkincil Optik Noropati / Secondary Optic Neuropathy

Emine Cinici[1], Hasan Kahveci[2], Arzu Tatar[3], Ibrahim Kocer[4]
[1]Erzurum District Training and Research Hospital, Department of Ophthalmology,
[2]Erzurum District Training and Research Hospital, Department of Pediatrics,
[3]Erzurum District Training and Research Hospital, Department of Ear, Nose And Thoroat,
[4]Ataturk University Medical Faculty, Department of Ophthalmology, Erzurum, Turkey

Özet

Onodi hücre optik sinir ile sıkı bir şekilde bağlantılıdır. Onodi hücre patolojileri, kompresyon sonucu optik nöropati ve görmede bozulmaya neden olabilir . Bize on gün içinde baş ağrısı ve görmede ilerleyici kayıp şikayetiyle başvuran 13 yaşındaki erkek hastada Onodi hücreli mukosel'in neden olduğu retrobulber optik nöropati tablosunu belirledik. Multi-slice paranazal bilgisayarlı tomografi ve kranial manyetik rezonans görüntüleme, sol sfenoid sinüsden kaynaklanan bir retansiyon kisti (Onodi hücreli mukosel) ve inflamasyonla uyumlu olarak raporlandı. Hasta herhangi bir komplikasyon olmadan başarılı bir şekilde transnasal sfenoetmoidektomi ile tedavi edildi. Histopatolojik değerlendirmede poliplerde Onodi Hücreli Mukosel tespit edildi. Ameliyat sonrasında hastanın görme keskinliği tam iyileşti. Akut veya kronik görme kaybı şikayetiyle göz , kulak burun boğaz ve çocuk doktorlarına başvuran çocuk hastalarda tespit edilen retrobulber optik nöropati etyolojisinde onodi hücreli mukoselide unutmamak gerekir.

Anahtar Kelimeler

Mukosel; Optik Nöropati; Çocuk

Abstract

Onodi cell is intimately related to the optic nerve. Onodi cell pathologies may result compressive optic neuropathy and poor visual outcome. We have identified for the first time in the 13-year-old male patient retrobulbar optic neuropathy caused by mucocele in an Onodi cell. This case presented with headaches and progressive loss of vision in his both eye within ten days. Multi-slice paranasal computed tomography and cranial magnetic resonance imaging showed a retention cyst (Onodi cell mucocele) that arouse from left component of the sphenoid sinus, and Onodi cell inflammation. The patient was treated successfully by elective transnasal sphenoethmoidectomy without any complications. Histopathological evaluation revealed polyps in Onodi cell. Postoperatively, the patient's visual acuity full were recovered. Ophthalmologists, otorhinolaryngologists, and pediatricians should consider Onodi cell mucocele in the etiology of retrobulbar optic neuropathy when a pediatric patient presents with acute or chronic loss of vision.

Keywords

Mucocele; Optic Neuropathy; Child

DOI: 10.4328/JCAM.2609 Received: 05.06.2014 Accepted: 05.07.2014 Printed: 01.10.2013 J Clin Anal Med 2013;4(suppl 5): 485-7
Corresponding Author: Emine Cinici, Department of Ophthalmology, Erzurum District Training and Research Hospital, Erzurum, Turkey.
T.: +90 4422325275 F.: +90 4422325090 E-Mail: dreminecinici@hotmail.com

Introduction

The Onodi cell was first decribed by Adolf Onodi in 1904. The Onodi cell is recognized as an anatomical variant, where the most posteriorly-positioned ethmoid cells enlarges into the body of the sphenoid bone that surround the optic nerve, which pneumatizes laterally and superiorly to the sphenoid sinus. Its clinical significance relates to the relative position of the Onodi cell to the optic nerve1,2. In the literature, the incidence of Onodi cells varies from 8–to13% in the radiological findings but the rate is % 60 in cadaveric studies1.It has been reported to be more prevalent in Asia compared to the Western countries (60% vs. 39%)3. In the recent study, Onodi cells were observed more frequently in the Far East than in Western countries and 98.1% of them were identified on preoperative paranasal sinus computed tomography4. Many cases of large spheno-ethmoidal mucocele manifesting as visual disturbances have been reported. However, isolated mucocele of an Onodi cell causing optic neuropathy is rare. Isolated mucocele an Onodi cell is an extremely unusual cause of compressive optic neuropathy2,5. Compressive retrobulbar optic neuropathy secondary to mucocele in Onodi cells and optic neuropathy secondary to sinusitis in Onodi cells have been reported in adult patients 1–8. Here, we present the first report of a pediatric patient with bilateral gradual loss of vision due to an isolated Onodi cell mucocele, with full recovery after elective surgery.

Case Report

A 13-year-old male patient presented to our clinic with loss of vision in both eyes that started 15 days previously and gradually worsened, accompanied by headache. He had no history of nasal or paranasal sinus inflammation or surgical manipulation. An ophthalmological examination indicated a best corrected visual acuity of 5/10 in the right eye, and vision in the left eye was limited to counting fingers at 1 m. Intraocular pressure and eye movements were normal in both eyes. However, the patient showed a relative pupillary defect and color vision deficiency. A fundus examination revealed that both optic discs were edematous. Neurological examination results were otherwise normal. Biochemical, hematologic, and immunological markers were normal. Skull radyography showed no abnormalities. Under a diagnosis of suspected bilateral optic neuritis, the patient was given oral amoxicillin-clavulanic acid and intravenous methylprednisolone. On day 3 of treatment, the best corrected visual acuity had improved to 10/10 in the right eye, although there was no improvement in the left eye.

Differential diagnoses were retrobulbar optic neuritis, infective optic neuropathy, compressive optic neuropathy and posterior ischaemic optic neuropathy. Multislice computed tomography (CT) of the paranasal sinuses revealed Onodi cell inflammation in the left component of the sphenoid sinus, in close proximity to the course of the optic nerve (Fig. 1). Cranial magnetic resonance imaging (MRI) showed a retention cyst measuring 17 × 13.9 mm (Onodi cell mucocele), originating from the left component of the sphenoid sinus, and lying next to the left optic canal. The cyst was isointense on fluid attenuated inversion recovery (FLAIR) images, hypointense on T1-weighted images, and hyperintense on T2-weighted images (Fig. 2). A radiological diagnosis of compressive retrobulbar optic neuropathy secondary to an Onodi cell mucocele was made.

The patient underwent transnasal sphenoethmoidectomy. The diagnosis was confirmed intraoperatively. The retention cyst in the left sphenoid sinus was drained. Histopathological examination revealed a cystic mass rich in ciliated epithelium, fibrosis, hyalinization, and interstitial tissue. A postoperative ophthalmic examination at 1 week showed a best corrected visual acuity of 10/10, normal pupillary light reflex, and normal color vision. There were no problems during the 8-year follow-up, and the patient has remained stable.

Discussion

Onodi cell is intimately related to the optic nevre. Thus, Onodi cell pathologies may result in ophthalmological complication as a rhinogenic optic neuropathies and poor visual outcome8. Retrobulber optic neuropathy caused by mucocele may be explained by several mechanisms. Optic neuropathy is caused by mechanical compression of the optic nerve, circulatory disturbance of the vasa nervorum due to the mechanic compression, or optic neuritis due to inflammation1-3,5.

Radiologic imaging is essential to preoperative diagnosis; specifically, CT scans are required to demonstrate anatomical variations. If the thickness of the slices is greater than the width of the Onodi cell, variations cannot be differentiated1,6. MRI scans are also required to determine the protein content of the Onodi cell material and to differentiate the nature of the lesion, including mucocele, pyocele, and tumor2. We established the diagnosis, as described in the literature, by CT of the paranasal sinuses and cranial MRI. Multislice paranasal CT and cranial MRI showed a retention cyst (Onodi cell mucocele) measuring 17 × 13.9 mm and arising from the left component of the sphenoid sinus, and Onodi cell inflammation (Fig 1,2). All reported cases of optic neuropathy secondary to an isolated Onodi cell mucocele have been in adult patients 1-3,5,7–8. in a 41-year-old male patient; by Kitagawa et al.7 in a 73-year-old male patient; by Lim et al.3 in a 60-year-old male patient; by Wu et al.1 in a 28-year-old male patient; by Fukuda et al.2 in a 45-year-old male patient; and by Taflan et al.6 in a 61-year-old

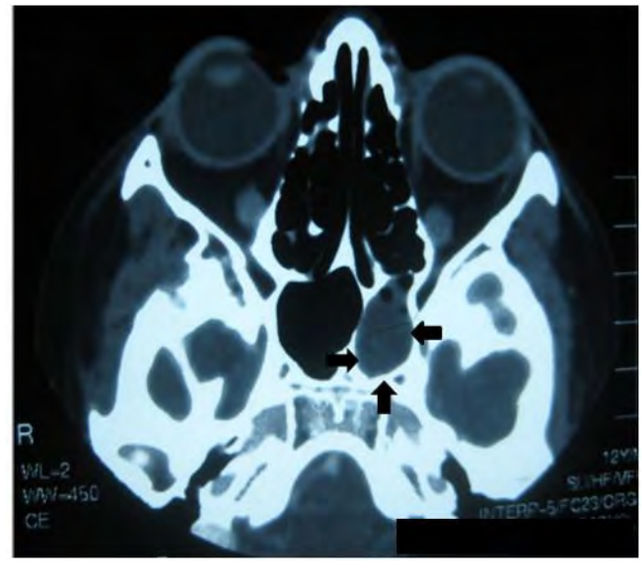

Figure 1. Multislice computed tomography images of the paranasal sinuses reveal Onodi cell inflammation in the sphenoid sinus, in close proximity to the course of the optic nerve (arrows).

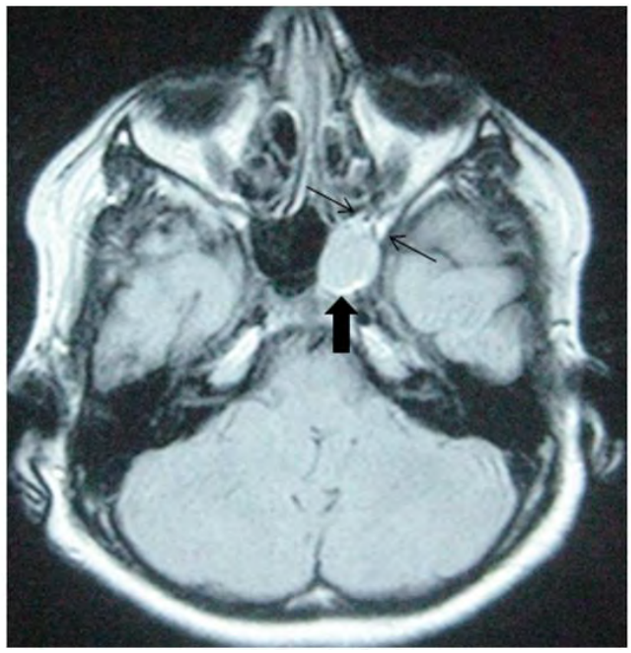

Figure 2. Cranial magnetic resonance images show a retention cyst (Onodi cell mucocele) lying next to the left optic canal, with an isointense appearance on axial cross-section FLAIR (arrows).

female patient. Fukuda et al.8 reported a bilateral case in a 79-year old female patient. The youngest patient reported to date, by Wu and colleagues1, was 28 at the time of diagnosis. To our knowledge, our patient represents the first reported pediatric case. As such, this case demonstrates that Onodi cell mucocele should be included in the etiology of compressive optic neuropathy in pediatric patients.

The best surgical approach is the subject of conjecture among surgeons. The transcranial approach may minimize the risk of optic nerve injury when a small Onodi cell mucocele is close to the optic nerve. However, brain parenchyma injury, leakage of cerebrospinal fluid, and possible contamination of the cerebrospinal fluid by mucocele contents are frequent and serious complications of this approach2. The endoscopic, transnasal approach lacks these complications and is a less invasive technique. The patient was treated successfully by elective transnasal sphenoethmoidectomy without any complications. Vision has been fully restored. In our patient we saw that an immediate decompression of the optic nerve led to considerable improvement of visual acuity and field, even in a case of drastic functional impairment.

In conclusion, ophthalmologists, otorhinolaryngologists, and neuroradiologist should be familiar with the rare occurrence of the Onodi cell mucoceles causing optic neuropathy. As delays in diagnosis and treatment increase the risk for vision loss, it is crucial to approach such cases in a multidisciplinary manner, maintaining close contact among medical staff. Ophthalmologists, otorhinolaryngologists, and pediatricians should consider Onodi cell mucocele in the etiology of retrobulbar optic neuropathy in pediatric patients presenting with acute or chronic loss of vision.

Competing interests

The authors declare that they have no competing interests.

References

1. Wu W, Sun MT, Cannon PS, Jianbo S, Selva D. Recovery of visual function in a patient with an Onodi cell mucocele compressive optic neuropathy who had a 5-week interval between onset and surgical intervention: case report. J Ophthalmol 2010; DOI: 10.1155/2010/483056.
2. Fukuda H, Fukumitsu R, Andoh M, Suzuki T, Yamana N, Kataoka H, et al. Small Onodi cell mucocele causing chronic optic neuropathy: case report. Neurol Med Chir (Tokyo) 2010;50(10):953–5.
3. Lim SA, Sitoh YY, Lim TC, Lee JC. Right rhinogenic optic neuritis secondary to mucocoele of the Onodi cell: clinics in diagnostic imaging. Singapore Med J 2008;49(1):84–7.
4. Shin JH, Kim SW, Hong YK, Jeun SS, Kang SG, Kim SW, et al. The Onodi cell: an obstacle to sellar lesions with a transsphenoidal approach. Otolaryngol Head Neck Surg 2011;145(6):1040–2.
5. Taflan T, Güngör I, Cengel Kurnaz S, Güngör L. Optıc neuropathy secondary to inflammation of sphenoidal sinuses and Onodi cell polyps: a case report. Ocul Immunol Inflamm 2013;21(3):1–4.
6. Toh ST, Lee JC. Onodi cell mucocele: rare cause of optic compressive neuropathy. Arch Otolaryngol Head Neck Surg 2007;133(11):1153–6.
7. Kitagawa K, Hayasaka S, Shimizu K, Nagaki Y. Optic neuropathy produced by a compressed mucocele in an Onodi cell. Am J Ophthalmol 2003;135(2):253–4.
8. Fukuda Y, Chikamatsu K, Ninomiya H, Yasuoka Y, Miyashita M, Furuya N. Mucocele in an Onodi cell with simultaneous bilateral visual disturbance. Auris Nasus Larynx 2006;33(2):199–202.

How to cite this article:
Cinici E, Kahveci H, Tatar A, Kocer İ. Optic Neuropathy Secondary to an Onodi Cell Mucocele in a Child. J Clin Anal Med 2013;4(suppl 5): 485-7.