Olgu Sunumu
JCAM
Case Report

Primary Neuroendocrine Tumor of the Prostate with Bone Metastasis

Kemik Metastazı Yapmış Prostatın Primer Nöroendokrin Tümörü

Prostatın Primer Nöroendokrin Tümörü / Primary Neuroendocrine Tumor of The Prostate

Abdullah Sivrikaya[1], Ersagun Karagüzel[1], İlke Onur Kazaz[1], Doğan Sabri Tok[1], Sevdegül Mungan[2]
[1]Üroloji Ana Bilim Dalı, Karadeniz Teknik Üniversitesi Tıp Fakültesi, Trabzon, Türkiye.
[2]Patoloji Ana Bilim Dalı, Karadeniz Teknik Üniversitesi Tıp Fakültesi, Trabzon, Türkiye.

Özet

Prostatın primer nöroendokrin tümörleri çok nadir ve biyolojik davranışları henüz çok iyi açıklanamamış tümörlerdir. Bu makalede primer prostat nöroendokrin tümörü ve kemik metastazı olan bir olgu sunulmaktadır. Altı aydır sık idrara çıkma, işemede zorluk ve mesanesini tam boşaltamama şikayetleri mevcut olan 50 yaşında erkek hastaya, transüretral prostat rezeksiyonu yapıldı. Patoloji sonucu az diferansiye nöroendokrin karsinom olarak rapor edildi. Hastanın boyun ağrısı nedeniyle yapılan servikal manyetik rezonans tetkikinde sağ paravertebral yumuşak dokuda bir kitle ve C6 vertebrada patolojik kompresyon kırığı tespit edildi. Hastaya kitlenin eksizyonunu takiben, C6 korpektomi ve homojen kemik grefti konulması operasyonu yapıldı. Paravertebral kitlenin patolojik incelenmesi sonucu az diferansiye nöroendokrin tümor metastazı olduğu tespit edildi. Lezyonun prostatın primer nöroendokrin tümörünün kemik metastazı olduğu konfirme edilmiş oldu.

Anahtar Kelimeler

Prostat; Nöroendokrin; Tümör; Kemik; Metastaz

Abstract

Primary neuroendocrine tumors of the prostate are very rare and their biologic behaviour is not yet well described. A case of primary, prostatic, neuroendocrine tumor with bone metastasis is described. A 50-year-old man presented with a 6 months history of frequent urination, difficulty in urination and failure to empty the bladder. Transurethral prostate resection was performed and the pathological examination of the prostate tissue revealed a poorly-differentiated neuroendocrine carcinoma. Meanwhile, cervical magnetic resonance imaging that was planned due to the presence of neck pain revealed a mass lesion in the right paravertebral soft tissue and a pathological compression fracture of the C6 vertebral body. The patient underwent an operation in which C6 corpectomy, placement of homogenous bone graft and obtaining a biopsy specimen were performed. The pathological assessment of the biopsy revealed metastasis of a poorly-differentiated neuroendocrine carcinoma confirming the bone metastasis of the primary neuroendocrine tumor of the prostate.

Keywords

Prostat; Nöroendokrin; Tümör; Kemik; Metastaz

DOI: 10.4328/JCAM.768 Received: 03.08.2011 Accepted: 11.08.2011 Publihed Online: 01.01.2014 J Clin Anal Med 2014;5(1):67-68
Corresponding Author: Ersagun Karagüzel, Üroloji Ana Bilim Dalı, Karadeniz Teknik Üniversitesi Tıp Fakültesi, Trabzon, Türkiye.
Phone : +904623775908 GSM: +905325029672 Fax: +90462 3250518 E-mail: ersagunkaraguzel@gmail.com

Introduction

Adenocarcinomas constitute approximately 95% of all malignant tumors of the prostate, and although rare, neuroendocrine tumors of the prostate, such as carcinoid tumors or small-cell carcinomas may also be encountered.[1-4] Herein, a patient diagnosed with a primary neuroendocrine tumor of the prostate in our clinic in whom evidence of bone metastasis was subsequently detected is presented.

Case Report

A 50-year-old male patient was admitted to our clinic with the complaints of frequent urination, difficulty in urination and failure to empty the bladder persisting for 6 months. His medical history revealed an acute urinary retention 3 months ago, requiring treatment with a urinary catheter and an alpha-adrenergic blocker. The patient, for whom a surgical intervention was planned, underwent a rectal examination, which revealed a soft, smooth prostate of grade I enlargement. The prostate-specific antigen (PSA) level was 1.4 ng/mL and creatinine was 1.1 mg/dL. Urinalysis revealed no abnormal findings. Prostatic obstruction was detected on cystoscopy, and a transurethral prostate resection was performed. Meanwhile, a cervical magnetic resonance imaging that was planned due to the presence of neck pain revealed a mass lesion in the right paravertebral soft tissue and a pathological compression fracture of the C6 vertebral body (Figure 1). Subsequently, the patient underwent an operation in which C6 corpectomy, placement of homogenous bone graft and obtaining a biopsy specimen were performed. The pathological examination of the prostate tissue revealed a poorly-differentiated neuroendocrine carcinoma. The immunohistochemical analysis of the tumor cells revealed positivity for CD56, synaptophysin and pancytokeratin, but negativity for PSA, CD45 and CD99 (Figure 2). The pathological assessment of the materials obtained from the C6 corpectomy and biopsy revealed metastasis of a poorly-differentiated neuroendocrine carcinoma. The immunohistochemical analysis revealed focal, weak positivity for chromogranin, diffuse, strong positivity for CD56 and synaptophysin, and negativity for CD45 (Figure 3). The patient was referred to the medical oncology clinic due to the metastatic primary neuroendocrine tumor of the prostate.

Discussion

Primary neuroendocrine tumor of the prostate is a rarely seen tumor that originates from cells responsible for amine precursor uptake and decarboxylation.[4] These tumors most often metastasize to the lymph nodes, to the liver, lungs and bones.[5] Numerous cases have been described in the literature, most of which involve cases over 60 years of age. In the presentation of a case of pediatric age, a primary neuroendocrine tumor of the prostate in conjunction with multiple endocrine neoplasia IIb was described.[6] Furthermore, the incidence of neuroendocrine tumors is increased in individuals with Crohn's disease.[7] Moreover, neuroendocrine differentiation can be observed in 10%-100% of prostatic adenocarcinomas. Neuroendocrine cells are present in the prostate tissue, and display a widespread distribution in the prostate tissue at birth.[1,8,9] Prostate tumors that show neuroendocrine differentiation are considered to be subtypes of prostatic adenocarcinomas.[9] Some authors claim that tumors with neuroendocrine differentiation behave more aggressively and hence, it is necessary to differentiate conventional adenocarcinomas with neuroendocrine differentiation from pure neuroendocrine carcinomas.[10] The present case is a pure and metastatic neuroendocrine tumor of the prostate.

The fundamental treatment of pure primary neuroendocrine tumors of the prostate is radical prostatectomy. However, as in the present case, other treatment modalities are recommended in the presence of metastasis. While chemotherapeutic agents such as cisplatin and etoposide can be recommended in anaplastic variants, a good prognosis can be observed in well-differentiated tumors with no additional treatment.[11] Besides, radiotherapy can be applied for local tumor control and analgesia in the treatment of tumors of large volume, brain metastases, potential pathological fractures, and for bladder outlet obstructions. Due to the limited number of cases in the literature, our knowledge regarding the prognosis of advanced stage disease is thus far insufficient. As seen in the present case, the possibility of the presence of a neuroendocrine tumor of the prostate should also be kept in mind in patients presenting with lower urinary tract complaints who have normal PSA levels.

Competing interests

The authors declare that they have no competing interests.

References

1. Bostwick DG. Neoplasms of the prostate. In: Bostwick DG, Eble JN, eds. Urologic Surgical Pathology. St.Louis, Missouri: Mosby-Yearbook Inc.; 1997.p. 343-422.
2. Dauge MC, Grossin M, Doumecq-Lacoste JM, Vinceneux P, Delmas V, Bocquet L. Carcinoid tumor of the prostate. A new anatomoclinical case and review of the literature. Arch Anat Cytol Pathol. 1985;33:73-79.
3. Reyes A, Moran CA. Low-grade neuroendocrine carcinoma (carcinoid tumor) of the prostate. Arch Pathol Lab Med. 2004;128:e166-168.
4. Wasserstein PW, Goldman RL. Diffuse carcinoid of prostate. Urology 1981;18:407–409.
5. Lim KH, Huang MJ, Yang S, Hsieh RK, Lin J. Primary carcinoid tumor of prostate presenting with bone marrow metastases. Urology 2005;65:174.
6. Whelan T, Gatfield CT, Robertson S, Carpenter B, Schillinger JF. Primary carcinoid of the prostate in conjunction with multiple endocrine neoplasia IIb in a child. J Urol. 1995;153:1080–1082.
7. West NE, Wise PE, Herline AJ, Muldoon RL, Chopp WV, Schwartz DA. Carcinoid tumors are 15 times more common in patients with Crohn's disease. Inflamm Bowel Dis 2007;13: 1129–1134.
8. Cohen RJ, Glezerson G, Haffejee Z, Afrika D. Prostatic carcinoma: histological and immunohistological factors affecting prognosis. Br J Urol 1990;66:405-410.
9. Di Sant'Agnese PA. Neuoroendocrine differentiation in human prostatic carcinoma. Hum Patol. 1992;23:287-296.
10. Giordano S, Tolonen T, Tolonen T, Hirsimäki S, Kataja V. A pure primary low-grade neuroendocrine carcinoma (carcinoid tumor) of the prostate. Int Urol Nephrol. 2010; 42:683–687.
11. Moertel CG, Kvols LK, O'Connell MJ, Rubin J. Treatment of neuroendocrine carcinomas with combined etoposide and cisplatin. Evidence of major therapeutic activity in the anaplastic variants of these neoplasms. Cancer 1991;68:227–232.



Figure 1. Magnetic resonance imaging showing pathological compression fracture of the C6 vertebral body and metastatic mass lesion (arrow) in the right paravertebral soft tissue

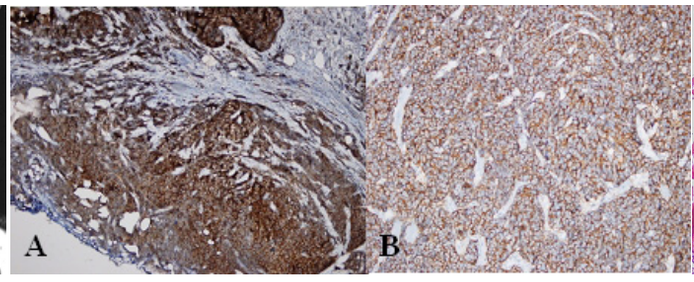

Figure 2. Immunohistochemical staining. (A) Neoplastic cells showing positivity for synaptophysin, (B) and for CD56

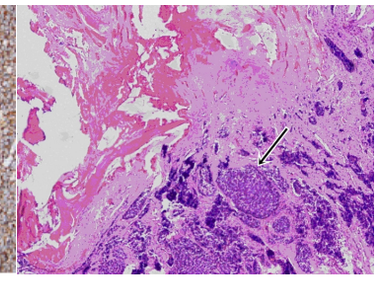

Figure 3. Islets of neoplastic cells (arrow) between the bone spicules