An Aneurysm of the Left Main Coronary Artery in a Patient with Metabolic Syndrome

Metabolik Sendromlu Bir Hastada Sol Ana Koroner Arter Anevrizması

Sol Ana Koroner Arter Anevrizması / An Aneurysm of the Left Main Coronary Artery

Muhammet R. Sayın, İbrahim Akpınar, Turgut Karabağ,
Bülent Ecevit Üniversitesi, Tıp Fakültesi, Kardiyoloji Anabilim Dalı, Zonguldak, Türkiye

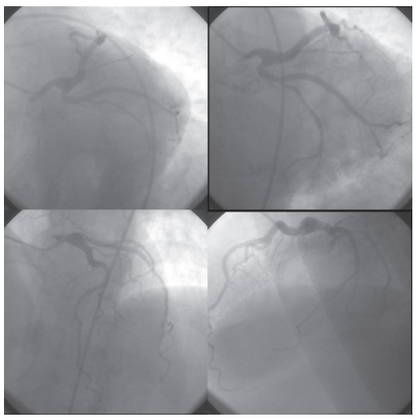

Figure 1.

A 68-year-old woman with prior history of hypertension, type 2 diabetes and dyslipidemia was presented at our hospital because of exertional dyspnea. On admission blood pressure was 145/80 mmHg, with a regular pulse of 78 bpm. Cardiovascular and other system examinations were entirely normal. The electrocardiogram showed sinus rhythm with no significant ST segment changes. The exercise treadmill stress test showed ST depression of 1.5 mm in leads V5-6. Coronary angiography revealed a giant aneurysm of the left main coronary artery with proximal ectasia of left anterior descending and circumflex artery (figure 1); the rest of the coronary tree was free of aneurysm and atherosclerosis. The patient was treated with aspirin, perindopril and atorvastatin.

Coronary artery aneurysm is a rare anomaly, which is described as the enlargement of coronary artery diameter to 1.5 times or more than its normal size. The incidence varies between 0.3% and 4.9% in different series. Most of the coronary artery aneurysms develop on the right coronary artery. Left main coronary artery aneurysms are extremely rare, and usually extend into the adjacent left anterior descending and circumflex artery proximal segments. Most of the cases are associated with atherosclerosis and Kawasaki disease. Coronary artery aneurysms should be treated according to existence of concomitant coronary artery disease. Patients with no obstructive coronary artery disease are recommended to be managed medically, while coronary bypasses should be performed when indicated by the severity of stenosis or progressive angina despite medical therapy.

References

1. Kyle SM, Lovie MJ, Dowie CS. Massive inguinal hernia. Br J Hosp Med 1990;43(5):383-4.
2. Serpell JW, Polglase AL, Anstee EJ. Giant inguinal hernia. ANZ J Surg 1988;58(10):831-4.
3. Mehendale FV, Taams KO, Kingsnorth AN. Repair of a giant inguinoscrotal hernia. Br J Plastic Surg 2000;53(6):529-9.
4. Weitzenfeld MB, Brown BT, Morillo G et al. Scrotal kidney and ureter: an unusual hernia. J Urol 1980;123(3):437-8.
5. Edward EM, Merril TD (1989) Pneumoperitoneum in Giant Hernia. Nyhus LM, Condon RE, (eds) Hernia 3rd ed. Philadelphia: Lippincott 36:521–30
6. Raynor RW, Del Guercio LR. The place for pneumoperitoneum in the repair of massive hernia. World J Surg 1989;13(5):581–5.
7. Stoppa RF. The treatment of complicated groin and incisional hernias. World J Surg 1989;13(5):545-54.
8. Morena IG. Chronic eventrations and large hernias. Surgery 1947:22(6):945-53.

DOI: 10.4328/JCAM.1113 Received: 28.05.2012 Accepted: 16.06.2012 Printed: 01.03.2014 J Clin Anal Med 2014;5(2): 174
Corresponding Author: Muhammet Raşit Sayın, Bülent Ecevit Üniversitesi, Tıp Fakültesi, Kardiyoloji Anabilim Dalı, Kozlu 67600, Zonguldak, Türkiye.
T.: +90 3722612162 F.: +90 3722610155 GSM: +905303112885 E-Mail: sayinmr@mynet.com