Simultaneous Bilateral Anterior Shoulder Dislocation Occurred During Sleepwalking

Uyurgezerlik Sırasında Meydana Gelen Eşzamanlı Bilateral Anterior Omuz Çıkığı

Bilateral Anterior Omuz Çıkığı / Bilateral Anterior Shoulder Dislocation

Fevzi Yılmaz, Cemil Kavalcı, Miray Özlem, Müge Sönmez
Ankara Numune Eğitim ve Araştırma Hastanesi, Acil Tıp Kliniği, Ankara, Türkiye

A 17-years-old male presented to our emergency department with a complaint of bilateral shoulder pain and motion restriction. His past medical history was unremarkable for epilepsy or major trauma. According to family history he was a sleepwalker since he was 5 or 6 years old and sometimes he was going to another place from his bed and when they saw him there were abrasions especially on his face and extremities. It was learned that he left the drugs given by the doctors for his complaint after using a short time. On physical examination, he was concious, cooperative and oriented. His vital signs and neurological examination were normal. His extremity examination revealed that his arms were slightly in abduction and external rotation. There was epaulet sign bilateral on his shoulders. His peripheral neurological examination was otherwise normal. The radiological evaluation revealed bilateral subchorocoidal anterior dislocation with no signs of fracture (Figure 1). After sedation closed reduction with kocher manevuer was performed initially. After reduction, forward flexion and abduction of each shoulder were over 75 degrees and immobilization with valpeau bandage was applied bilaterally for 3 weeks. There was no decrease in length of motion and muscular strength during 1-year follow-up and stability of each shoulder was normal.

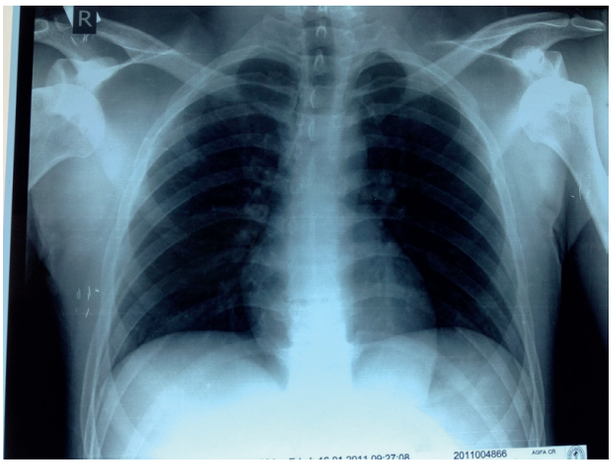

Figure 1. Anteroposterior radiograph of the shoulders showing bilateral subchorocoidal anterior dislocation with no signs of fracture.

DOI: 10.4328/JCAM.1235 Received: 01.08.2012 Accepted: 17.08.2012 Printed: 01.05.2014 J Clin Anal Med 2014;5(3): 271
Corresponding Author: Fevzi Yılmaz, Ankara Numune Eğitim ve Araştırma Hastanesi, Acil Tıp Kliniği, 06100 Altındağ, Ankara, Türkiye.
T.: +905055907307 F.: +90312 3125346 E-Mail: fevzi_yilmaz2002@yahoo.com