Catheter-Induced in-Stent Coronary Dissection

Kateter ile Oluşmuş Stent İçi Koroner Diseksiyon

Stent İçi Koroner Diseksiyon / In-Stent Coronary Dissection

Barış Buğan[1], Turgay Çelik[2], Atila İyisoy[2]
[1]Malatya Military Hospital, Cardiology Service, Malatya, [2]Gulhane Military Medical Academy, Department of Cardiology, Ankara, Turkey

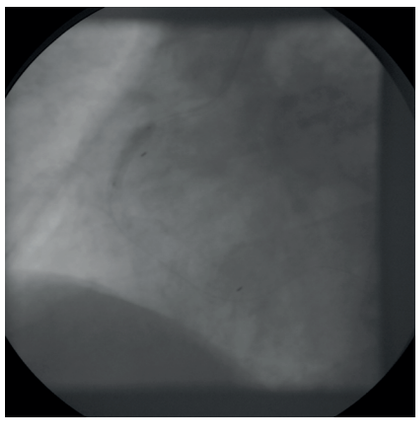

Figure 1. Coronary angiography showing the balloon dilatation of the restenotic segment

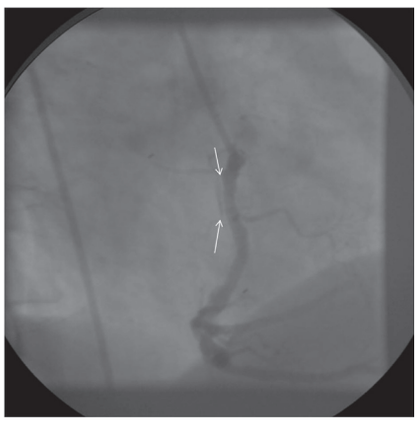

Figure 2. Coronary angiography showing in-stent coronary dissection (arrows),

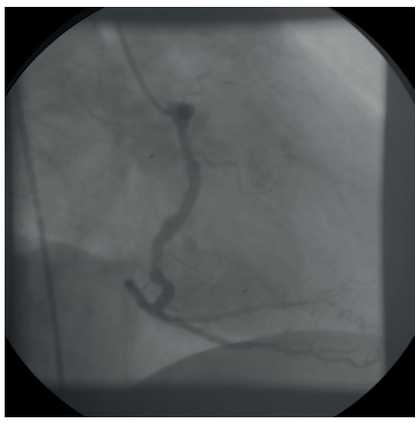

Figure 3. Control coronary angiography showing the same segment without dissection.

A 57-year-old male patient presented with exercise-induced angina for the last 10 days. The patient had undergone stent implantation in the right coronary artery (RCA) leading to acute myocardial infarction six months ago. The patient was on aspirin, klopidogrel, perindopril, and metaprolol succinate. Electrocardiogram showed sinus rhythm with Q waves in D2-3, aVF leads and ST-segment depression in V4-6 leads. Echocardiography depicted mild mitral regurgitation, and hypokinesis of the inferobasal segment with ejection fraction of 58%. Coronary angiography revealed 80% restenosis in the previously stented segment of RCA and 40% stenosis in the mid-segment of LAD. When the balloon dilatation of the restenotic segment was performed (Figure 1), in-stent dissection occurred (Figure 2). We decided to initiate tirofiban and heparin infusion during 24 hours. The patient was stable and cardiac enzymes remained normal. Control angiography showed that the dissection was disappeared (Figure 3). Two days later, he was discharged with same medications. The patient was totally asymptomatic at 6-month follow-up.

Coronary dissection is a well-known complication of percutaneous coronary intervention; however, in-stent dissection has been rarely reported. The clinical presentation ranges from asymptomatic to angina, acute myocardial infarction, and sudden cardiac death. Therapy options include conservative medical treatment and interventional treatment with PCI or surgery.

Consequently, in-stent coronary artery dissection is an unusual thinking but may occur either spontaneously or catheter-induced. All clinicians should keep in mind this complication and it's treatment should be tailored individually.

DOI: 10.4328/JCAM.1259 Received: 14.08.2012 Accepted: 23.08.2012 Printed: 01.05.2014 J Clin Anal Med 2014;5(3): 270
Corresponding Author: Barış Buğan, Malatya Military Hospital, Cardiology Service, Malatya, Turkey.
T.: +90 4223365434 F.: +90 4223362043 E-Mail: bbugan@hotmail.com