Borchardt Triade: A Symptom of Acute Gastric Volvulus

Borchardt Triadı: Akut Gastric Volvulusun Belirtisi

Borchardt Triadı / Borchardt Triade

Salim Bilici[1], Mehmet Göksu[1], Mehmet Melek[1], Fuat Sayır[2], Cihangir Akgün[3], Metin Simsek[1]
[1]Department of Pediatric Surgery, Yüzüncü Yıl University, Van, Türkiye.
[2]Thoracic Surgery, Faculty of Medicine, Yüzüncü Yıl University, Van, Türkiye.

Bu olgu 16-19 Mayıs 2011 tarihinde İstanbul'da gerçekleştirilen '29. Ulusal Çocuk Cerrahisi Kongresi ve Mısır Çocuk Cerrahisi Derneği Ulusal Kongresi' nde sunulmuştur.

Özet

Gastrik volvulus özellikle akut olgularda strangulasyon, perforasyon, peritonit, şok ve ölümle sonuçlanabilir. Çocuklarda nadirdir, fakat yaşamı tehdit ettiği için erken tanı ve tedavisi önemlidir. Akut gastrik volvuluslu hastalarda, klinik olarak üst abdomende veya alt toraksta ani başlayan şiddetli ağrı ve distansiyon, öğürmeye rağmen kusamama ve nazogastrik kataterin ilerletilememesi bulgularıyla karakterize Borchardt triadı gözlenebilir. Bu yazıda, Borchardt triadı ile tanı konan, diyafragma hernisi ve gezici (wandering) dalağın eşlik ettiği akut mezenteroaksiyal gastrik volvuluslu bir çocuk olgu sunularak Borchardt triadının vurgulanması amaçlandı.

Anahtar Kelimeler

Borchardt; Gastrik Volvulus; Çocuk

Abstract

Gastric volvulus, especially cases with an acute onset, may result in strangulation, perforation, peritonitis, shock and death. The disease is rarely seen in children, but early diagnosis and treatment is essential due to its life-threatening potential. In patients with acute gastric volvulus, the clinical Borchardt triade may be observed, which is characterized by acute severe pain and distension in the upper abdomen or lower thoracic region, retching and the inability to pass a nasogastric tube. In this article, We aimed to emphasize the Borchardt's triad by presenting a pediatric case who was diagnosed with Borchardt's triad and who had acute mesenteric axial gastric volvulus which diaphragmatic hernia and mobile (wandering) spleen were accompanied.

Keywords

Borchard; Gastric Volvulus; Children

DOI: 10.4328/JCAM.821 Received: 02.10.2011 Accepted: 18.10.2011 Printed: 01.07.2014 J Clin Anal Med 2014;5(4): 328-330
Corresponding Author: Salim Bilici, Department of Pediatric Surgery, Yüzüncü Yıl University, Van, Türkiye.
T.: +90 5053509630 F.: +90 4322167519 E-mail: salbilici@yahoo.com

Introduction

Gastric volvulus is the abnormal rotation of the stomach or a part of the stomach of at least 180 degrees around an axis leading to obstruction.[1] In acute cases in particular, it may result in strangulation, perforation, peritonitis, shock and death.[1,2] Acute gastric volvulus is rarely seen in children, but early diagnosis and emergency treatment is critical in terms of reducing the risk of mortality.[1-3] In 1904, Borchardt noted symptoms and signs of severe pain in the upper abdomen, retching and the inability to pass a nasogastric tube in these patients.[4] These three symptoms of acute volvulus are known as the Borchardt triade. The Borchardt triade is pathognomonic for acute gastric volvulus.

In this report, we have presented a pediatric patient with acute mesentero-axial gastric volvulus accompanied by diaphragmatic hernia and wandering spleen, exhibiting the clinical signs of Borchardt triade.

Case Report

A 3-year-old girl was brought to the hospital with the complaints of acute distention and severe pain in the epigastric region and non-productive retching that had been persisting for 8 hours. No such symptoms were present in the patient's history, but parents stated that she had experienced occasional vomiting since the age of one. On the physical examination, decreased general health and painful distention in the epigastric region were determined. Furthermore, there was a severe non-productive retching. Radiographic evaluation of the patient performed in the upright showed a gastric air filling the left half of abdomen and half of the thorax (figure 1). Insertion of a nasogastric tube was attempted, but it was not possible to move the tube further distal than 30 cm. Radiography with contrast material showed that the nasogastric tube formed a curve around gastro-esophageal junction and that the contrast material did not pass into the stomach. Emergency surgical intervention was performed with the suspected diagnosis of gastric volvulus. In laparotomy, the stomach was found to be severely distended and twisted with a torsion angle of 360 degrees in the mesentero-axial direction. Almost half of the stomach was seen to have herniated into the thorax through the posterolateral diaphragmatic defect. The patient had a wandering spleen with no torsion, the gastrocolic and the gastrosplenic ligaments were missing. The stomach was derotated by pulling it away from the thorax and primary repair of the diaphragmatic defect was performed. Anterior gastropexy and splenopexy were performed. No complications were observed following surgery and the patient was discharged 5 days after surgery. No clinical problems were observed during the one month follow-up.

Discussion

Gastric volvulus, a rare condition in pediatric patients, is the rotation of the stomach or a part of the stomach with an angle of at least 180 degrees, leading to full obstruction. Rotation or curving of the stomach with an angle of less than 180 degrees causes partial obstruction and this condition is called as "gastric torsion".[1] Gastric volvulus was first described in 1866 by Berti[4] in a 61-year-old female cadaver. Under normal conditions, the stomach is fixated to the abdominal cavity by the gastrocolic, gastrohepatic, gastrophrenic and the gastrosplenic ligaments. These ligaments, together with the gastro-esophageal junction and the pylorus, firmly fixate the stomach and prevent volvulus. Deficiency, loosening, agenesis or deformation of these ligaments may lead to idiopathic or primary gastric volvulus.[4] Moreover, secondary gastric volvulus may be seen secondarily in anomalies such as diaphragmatic hernia and eventrations or wandering spleen.[1,4] Gastric volvulus may present in three different types, according to the axis of rotation, namely, organo-axial, mesentero-axial and the mixed type.[1] In the case presented in this report, a mesentero-axial type gastric volvulus was seen, characterized by congenital agenesis of the gastric ligaments, diaphragmatic hernia and wandering spleen.

The clinical symptoms of gastric volvulus depend on the duration of onset, type of volvulus and extent of obstruction. Obstruction may manifest as an acute, recurrent or chronic condition.[1,4] In the acute type, as observed in our patient, severe pain in the upper abdomen or the lower thorax, distention and an unproductive retching is observed. With the addition of the inability to pass through the nasogastric tube, these three symptoms are described as the "Borchardt triade".[4] The incidence of this triade among adults is 30%, though it is seen less frequently in children.[5] Chronic gastric volvulus manifests with non-specific symptoms such as occasional postprandial pain of long duration, belching, early satiety, vomiting and distention.[2] The mortality rate in acute volvulus is three times more than in chronic volvulus. More than two-thirds of fatal outcomes in acute or chronic gastric volvulus are reported to be due to the delay in the diagnosis and the delay in appropriate surgical treatment.[1]

The treatment of gastric volvulus varies according to the type of volvulus. Treatment of acute gastric volvulus is surgical. Miller et al. reported the rate of mortality among non-operated cases as over 80%.[3] The primary procedures in surgical intervention are derotation of the volvulus, reduction of the herniated stomach, repair of the accompanying diaphragmatic hernia and fixation of the stomach to the anterior abdominal wall.[6] Although

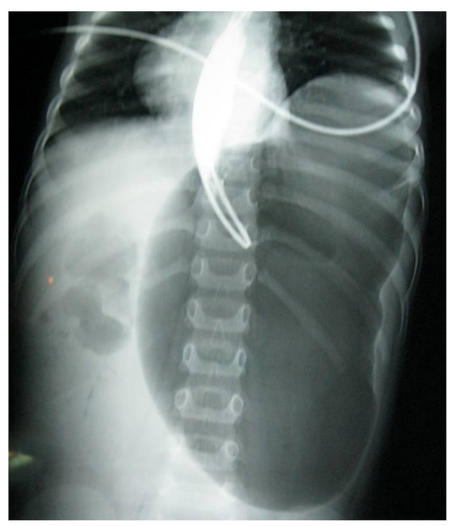

Figure 1. Plain abdominal roentgenogram showing gastric air filling the left half of abdomen and half of the thorax plus curving of the nasogastric catheter at the gastro-esophageal junction.

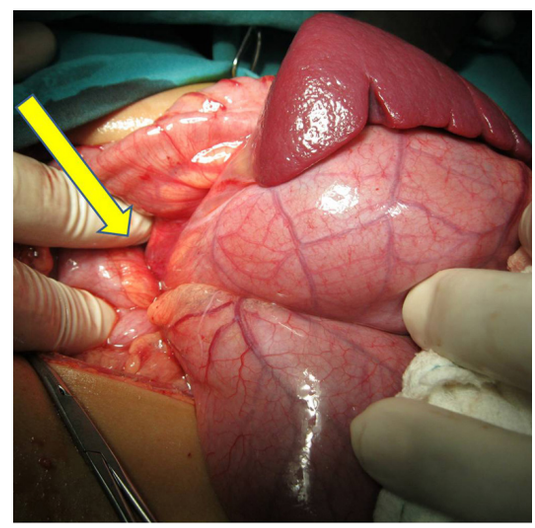

Figure 2. Torsion zone (yellow arrow)

a number of authors have suggested that simple reduction of the stomach without repair of the accompanying defect and fixation are sufficient for the treatment, other authors have stated this approach to be inappropriate.[7] In two pediatric patients with primary volvulus, recurrence was reported following simple reduction.[1] Similarly, recurrent volvulus was reported in a case where repair of hiatal hernia and Nissen fundoplication was performed without gastric fixation.[8] In our case, gastric detorsion, primary repair of the diaphragmatic hernia, anterior gastropexy and splenopexy were performed in laparotomy. Recently, especially in cases of chronic gastric volvulus, less invasive interventions such as endoscopic reduction have been used via laparoscopic surgery or by insertion of an endoscopic percutaneous gastrostomy tube.[4]

Acute gastric volvulus is a life-threatening condition. Due to the fact that early diagnosis and treatment reduce the mortality, acute gastric volvulus should always be considered in cases presenting with epigastric pain, distention and non-productive vomiting with an acute onset, it should not be overlooked that the diagnosis is possible by implementation of a nasogastric catheter and a simple radiogram.

Competing interests

The authors declare that they have no competing interests.

References

1. Cribbs RK, Gow KW, Wulkan ML. Gastric volvulus in infants and children. Pediatrics 2008,122(3):e752-62. Epub 2008 Aug 4.
2. Shivanand G, Seema S, Srivastava DN, Pande GK, Sahni P, Prasad R, et al. Gastric volvulus: acute and chronic presentation. Clin Imaging 2003,27(4):265-8
3. Miller DL, Pasquale MD, Seneca RP, Hodin E. Gastric volvulus in the pediatric population. Arch Surg 1991,126:1146–1149.
4. Rashid F, Thangarajah T, Mulvey D, Larvin M, Iftikhar SY. A review article on gastric volvulus: a challenge to diagnosis and management. Int J Surg 2010,8(1):18-24. Epub 2009 Nov 10.
5. Mayo A, Erez I, Lazar L, Rathaus V, Konen O, Freud E. Volvulus of the stomach in childhood: the spectrum of the disease. Pediatr Emerg Care 2001,17(5):344-8.
6. Kotobi H, Auber F, Otta E, Meyer N, Audry G, Helardot PG. Acute mesenteroaxial gastric volvulus and congenital diaphragmatic hernia. Pediatr Surg Int 2005,21:674-676.
7. Chattopadhyay A, Vepakomma D, Prakash B, Kumar V. Is gastropexy required for all cases of gastric volvulus in children? Int Surg 2005,90(3):151–154.
8. Stiefel D, Willi UV, Sacher P, Schwobel MG, Stauffer UG. Pitfalls in therapy of upside-down stomach. Eur J Pediatr Surg 2000,10(3):162–166.