Angiosarcoma of the Thyroid and Regional Lymph Node Metastasis

Tiroidin Anjiosarkomu ve Bölgesel Lenf Nodu Metastazı

Tiroidin Anjiosarkomu ve Metastazı / Angiosarcoma of the Thyroid and Metastasis

Lutfi Dogan[1], Niyazi Karaman[1], Cigdem Irkkan[2], Ali Kucuk[1], Can Atalay[1]
Department of General Surgery, Ankara Oncology Training and Education Hospital, Ankara, Türkiye.
[2]Department of Pathology, Ankara Oncology Training and Education Hospital, Ankara, Türkiye.

Presented in 17th National Surgical Congress, Ankara, Türkiye.

Özet

Tiroid anjiosarkomları tipik olarak infiltratif ve büyük tümörlerdir ve klinik bulguları anaplastik tiroid kanserine çok benzer. Erken hematojen yayılım çok sık iken, bölgesel lenf nodu metastazı oldukça nadirdir. Bu yazıda 68 yaşında bir erkek hastada bölgesel lenf bezi metastazı olan tiroid anjiosarkom olgusu bildirilmiştir. Hastaya total tiroidektomi ile birlikte sağ modifiye radikal boyun diseksiyonu uygulandı. Disseke edilen 19 lenf nodunun dördünde metastaz saptandı. Metastatik tümör çok sayıda kan dolu yarıkları içeren sarkomatöz alanlardan oluşmaktaydı. Ameliyattan sonra PET-CT çekilen hastada multipl metastazlar saptandı. Tiroid anjiosarkomları anjiomatoid anaplastik karsinomlardan tamamen farklı tümörlerdir. Bu tümörlerde uzun sağ kalım sadece agresif cerrahi ile mümkündür ve bölgesel lenf bezi metastazı varlığında boyun diseksiyonu yapılmalıdır.

Anahtar Kelimeler

Tiroid; Anjiosarkom; Metastaz

Abstract

Thyroid angiosarcomas are typically infiltrative and large tumors with very similar clinical findings of anaplastic carcinoma of thyroid. Early hematogenous metastasis is very frequent, but regional lymph node metastasis is quite rare. We present a case of angiosarcoma of the thyroid gland in a 68 years old man with regional lymph node metastasis. Total thyroidectomy with right modified radical neck dissection was applied. Four out of 19 lymph nodes dissected were seen to contain metastasis. Metastatic tumor was composed of sarcomatous areas containing large numbers of blood filled clefts. There after the surgery PET-CT was performed and multiple metastatic involvements were reported. Thyroid angiosarcomas are completely different tumors from angiomatoid anaplastic carcinomas. Longer survival with these tumors is only possible with agressive surgery and in case of regional LN metastasis, neck dissection should be done.

Keywords

Thyroid; Angiosarcoma; Metastasis

DOI: 10.4328/JCAM.828 Received: 14.10.2011 Accepted: 07.12.2011 Printed: 01.09.2014 J Clin Anal Med 2014;5(5): 425-427
Corresponding Author: Niyazi Karaman, Department of General Surgery, Ankara Oncology Training and Education Hospital, Ankara, Türkiye.
T.:+90 3122251869 F.: +90 3122251871 E-mail: niyazikaraman@hotmail.com

Introduction

The thyroid gland is composed of different cells like thyroid follicular cells, parafollicular cells, vascular endothelium and smooth muscle cells, lymphocytes, neuroendocrine cells, and connective tissues. Each of these cells have potential for malignant transformation to produce different types of cancers.[1] Angiosarcomas arise from blood or lymphatic vessels. The incidence is highest in European Alpine regions and it constitutes 2-10 % of all malignant thyroid tumors in Switzerland, Austria and northern Italy. In other parts of the world it is extremely rare.[2,3] In an analysis of 7023 thyroidectomy specimens reported from Singapore, only two angiosarcomas have been reported.[4]
The tumor is typically infiltrative, large with extensive areas of necrosis and hemorrhages. The clinical presentation is very similar to that of anaplastic carcinoma with a painless, rapidly enlarging mass.[5,6] Early hematogenous metastasis is very frequent and the lungs are the most frequent metastatic site.[7] Patients live for only a few months from the time of diagnosis if surgery can not be performed before extracapsuler extension.[8] We present a case of angiosarcoma of the thyroid gland in a 68 years old man.with atypical regional lymph node metastasis.

Case Report

Sixty eight years old male patient presented with a swelling on the right side of neck for the last six months. There was no symptoms like hoarseness, dyspnea, dysphagia and history of previously diagnosed goiter. At physical examination, a hard, tender, fixated and ill defined 5 cm mass was palpated in the right lobe of thyroid gland and there were two palpable lymph nodes (LN) on the same side of the neck. Other systemic examinations and laboratory tests including complete blood count, electrolytes, liver, kidney and thyroid functions were all within normal ranges. Computed tomographic (CT) examination of the neck and thorax revealed a heterogenous solid nodule with patchy calcifications in the right lobe of thyroid and multiple LNs with a maximum diameter of 2.5x1.5 cm in the same side of the neck. There were no pathologic findings other than fibrotic bands and chronic changes in both lung fields
Fine needle aspiration biopsy (FNAB) under radiological guidance was used both for the mass in the thyroid and LN in the neck. Both preparations revealed degenerated looking pleomorphic atypical cells in a necrobiotic background. Total thyroidectomy with right modified radical neck dissection was applied with the presumed diagnosis of thyroid carcinoma metastasized to the regional LNs. The mass in the right lobe was adherent to surrounding muscles and soft tissues with extracapsular extention. The postoperative period was uneventful.
Bilateral thyroidectomy specimen was composed of a 3,5x2,5x2 cm left lobe, 3x2x1 cm isthmus and 7,5x5,5x4 cm right lobe. On cut surfaces, left lobe and isthmus were normal but right lobe contained a 5,5x4x4 cm cream-yellow-brown colored heterogenous textured lesion. Microscopically, left lobe and isthmus were seen as normal thyroid tissue. The lesion in the right lobe had heterogenous histology which had areas of cavernous blood filled spaces, wide areas of necrosis and sarcomatous solid proliferation. The lesion was seperated from the thyroid tissue by a thick but discontinuous collagenous stromal reaction, which contained a lot of hemosiderin filled macrophages. In the solid sarcomatous areas, clefts occured between the cells. In other areas, these clefts were seen to be filled with erythrocytes and some of the tumor cells even formed intracytoplasmic lumen with erythrocytes in it (Figure 1). Tumor cells were highly atypical with 5 mitosis per 10 high power field. Extension to the extrathyroid adipocytic soft tissues was seen. Tumor cells were diffusely reactive for CD31 and F8, whereas focally for CD 34 immunohistochemically. From the right neck dissection, 4 out of 19 lymph nodes were seen to contain metastasis. Same as the tumor in the thyroid, metastatic tumor was composed of sarcomatous areas containing a large number of blood filled clefts (Figure 2). There after the surgery, PET-CT was performed and multiple metastatic involvements were reported in lungs and bones.

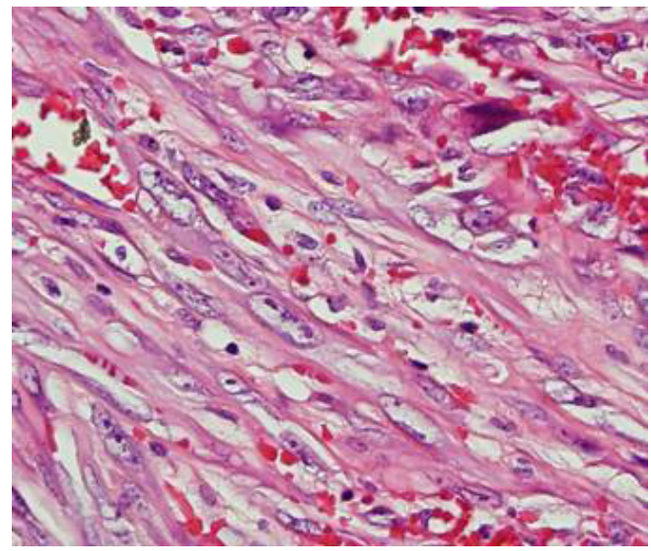

Figure 1. Blood filled clefts between the highly atypical cells with some forming intracytoplasmic lumen containing erythrocytes (HE, x400).

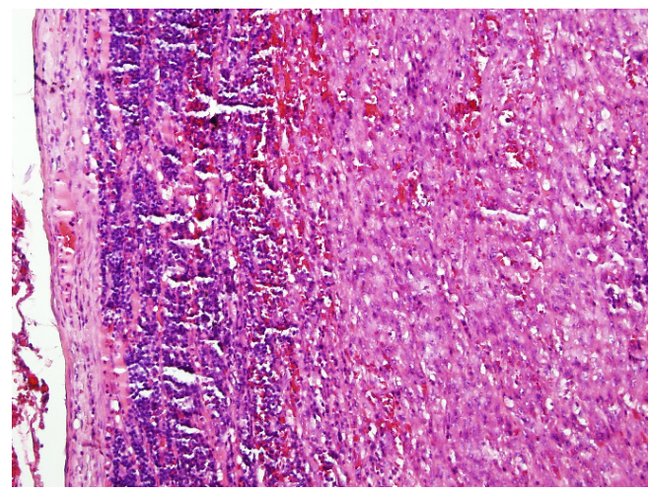

Figure 2. Metastatic angiosarcoma in the lymph node rich in blood filled clefts (HE, x200).

Discussion

Malignant vascular tumors known as agressive tumors with

poor prognosis represent one of the rarest forms of soft tissue malignancies, comprising less than 1% of all sarcomas. They can occur at any location in the body. Angiosarcomas represent one of the major histological subtypes of malignant vascular tumors. The term angiosarcoma is commonly used for all sarcomas showing endothelial differentiation whether they originate in the vascular or lymphatic endothelium.[9,10] Angiosarcomas have a predilection for cutaneous sites, especially in the head and neck region of elderly male patients.[11] Leowardi et al. analysed 43 malignant vascular tumors and reported only two thyroid angiosarcomas.[12] The nearly exclusive presence of these tumors in the Alpine goiter regions and their progressive decline in incidence with the advent of iodine prophylaxis, suggests chronic goiter as a predisposing risk factor.[13] The case presented here also does not have history of goiter like some other cases in literature presented without previous goiter history.[14] As these tumors are large with extensive areas of necrosis and hemorrhage, they may resemble to hematoma. For this reason, the diagnosis with fine needle aspiration biopsy (FNAB) is very difficult.[15,16] Both FNAB preparations of our case were also composed of degenerated looking pleomorphic atypical cells in a necrobiotic background. Immunohistochemistry provides the key diagnostic tool with positive staining for factor VIII-related antigen, CD34 (a hematopoietic progenitor cell antigen), CD31 (a vascular cell-to-cell adhesion molecule), and Ulex Europaeus Ilectin (an endothelial marker), but negative staining for most epithelial markers.[16-18]

The second most frequent metastatic site after the lungs is bone marrow. Thyroid angiosarcomas presented with anemia were also reported.[19] Regional LN metastasis is quite rare for these tumors.[11] During our literature search, we have seen a report from Slovenia about the presence of radiologically detectable enlarged LNs.[3] But we could not find any report on histologically verified regional LN metastasis.

The metastasis was not diagnosed with preoperative CT examinations. Both lung and bone metastasis were diognosed with postoperative pozitron emission tomographic (PET-CT) examinations. The development of distant metastasis shortly after the surgery makes us think about the presence of micrometastasis that were not able to be diagnosed before surgery.[20] Clinical studies on angiosarcomas introduced that these tumors and their metastasis show functional activity with PET-CT early in their progression.[21]

Lobectomy was settled for total thyroidectomy was for some cases reported in literature due to adjasent tissue invasion.[4,14] The survival for these cases was limited for few months. Recent molecular, immunohistochemical and ultrastructural studies have shown that thyroid angiosarcomas are completely different tumors from angiomatoid anaplastic carcinomas.

Regional LN metastasis of these tumors is an occurence. Longer survival with these tumors is only possible with agressive surgery and whenever a regional LN metastasis is detected, neck dissection should be tried. New therapeutic advances will only be possible with increased knowledge about thyroid angiosarcomas.

Competing interests

The authors declare that they have no competing interests.

References

1. Burman KD, Ringel MD, Wartofsky L. Unusual types of thyroid neoplasms. Endocrinol Metab Clin North Am 1996; 25: 49-68.
2. Chan YF, Ma L, Boey JH, Yeung HY. Angiosarcoma of the thyroid. An immunohistochemical and ultrastructural study of a case in a Chinese patient. Cancer 1986; 57: 2381-2388.
3. Ryska A, Ludvíková M, Szépe P, Böör A. Epithelioid haemangiosarcoma of the thyroid gland. Report of six cases from a non-Alpine region. Histopathology 2004; 44: 40-46.
4. Goh SG, Chuah KL, Goh HK, Chen YY. Two cases of epithelioid angiosarcoma involving the thyroid and a brief review of non-Alpine epithelioid angiosarcoma of the thyroid. Arch Pathol Lab Med 2003; 127: 70-73.
5. Lamovec J, Zidar A, Zidanik B. Epithelioid angiosarcoma of the thyroid gland. Report of two cases. Arch Pathol Lab Med 1994; 118: 642-646.
6. Lin O, Gerhard R, Coelho Siqueira SA, de Castro IV. Cytologic findings of epithelioid angiosarcoma of the thyroid. A case report. Acta Cytol 2002; 46: 767-771.
7. Hassan I, Barth P, Celik I, Hoffmann S, Langer P, Ramaswamy A, et al. An authentic malignant epithelioid hemangioendothelioma of the thyroid: a case report and review of the literature. Thyroid 2005; 15: 1377-1381.
8. Sniezek JC, Holtel M. Rare tumors of the thyroid gland. Otolaryngol Clin N Am 2003; 36: 107-115.
9. Maddox JC, Evans HL. Angiosarcoma of skin and soft tissue: a study of forty-four cases. Cancer 1981; 48: 1907-1921.
10. Holden CA, Spittle MF, Jones EW. Angiosarcoma of the face and scalp, prognosis and treatment. Cancer 1987; 59: 1046-1057.
11. Behranwala KA, A'Hern R, Omar AM, Thomas JM. Prognosis of lymph node metastasis in soft tissue sarcoma. Ann Surg Oncol 2004; 11: 714-719
12. Leowardi C, Hinz U, Hormann Y, Wente MN, Mechtersheimer G, Willeke F, et al. Malignant vascular tumors: clinical presentation, surgical therapy, and long-term prognosis. Ann Surg Oncol 2005; 12: 1090-1101.
13. Hedinger C. Geographic pathology of thyroid diseases. Pathol Res Pract 1981; 171: 285-292.
14. Kalitova P, Plzak J, Kodet R, Astl J. Angiosarcoma of the thyroid. Eur Arch Otorhinolaryngol 2009; 266: 903-905.
15. Astl J, Dusková J, Límanová Z, Povýsil C, Kuchynková Z. Hemangiosarcoma of the thyroid gland. A case report. Neuro Endocrinol Lett 2000; 21: 213-216.
16. Isa NM, James DT, Saw TH, Pennisi R, Gough I. Primary angiosarcoma of the thyroid gland with recurrence diagnosed by fine needle aspiration: a case report. Diagn Cytopathol. 2009 Jun;37(6):427-32.
17. Cutlan RT, Greer JE, Wong FS, Eltorky M. Immunohistochemical characterization of thyroid gland angiomatoid tumors. Exp Mol Pathol 2000; 69: 159-164.
18. Mills SE, Gaffey MJ, Watts JC, Swanson PE, Wick MR, LiVolsi VA, et al. Angiomatoid carcinoma and 'angiosarcoma' of the thyroid gland. A spectrum of endothelial differentiation. Am J Clin Pathol 1994; 102: 322-330.
19. Yilmazlar T, Kirdak T, Adim S, Ozturk E, Yerci O. A case of hemangiosarcoma in thyroid with severe anemia due to bone marrow metastasis. Endocr J 2005; 52: 57-59.
20. Samaan NA, Ordoñez NG Uncommon types of thyroid cancer. Endocrinol Metab Clin North Am 1990; 19: 637-648.
21. Schwarzbach MH, Dimitrakopoulou-Strauss A, Willeke F, Hinz U, Strauss LG, Zhang YM, et al. Clinical value of [18-F] fluorodeoxyglucose positron emission tomography imaging in soft tissue sarcomas. Ann Surg 2000; 231: 380-386.