Lipoma Arborescens of the Knee

Dizde Lipoma Arboresens

Lipoma Arboresens / Lipoma Arborescens

Mehmet Erdil, Yunus İmren, Kerem Bilsel, Hasan Hüseyin Ceylan, İbrahim Tuncay
Orthopaedics & Traumatology Department, Bezmialem Vakıf University, İstanbul, Türkiye.

Bu olgu sunumu 31 Ekim-5 Kasım 2011 tarihleri arasında Antalya'da düzenlenen 22. Ulusal Ortopedi ve Travmatoloji Kongresi'nde poster bildirisidir.

Özet

Lipoma arboresens nadir görülen bir intraartiküler tümördür. En sık diz eklemi tutulumu görülmekle birlikte literatürde kalça ve omuz gibi diğer eklemlerin tutulumu da bildirilmiştir. Literatürde az sayıda ilgili makale mevcuttur.Nadir gözlenen bu durumun patolojisi ve tedavisindeki tıbbi bilgiyi geliştirmeye yönelik bir olgu sunmaktayız. 20 yaşında kadın hasta sağ dizinde ağrı ve şişlik şikayetiyle başvurdu. Muayenesinde suprapatellar bölgede şişlik ve lokal hassasiyet mevcuttu. MRI incelemesinde diz ekleminde ve suprapatellar bölgede belirgin sıvı artışı,suprapatellar bursa içerisinde tüm sekanslarda yağlı doku ile izotens görünümde lipoma arboresens ile uyumlu lezyonlar dikkati çekmekteydi. Cerrahi olarak tümüyle çıkarılan kitlenin histopatolojik incelemesi ameliyat öncesi tanıyı doğruladı. Bu olgu sunumunda nadir görülen eklem içi bir tümörde muayene ve histopatolojik incelemenin önemi vurgulanmıştır. Bu tür tümoral lezyon şüphesinde ilgili eklemin manyetik rezonans incelemesi ve kitlenin cerrahi olarak tümüyle çıkarılması çok iyi sonuç vermektedir.

Anahtar Kelimeler

Lipoma Arboresens; Diz; Eklemiçi; Sinovyum

Abstract

Lipoma Arborescens is a rare intra-articular tumor. Knee is the most commonly affected joint, whereas ankle, hip, shoulder and elbow may be involved. There are few case reports published in the literature. We report a case with lipoma arborescens in the knee joint to improve the medical knowledge about the pathology and management of this rare entitiy. 20-year-old Caucasian female patient admitted to outpatient clinic with complaints of swelling and pain in her right knee. There was swelling and local tenderness in the suprapatellar region. Magnetic resonance imaging (MRI) findings include significant effusion in knee joint and suprapatellar compartment, remarkable suprapatellar mass was drawing attention at all sequences which have an isointense view with fat tissue. Tumor was resected totally, and the preoperative diagnosis of lipoma arborescens is confirmed after histopathological examination. This report notes the significance of both physical and histopathologic examination for the confirmation of such a rare intra-articular entity. When such lesions are suspected, MRI of the joint is necessary and total excision of the mass yields excellent outcome.

Keywords

Lipoma Arborescens; Knee; Intra-Articular; Synovium

DOI: 10.4328/JCAM.847 Received: 05.11.2011 Accepted: 13.12.2011 Printed: 01.09.2014 J Clin Anal Med 2014;5(5): 428-430
Corresponding Author: Mehmet Erdil, Orthopaedics & Traumatology Department, Bezmialem Vakıf University, İstanbul, Türkiye.
T.: +02124531700 /1776 E-mail: drmehmeterdil@gmail.com

Introduction

Lipoma arborescens is a rare intra-articular tumor [1, 2]. Knee joint involvement is most frequently seen but also involvements of other joints such as hip and shoulder have been reported in literature. Villous lipomatous proliferation of synovial tissue is typical on histological examination. Open or arthroscopic synovectomy of the joint is the general approach in the treatment. Long-standing complaints can progress to osteoarthritis of the affected joint. 20-year-old female patient admitted to outpatient clinic with complaints of swelling and pain in her right knee. There was swelling and local tenderness in the suprapatellar region. MRI findings include significant effusion in knee joint and suprapatellar compartment, remarkable suprapatellar mass was drawing attention at all sequences which have an isointense view with fat tissue. Tumor was resected totally, and the preoperative diagnosis of lipoma arborescens is confirmed after histopathological examination. Patient's complaints recovered after surgical excision and no recurrence was observed in two-year follow-up period. Lipoma arborescens should be considered in the differential diagnosis of patients with chronic knee pain and swelling. In those, MRI evaluation is necessary in addition to physical examination for the early diagnosis of the intraarticular problems. Definitive diagnosis is established by histopathological examination. Recurrence is rare after surgical excision.

Case

20 year old woman had swelling and knee pain resistant to non-surgical treatment for 2 years without any history of trauma. Examination reveals suprapatellar swelling (Figure 1A) and tenderness in her right knee. There was no warmth difference comparing to the contralateral side, and the range of motion was painful. She was evaluated according to Tegner Activity Scale (TAS) with 2 points. Pre-operative laboratory values were normal. X-ray examinations revealed no pathologic findings except for soft tissue expansion.Relevant effusion in suprapatellar region with evident suprapatellar plica was seen in MR evaluation. Furthermore, in all sequences the lesion had the same intensity as fatty tissue and also Baker cyst with 40x20x10 mm in diameter was observed (Figure 1B,1C,1D). Excision was planned with pre-diagnosis of lipoma arborescens. Median parapatellar incision was performed and tumoral lesion with villous character that fully filled suprapatellar pouch was observed and excised (Figure 2A, 2B). In the histopathologic evaluation of three different yellow-brown masses with the largest one was 90x60x30 mm in dimension, benign lipomatous regions covered by synovial epithelium and chronic inflammation areas were detected (Figure 2C). The hypertrophic synovial tissue advanced through the intercondylar notch. Grade 1-2 chondropathy in patellar surface and trochlea. These findings are compatible for lipoma arborescens as pre-existent of chronic synovitis. After the surgery, clinical findings regressed. Full range of motion of the knee without pain was achieved at the end of fourth week. No recurrence was observed at the second year follow-up with 8 points according toTAS.

Discussion

Lipoma Arborescens is a rare pathology that was firstly described by Arzimanoglu in 1957 [3]. Clinical diagnosis is usually delayed because of the rare incidence of this lesion that leads non-specific symptoms such as swelling and pain. In an MR study, 6387 knees were evaluated in 9 years and only 9 Lipoma Arborescens were reported with 7 diffuse involvements and with 2 nodular involvements without synovial hypertrophy [4]. Joint movements can be restricted according to the mass effect and effusion. The most common involvement is unilateral knee joint. There are some reports of bilateral knee joint involvement, and also multiple joint involvements with bilateral knee, bilateral wrist and bilateral hand [5]. Lipoma arborescens originates from suprapatellar pouch of the knee joint whereas lipoma and hemangioma of the knee originates from infrapatellar pouch.
Differential diagnosis includes synovial lipoma, synovial chondromatosis, synovial hemangioma, infectious synovitis, xantoma, amyloid arthropathy, and villonodular synovitis with the ability of leading soft tissue in suprapatellar pouch [1]. Most of the soft tissue tumors arise from either synovium or surrounding tissues without joint involvement. Rarely, it originates from tendon sheaths [6]. Differential diagnosis of seldom pediatric cases include juvenile romatoid arthritis, acute rheumatic fever, vascular malformations, Behcet disease, meniscal malformations, and synovial enchondromatosis [7]. Congenital short bowel syndrome and medial meniscus agenesis may accompany with lipoma arborascens [1, 5]. Definitive diagnosis is late because of mild symptoms and lipoma arborescens should be excluded in persistent knee pain. Although synovial reaction secondary to trauma is considered to be an etiologic factor, most of the patients do not have history of trauma [8]. Lymphoplasmocytic infiltration under synovial cells is seen in histologic sections. In addition, mature adipocyte hypertrophy in subsynovial tissue and synovial villous proliferations are typical [4]. Sub-

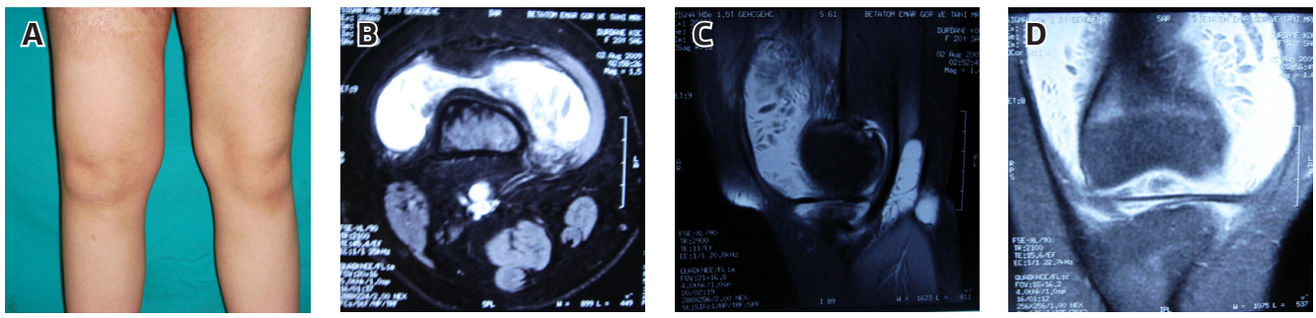

Figure 1. Clinical view of swelling on the right knee (A) Axial, sagittal and coronal sections of right knee MR (B, C, D)



Figure 2. Per-operative view of lesion (A) Macroscopic view of the biopsy specimen (B) Histopathologic view. (C)

chondral bony erosions due to synovial invasion can be seen on direct views. Thorough physical examination and MR imaging can hold key to early diagnosis. On T1 and T2 weighted MR images, isointense villous lipomatous proliferation leading to typical fernlike appearance, joint effusion, subsynovial fat deposits, bony erosions on joint line, and degenerative changes can be detected [4]. Definitive diagnosis is made on histopathologic examination.Treatment approach is usually open or arthroscopic synovectomy. Besides, radioactive ablation with yttrium-90 has favorable outcomes. Despite synovectomy, osteoatrhritis may progress in long-term.

Conclusion

Lipoma Arborescens is a very rare benign primary intra-articular tumor of the synovium with non-specific symptoms. The most important point is accurate diagnosis achieved by both clinical suspicion and imaging.Good to excellent outcomes can be easily obtained with open excision.

Competing interests

The authors declare that they have no competing interests.

References

1. Utkan A, Ozkan G, Köse CC, Ciliz DS, Albayrak AL. Congenital absence of the medial meniscus associated with lipoma arborescens. Knee 2010;17(3):258-60.
2. Kim RS, Song JS, Park SW, Kim L, Park SR, Jung JH, Park W. Lipoma arborescens of the knee. Arthroscopy 2004;20(1):95-9.
3. Arzimanoglu A. Bilateral arborescent lipoma of the knee. J Bone Joint Surg Am 1957;39:976-9.
4. Iovane A, Sorrentino F, Pace L, Galia M, Nicosia A, Midiri M, Bartolotta TV, De Maria MR findings in lipoma arborescens of the knee: our experience. M Radiol Med 2005;109(5-6):540-6.
5. Siva C, Brasington R, Totty W, Sotelo A, Atkinson J. Synovial lipomatosis (lipoma arborescens) affecting multiple joints in a patient with congenital short bowel syndrome. J Rheumatol 2002;29(5):1088-92.
6. Dogramaci Y, Kalaci A, Sevinç TT, Atik E, Esen E, Yanat AN. Lipoma arborescens of the peroneus longus and peroneus brevis tendon sheath: case report. J Am Podiatr Med Assoc 2009;99(2):153-6.
7. Ramsey SE, Cairns RA, Cabral DA, Malleson PN, Bray HJ, Petty RE. Knee magnetic resonance imaging in childhood chronic monoarthritis. J Rheumatol 1999;26:2238-43.
8. Sailhan F, Hautefort P, Coulomb A, Mary P, Damsin JP. Bilateral lipoma arborescens of the knee a case report. J Bone Joint Surg Am 2011;93(2):195-8.