A Case of the Kartagener Syndrome Accompanied by Pectus Carinatus Deformity

Pektus Karinatus Deformitesinin Eşlik Ettiği Kartagener Sendromu

Kartagener Sendromu / Kartagener Syndrome

Mahmut Tokur[1], Naime Tokur,[2] Derya Yenibertiz[3], Celalettin Korkmaz[3]
[1] Department of Thoracic Surgery, Medicine Faculty, Kahramanmaras Sutcu Imam University,
[2] Clinic of Pediatri, Kahramanmaras State Hospital, [3] Clinic of Chest Dsease, Kahramanmaras State Hospital, Kahramanmaras, Turkey

Türk Göğüs cerrahisi derneği 5. yıllık kongresi-2009. P 25.

Özet

Klinik ve radyolojik olarak Kartagener Sendromu (KS) tanısı konulmuş olan yedi yaşındaki kız çocuk hasta; sık balgam çıkarma, öksürük, yüksek ateş şikayeti ile getirildi. Hastanın fizik muayene ve radyolojik incelemelerinde; situs inversus totalis, yaygın sinüzit, harab olmuş sağ alt lob, sol orta lobda bronşektazi, pektus karinatus deformitesi saptandı. Uzun süreli medikal tedaviye rağmen pulmoner semptomlar kontrol altına alınamadığı için hastaya sağ alt lobektomi yapıldı. Literatürde KS ile nadir birlikteliklerden bahsedilmiş ancak toraks deformiteli olguya rastlanmamıştır.

Anahtar Kelimeler

Kartagener Sendromu; Pektus Karinatus; Bronşektazi

Abstract

A seven year old female patient diagnosed as a Kartagener Syndrom (KS) by the findings of clinical and radiological, was brought to the hospital with the complaints such as expectoration sputum often, cough and fever. Situs inversus totalis, pansinusitis, destroyed right lower lobe, bronchiectasis in the left middle lobe and pectus carinatus deformity were detected in the physical examination and radiological investigations of the patient. Although long-term medical therapy pulmonary symptoms couldn't get under control. Because of this right lower lobectomy was performed to the patient. In the literature it is mentioned that KS can be with rare togetherness but patient with thoracic deformities were not encountered.

Keywords

Cartagener Syndrom; Pectus Carinatus; Bronchiectasis

DOI: 10.4328/JCAM.845 Received: 01.11.2011 Accepted: 13.12.2011 Printed: 01.11.2014 J Clin Anal Med 2014;5(6): 518-519
Corresponding Author: Mahmut Tokur, Kahramanmaraş Sütçü İmam Üniversitesi, Tıp Fakültesi, Göğüs Cerrahisi Anabilimdalı, Yörükselim Mahallesi, Hastane Caddesi 46100 Kahramanmaraş, Türkiye. T.: +90 344 2257575/138 F.: +90 344 2212371 E-mail: mahmuttokur@hotmail.com

Introduction

KS is a rare congenital malformation and the classic triad of it is; situs inversus totalis, bronchiectasis and sinüsitis. In these patients, there is impaired mucociliary clearance according to the abnormally movement or immobility of ciliaries. It shows autosomal recessive inheritance, the incidence is aproximately 1/15.000- 20.000 [1].

Case Report

A seven-year-old female patient with KS was brought with the complaints such as often expectoration purulent sputum, cough and fever. There were situs inversus totalis, destroyed lower right lobe, minimal bronchiectasis in the left middle lobe, pansinusitis and pectus carinatus deformity in the patient's physical examination and radiological investigations (Figure 1-2). In the laboratory analysis; Leukocyte: 17800/mm ^{3}, Hb: 14.0 g / dl, ESR: 53 mm/h, were found respectively. Pseudomonas aeruginosa proliferated in the patient's sputum culture. In the analysis of arterial blood gas was pH: 7:33, PaCO2: 48.4 mmHg, PaO2: 89 mmHg, O2 Sat: 93% respectively. Patient couldn't accord with the pulmonary function test. Sinus tachycardia was in electrocardiography, the echocardiography was normal. Family history was negative.

Despite the long-term medical therapy pulmonary symptoms couldn't get control under and because of this right lower lobectomy applied to the patient.

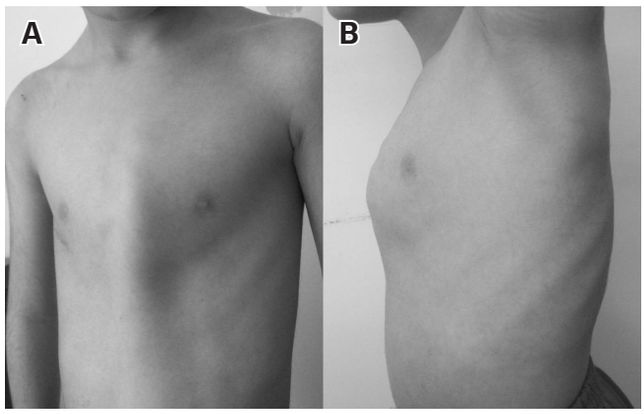

Figure 1. Patients with evidence of pectus carinatum. (A-B)

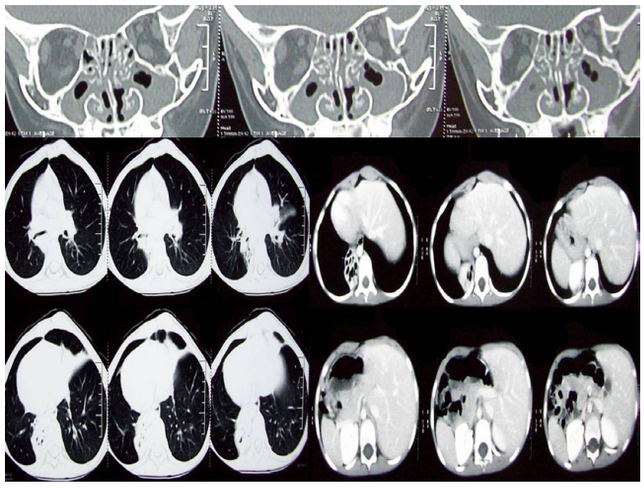

Figure 2. The patient's CT images: sinusitis, right lower lobe bronchiectasis, pectus carinatus deformity and situs inversus.

Discussion

The triad of KS consist of situs inversus, bronchiectasis and sinusitis was defined by Siewart in 1903 as the first time. In these cases, infections and sputum retention develop in the upper and lower respiratory tract as a result of ciliary motility disorder [1]. Chronic productive cough, rhinitis, sinusitis, otitis media and recurrent pulmonary infections, constitute of the clinical table of the disease. There are no symptoms at birth, but the symptoms can appears sometimes in early childhood. Chronic or recurrent infections cause bronchiectasis in the childhood and early adult years [2,3]. In our case right lower lobe became destroyed and bronchiectasis developed in the left middle lobe.

There is no specific treatment modality to cure KS completely. Treatment intend to clean the respiratory system secretions and get control under of infections. Antibiotic treatment is used for the acute bacterial exacerbations, bronchodilator therapy is used and also chest physiotherapy is used for the excretion of the secretions [2-4].

Non-surgical methods such as the destruction of bronchial wall and irreversible dilatation are defined for the treatment of bronchiectasis as first choice methods. The purpose in the surgical treatment of bronchiectasis is to resection of the all bronchiectatic areas to make the patients asymptomatic. The patients with KS that have severe problems because of bronchiectasis can be applied bronchiectasis surgery [5]. Lobectomy was carried out to our case because of destroyed right lower lobe.

Various organ pathologies can be seen with KS. It has been reported abnormalities such as congenital heart disease, esophageal disease, biliary atresia, hydrocephalus, Marfan's syndrome, hipoglossi, renal and pancreatic dysplasia, Hirschsprung's disease, varicocele and the small intestine malrotations polysplenia and kyphoscoliosis [2,6].

It was reported the incidence of chest wall deformities is 1/300-400 live births and the prevalence of chest wall deformities is 0.07-1%. Chest wall deformities may accompany other congenital anomalies [7].

In our case, the classic signs of KS and pectus carinatu deformity were determined. This state is can be evaluated that Marfan syndrome, kyphoscoliosis are rare conditions attended Kartagener or it may also sporadic togetherness.

Conclusion

It can be seen the concomitance of another congenital pathologies to the classic triad of KS. These congenital pathologies can be the component of the KS or can be incidental. It will be registered in the future with the contribution of the cases that come in literature.

Competing interests

The authors declare that they have no competing interests.

References

1. Afzelius BA. Immotile cilia syndrome: past, present and prospects for the future. Thorax 1998;53(10):894-7.
2. Behrman RE, editor. Nelson Texbook of Pediatrics. 17th ed. Philadelphia: wb Saunders; 2000. p.1391.
3. De Iongh RU, Rutland J: Ciliary defects in healthy subjects, bronchiectasis, and primary ciliary dyskinesia. Am J Respir Crit Care Med 1995;151(5):1559-67.
4. Webber BA, Pryor JA, editors. Bronchiectasis, primary ciliary dyskinesia and cystic fibrosis, Physiotherapy for Respiratory and Cardiac Problems. Tokyo: Churchill Livingstone; 1993.p.402-4.
5. Agasthian T, Deschamps C, Trastek VF, Allen MS, Pairolero PC. Surgical management of bronchiectasis. Ann Thorac Surg 1996;62(4):976-8.
6. Yakan B, Mirici A, Görgüner M, Girgiç M, Mısırlıoğlu F. Kifoskolyoz ve Kongenital Kardiak Anomaliler ile Birlikte Seyreden Kartagener Sendromlu Bir Hastanın Silya Ultrastrüktürü. Türkiye Klinikleri Tıp Dergisi 1996;16(6):458-60.
7. Shamberger RC. Chest wall deformities. In: Shields TW,LoCicero III J, Ponn RB, editors. General Thoracic Surgery. 4th ed. Philadelphia: Lippincott Williams & Wilkins; 2000.p.535-61.