Lobar Carina Resection and Reconstruction in the Cases with Carcinoid Tumor

Karsinoid Tümörlü Olguda Lober Karina Rezeksiyonu ve Rekonstrüksiyonu

Karsinoid Tümörde Sleeve Rezeksiyon / Carcinoid Tumor in Sleeve Resection

Mahmut Tokur[1], Hasan Kahraman[2], Fuat Özkan[3], Derya Yenibertiz[4], Nurhan Atilla[4]
[1] Department of Thoracic Surgery, Medicine Faculty, Kahramanmaras Sutcu Imam University, [2]Department of Chest Dsease, [3]Department of Radiology, [4] Clinic of Chest Dsease, Kahramanmaras State Hospital, Kahramanmaras, Turkey

Türk Toraks Derngi 14. yıllık kongresinde sunulmuştur.

Özet

Olgumuzda sol akciğer alt lob üst lob ayırım karinasında tipik karsinoid tümör saptandı. Hastaya pnömonektomi yerine lober karina rezeksiyonu ve rekostrüksiyonu yapıldı. Akciğer parankimini korumak için uygun vakalarda sleeve rezeksiyonlar pnömonektomiye tercih edildi. Teknik güçlüğüne rağmen uygun vakalarda başarıyla uygulanabilen lober karina rezeksiyonu, bir sleeve rezeksiyon varyantı olarak değerlendirilmelidir.

Anahtar Kelimeler

Karsinoid Tümör; Lober Karina; Sleeve

Abstract

In our case a typical carcinoid tumor was determined that settled in the seperation of lower lobe and upper lobe bronchi of left lung. Lobar carinal complet resection and lobar carinal reconstruction were performed to the only localizaton of tumor in the patient instead of pneumonectomy. Because of the maintaining the lung parenchymal tissue, sleeve rezections should be preferred to the pneumonectomy in the appropiate cases. In the selective cases such as our case, lobar carinal resections although they are technically difficult should be evaluated as a variant of sleeve resection.

Keywords

Carcinoid Tumor; Lobar Carina; Sleeve

DOI: 10.4328/JCAM.852 Received: 10.11.2011 Accepted: 13.12.2011 Printed: 01.11.2014 J Clin Anal Med 2014;5(6): 515-517
Corresponding Author: Mahmut Tokur, Department of Thoracic Surgery, Medicine Faculty, Kahramanmaras Sutcu Imam University, Street Yörükselim, Kahramanmaras, 46100 Turkey T.: ++90 344 2257575, F.: ++90 344 2212371 Email: mahmuttokur@hotmail.com

Introduction

Sleeve resections are resections that applied with different variations in the benign diseases, low-grade malignancies, and bronchial cancers for protect the parenchym [1]. Lobar carinal resection was carried out in our case as an alternative to pneumonectomy.

Case

Twenty-six-year-old female patient resorted to the our policlinic because of hemoptysis. In her history we have learned that she had been treatening with a diagnosis of asthma for approximately one year and she has had chronic cough, shortness of breath that don 't respond to treatment and recurrent hemoptysis for the last two months. Computerized Thorax Tomography (CT) was applied to the patient and in the left lower lobe air trapping was determined. In her fiberoptic bronchoscope (FOB) endobronchial lesion (EBL) that had obstructed the left main bronchus completely was detected. Needle biopsy that had been taken from tle lesion was consistent with a typical carcinoid tumor. When the coronal scans of the CT were checked it was seen that the distal of the EBL was open (Figure 1).

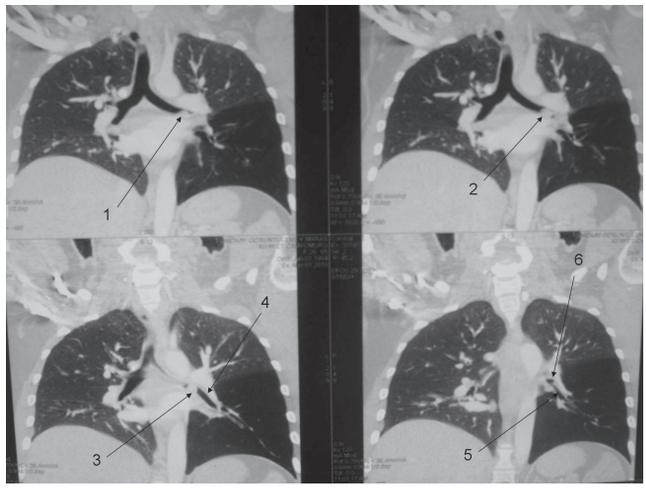

Figure 1. Preoperative chest computed tomography coronal sections: 1-2-3) dating back to the left main bronchus in the secondary hull EBL 4-5) of the lower lobe bronchus open 6) open the upper lobe bronchus

Left thoracotomy was carried out to the patient. With Karlens tube, ventilation of the left bronchial system was blocked. Accompanied by FOB bronchotomy was performed to the proximal of EBL in left main bronchia (Figure 2). Lobar carinal was excised because of not being tumor on the upper and lower lobe bronchia that are distal of the lesion (Figure 3). First reconstruction of the upper-lower lobe bronchus and then the reconstruction of left main bronchus were performed. After the detection of the full ekspansation of the left lung the operation was terminated. In the postoperative third month all bronchial system was seen as open and the air trapping that on the left lower lobe was seen as absent by CT and FOB (Figure 4).

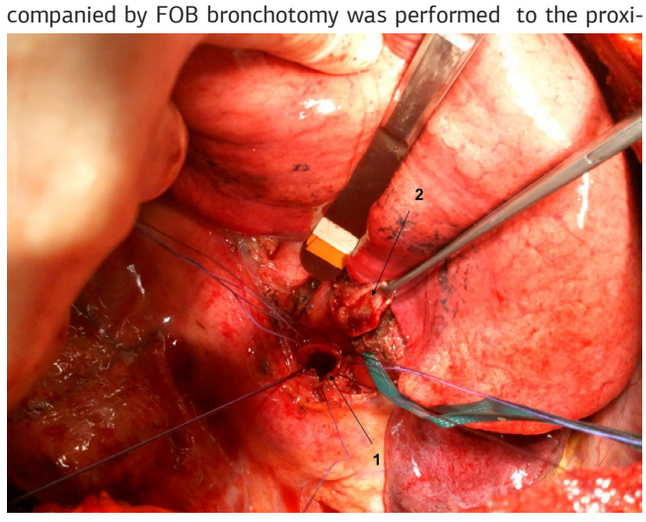

Figure 2. To the top of the left main bronchus EBL bronchotomy: 1) the left main bronchus 2) EBL

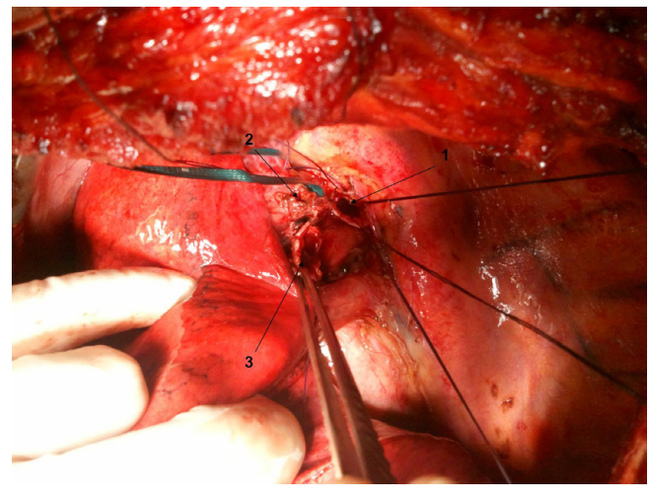

Figure 3. Lobar keel after excision of view: 1) the left main bronchus 2) upper lobe bronchus 3) the lower lobe bronchus

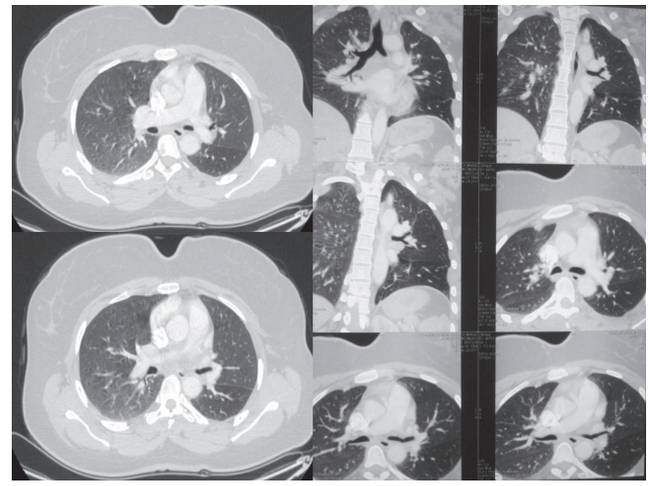

Figure 4. Postoperative 3 months CT imaging.

Discussion

Bronchial carcinoid tumors arising from neuroendocrine cells of are seen rarely grow slowly and grow by making local invasion [2]. While tumors that located in peripheral zone are usually asymptomatic in central located tumors findings of endobronchial obstruction are seen. The classic symptoms are cough, hemoptysis and recurrent pulmonary infections [3]. With bronchoscopy 80% of the cases can be diagnosed but it should be borne in mind that hemorrhage can develop during the processing [2].
Long-term prognosis is quite good in the carcinoid tumors. The 5-year survival for typical carcinoid tumors is above of 85%, for atypical carcinoid tumors is above of the 50%. It has been found that age and gender don't affect the prognosis [4].

The treatment of these tumors is complete surgical resections that aplied by maintaining lung tissue as possible. For this purpose, wedge resection, segmentectomy, bronchotomy, mass extirpation or sleeve resection can be used as technique. Videothoracoscopic surgery that a minimally invasive method,may be an alternative method for selected cases accompined by peripheral typical carsinoid [5,6].

Endobronchial treatment methods can be used in patients that surgical therapy is contraindicated. The morbidity rate of sleeve resections is in interval of 2.5-11% interval and mortality rate is in interval of 1.3%-7.7% . The most feared complication is the seperation of anastomose border in the early period [6,7].

İn literature lobar carinal resections are mentioned a few. It is seen that lobar carinal resections are easy method because of not have ventilation difficulty but they are more diffucult technically due to deal with small scale bronchus when it is compared with the main carina resections [8,9,10].

Conclusion

Sleeve resections should be preferred to the pneumonectomy in proper cases, because of the lung parenchymal tissue is maintained . In the selective cases such as our case, lobar carinal resections should be regarded as a variant of a sleeve resection .

Competing interests

The authors declare that they have no competing interests.

References

1. Regnard JF, Perrotin C, Giovannetti R, Schussler O, Petino A, Spaggiari L, et al. Resection for tumors with carinal involvement: technical aspects, results, and prognostic factors. Ann Thorac Surg 2005;80(5):1841-6.
2. Conley YD, Cafoncelli AR, Khan JH, Khan MZ, Aburahrna AF, Boland JP. Bronchial carcinoid tumor: experience over 20 years. Am Surg 1992;58(1):670-2.
3. Kosmidis PA. Treatment of carcinoid of the lung. Curr Opin Oncol 2004;16(2):146-9.
4. Cardillo G, Sera F, Martino M, Graziano. P, Giunti R, Carbone L, et al. Bronchial carcinoid tumors: Nodal status and long-term survival after resection. Ann Thorac Surg 2004;77(5):1781-5.
5. Solaini L, Bagioni P, Prusciano F, Francesco FD, Poddie DB. Video-assisted thoracic surgery lobectomy for typical bronchopulmonary carcinoid tumors. Surg Endosc 2000;14(12):1142-5.
6. Iglesias M, Belda J, Baldo X, Gimferrer JM, Catalán M, Rubio M, et al. Bronchial carcinoid tumor: A retrospective analysis of 62 surgically treated cases. Arch Bronconeumol 2004;40(5):218-21.
7. Suen HC, Meyers BF, Guthrie T. Favorable results after sleeve lobectomy or bronchoplasty for bronchial malignancies. Ann Thorac Surg 1999;67(6):1557-62.
8. Lucchi M, Melfi F, Ribechini A, Dini P, Duranti L, Fontanini G, et al. Sleeve and wedge parenchyma-sparing bronchial resections in low-grade neoplasms of the bronchial airway. J Thorac Cardiovasc Surg 2007;134(2):373-7.
9. Okur E, Baysungur V, Gokce M, Halezeroglu S. A Case of Carcinoid Tumor who Underwent Lobar Carina Resection and Reconstruction. Tur Toraks Der 2010;11(2):131-3.