Uncommon Asymptomatic Unilateral Complete Duplicated Collecting System and Giant Ectopic Ureterocele in Middle-Age Patient

Orta Yaşta Nadir Görülen Asemptomatik Tek Taraflı Komplet Duplike Toplayıcı Sistem ve Dev Ektopik Üreterosel

Orta Yaşta Asemptomatik Dev Üreterosel / Asymptomatic Giant Ureterocele in Middle-Age Patient

H. İbrahim Serin[1], Sebahattin Albayrak[2], M. Fatih Erkoç[1], Kursad Zengın[2], Yurdanur Akyuz[1]
[1]Department of Radiology, [2]Department of Urology, Bozok University, School of Medicine, Yozgat, Turkey

Özet

Üreterosel yaygın pediatrik ürolojik bir problemdir, fakat yetişkinlerde nadiren bildirilmektedir. Çoğu çift toplayıcı sistem üreterosel erken yaşta idrar yolu enfeksiyonları ile ortaya çıkmaktadır. Yetişkin yaşta ortaya çıkması yaygın değildir. Dilate distal üreter segmentindeki idrar stazı idrar yolu enfeksiyonları ve taş oluşumuna neden olur ve en yaygın ortaya çıkma yakınmaları idrarda yanma, ani idrar yapma isteği ve tekrarlayan idrar yolu enfeksiyonlarıdır. Çift toplayıcı sistemdeki nonfonksiyone veya kötü fonksiyonlu kısımların heminefroüreterektomisi kesin çözümdür. Biz orta yaşta nadir görülen bir asemptomatik, tıkayıcı, dev üreterosel vakasını sunmaktayız. Biz tıkayıcı, dev, ektopik üreterosel ve çift toplayıcı sistem hastasının asemptomatik olabileceğini vurgulamayı amaçladık.

Anahtar Kelimeler

Asemptomatik; Üreterosel; Komplet Duplike Toplayıcı Sistem

Abstract

Ureterocele is a common pediatric urologic problem, but has been reported seldom in adults. Most duplex system ureteroceles existent as urinary tract infections at an early age, with adult presentation being uncommon. Urinary stasis in the dilated distal ureter often lends to urinary infection and stone formation; precluding the most common offering symptoms of dysuria, urgency, and recurrent urinary tract infections. İn duplex system ureteroceles to poorly or non-functioning moieties, heminephroureterectomy is an definite solution. We present a case of rarely middle-age asymptomatic obstructive giant ureterocele. We intended to emphasize that patient with obstructive, giant, ectopic ureterocele and duplicated collecting system may have asymptomatic course.

Keywords

Asymptomatic; Ureterocele; Complete Duplicated Collecting System

DOI: 10.4328/JCAM.2698 Received: 25.07.2014 Accepted: 05.08.2014 Printed: 01.02.2014 J Clin Anal Med 2014;5(suppl 1): 29-31
Corresponding Author: H. İbrahim Serin, Department of Radiology, Bozok University, School of Medicine, 66000, Yozgat, Turkey.
T.: +90 3542127060 F.: +90 3542177150 E-Mail: raddrhiserin@gmail.com

Introduction

Ureterocele is a cystic dilatation anomaly of distal ureter with an incidence of 1:500-2000 at childhood. It is 4 to 7-folds more common among girls. Complete ureter duplication is primarily seen in ureter that drain upper pole by 80% [1]. Complete renal pelvis and ureter duplication is the most common anomaly of upper urinary tract [2].

In duplicated systems, ureterocele is observed at the ureter draining upper pole and vesicoureteral reflux (VUR) is generally seen at the ureter of ipsilateral lower pole [3].

Ureterocele, vesicoureteral reflux (VUR) and ectopic ureter may be seen in association with duplicated collecting system anomaly and some syndromes can accompany to duplex system anomaly. In addition, it can lead problems such as kidney stone and urinary infections [4]. Here we presented incidentally diagnosed unilateral complete duplicated collecting system with ureterocele without urological complaint in middle-age.

Case Report

A 52 years old man presented to our gastroenterology outpatient clinic with gastrointestinal complaints (stomachache, and dyspepsia). He had no urinary complaint. There was no previous history of urinary tract infections or urinary stone disease. He did not have any systemic disease and did not pass on any surgical intervention. General physical examination and digital rectal examination was normal. Urinalysis were not abnormal. Serum creatinine level was 0.9 mg/dL, serum prostate specific antigen level 1.25 ng/mL. On sonographic evaluation, grade 4 ureterohydronephrosis was observed at upper pole of left kidney. Dilated ureter had a calibration reaching 28 mm and extended up to bladder. Lower pole of left kidney had normal appearance. A suspicious appearance suggesting ureterocele was observed in bladder lumen. MR urography was performed with initial diagnoses of duplicated collecting system in left kidney and ureterocele.

On MR urography, there was complete duplication in left kidney and grade 4 ureterohydronephrosis at upper pole. It was seen that ureter draining upper pole was highly dilated (3 cm) with tortuous appearance.In bladder lumen, an ectopic ureterocele (approximately 55x48 mm in size) was observed. The upper pole of the kidney did not function in technetium-99m dimercaptosuccinic acid renal scintigraphy. Voiding cystourethrography showed absence of a vesico-ureteral reflux.

The patient was recommended upper-pole nephroureterectomy but the patient decided not to have surgical procedure. At follow up, three months later, the patient still had no urological complaints. Serum creatinine levels were measured as 1.1 mg/dL.There was no infection in the urine culture.

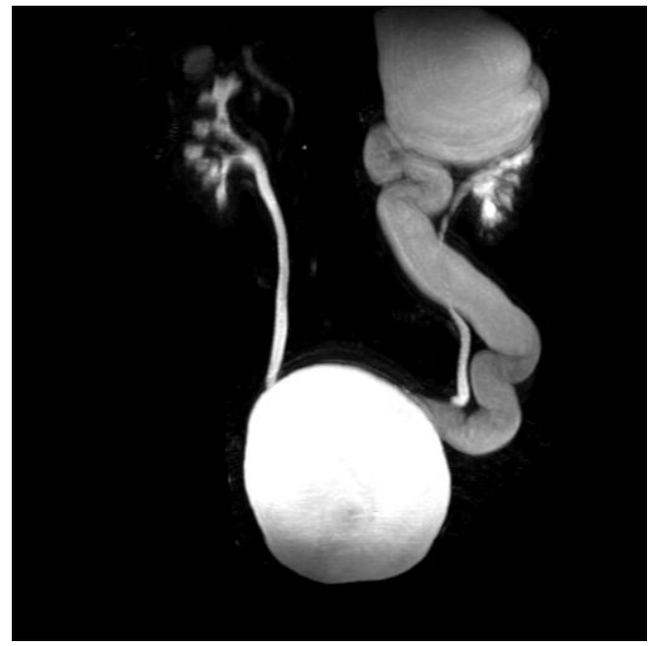

Figure 1. The image of unilateral complete duplicated collecting system in MR urography

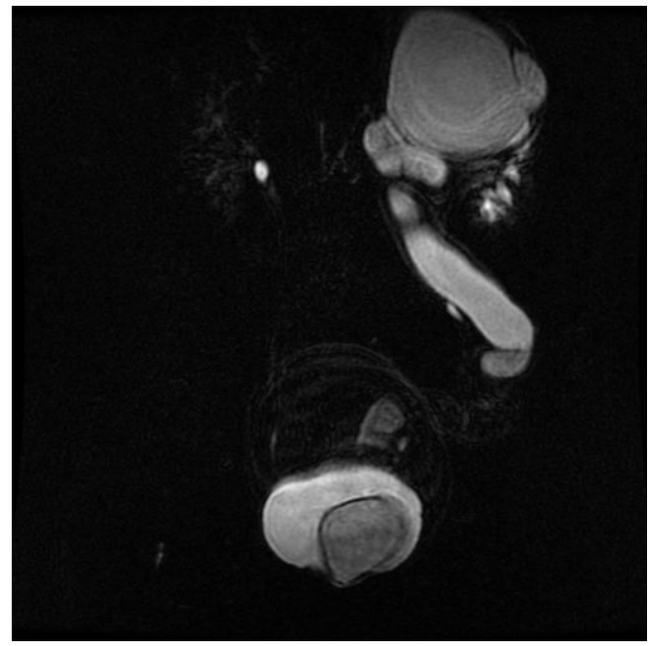

Figure 2. The image of mass due to ureterocele in MR urography

Discussion

Ureterocele, while not an uncommon pediatric urologic problem, has been reported only rarely in adults [5]. The presentation of ureterocele is highly variable. In the plurality of cases it is identified by antenatal ultrasound scan, and urinary tract infection continues to be the most common presentation postnatally [6]. The ureteroceles usualy stay asymptomatic and/or unrecognized in adult [5]. A large ureterocele can sometimes prolapse and obstruct the bladder outlet [1]. Most duplex system ureteroceles existent as urinary tract infections at an early age, with adult presentation being uncommon [7]. Urinary stasis in the dilated distal ureter often lends to urinary infection and stone formation; precluding the most common offering symptoms of dysuria, urgency, and recurrent urinary tract infections. Patients may present with hematuria, pyelonephritis, and abdominal pain. Urinary incontinence or retention may also be seen if the ureterocele bring about an obstruction at the level of the bladder. [5]. Our case is a 52-years old man who had no urological complaint during the entire life. It is interesting that there was duplication at left kidney, hydronephrosis at upper pole and giant ectopic ureterocele at ureter draining upper pole but not vesicoureteral reflux at lower pole and upper pole. Obstructive, giant and ectopic ureterocele case is notable to be asymptomatic in 52 years old patient.

The most appropriate treatment for duplex-system ureterocele is variable and eristic. A more conservative method by endoscopic incision has replaced the traditional invasive treatment [6]. In patients with an ectopic ureterocele and no vesicoureteral reflux partial nephrectomy should be thought the treatment of selection [8]. In our case, the patient was recommended upper-pole nephroureterectomy but he did not accept a surgical procedure.

To best of our knowledge, obstructive, giant and ectopic ureterocele has been reported unusually without urological complaint in middle-age. We intended to emphasize that patient with obstructive, giant, ectopic ureterocele and duplicated collecting system may have asymptomatic course.

Competing interests

The authors declare that they have no competing interests.

References

1. Merlini E, Lelli CP. Obstructive ureterocele-an ongoing challenge. World J Urol 2004;22(2):107-14.
2. Jednak R, Kryger JV, Barthold JS, Gonzalez R. A simplified technique of upper pole heminephrectomy for duplex kidney. J Urol 2000;164(4):1326-8.
3. Vates TS, Bukowski T, Triest J,Freedman A, Smith C, Perlmutter A, et al. Is there a best alternative to treating the obstructed upper pole? J Urol 1996;156(2):744-6.
4. Keating MA. Ureteral duplication anomalies: Ectopic ureters andureteroceles. In: Docimo SG, Canning DA, Khoury AE, editors. TheKelalis-King-Belman Textbook of Clinical Pediatric Urology . 5th ed. London: Informa Healthcare; 2007. p. 593-647.
5. Hoşcan M, Ekinci M, Tunçkıran A, Menekşe M. Unusual Clinical Presentation of Bilateral Adult Non-Obstructing Ureteroceles Containing Urinary Stones. J Clin Anal Med 2010;1(1):57-9.
6. Chertin B, de Caluwe D, Puri P. Is primary endoscopic puncture of ureterocele a long-term effective procedure? J Pediatr Surg 2003;38(1):116-9.
7. Van DHJ, Montagne GJ, Newling DW. Bilateral intravesical duplex system ureteroceles with multiple calculi in an adult patient. Scand J Urol Nephrol 1995;29(2):223-4.
8. Husmann D, Strand B, Ewalt D, Clement M, Kramer S, Allen T. Management of ectopic ureterocele associated with renal duplication: a comparison of partial nephrectomy and endoscopic decompression. J Urol 1999;162(4):1406-9.

How to cite this article:
Serin Hİ, Albayrak S, Erkoç MF, Zengın K, Akyuz Y. Uncommon Asymptomatic Unilateral Complete Duplicated Collecting System and Giant Ectopic Ureterocele in Middle-Age Patient. J Clin Anal Med 2014;5(suppl 1): 29-31.