A Surgical Repair Tecnique for High Partial Abnormal Pulmonary Venous Return

Yüksek Açılımlı Parsiyel Anormal Pulmoner Venöz Dönüşte Cerrahi Onarım Tekniği

Anormal Pulmoner Venöz Dönüş / Abnormal Pulmonary Venous Return

Onur Isik, Muhammet Akyuz, Nurjan Narymbetov, Mehmet Fatih Ayik, Yüksel Atay
Department of Cardiovascular Surgery, Medical Faculty of Ege University, Izmir, Turkey

Özet

Süperiyor vena kavaya (SVC) olan parsiyel anormal pulmoner venöz dönüş (PAPVD) sinus venozus atriyal septal defekli hastaların %10 ile %15 kadarında görülmektedir. SVC'ye dökülen PAPVD anomalisinin onarımı için birçok teknik tarif edilmiştir. Bu olgu sunumunda yüksek açılımlı parsiyel anormal pulmoner venöz dönüş onarımı için uyguladığımız etkili ve pratik olan onarım tekniğini tartıştık.

Anahtar Kelimeler

Pulmoner Ven; Superiyor Vena Kava; Persistan Sol Superiyor Vena Kava

Abstract

Partial anomalous pulmonary venous connection (PAPVC) to the superior vena cava (SVC) occurs in about 10% to 15% of patients with sinus venosus atrial septal defect. Various surgical techniques have been described to repair PAPVC draining into the SVC. In this report we discuss a practical and efficient repair technique for high partial abnormal pulmonary venous return.

Keywords

Pulmonary Vein; Superior Vena Cava; Persistent Left Superior Vena Cava

DOI: 10.4328/JCAM.2874 Received: 01.10.2014 Accepted: 22.10.2014 Printed: 01.02.2014 J Clin Anal Med 2014;5(suppl 1): 117-9
Corresponding Author: Muhammet Akyüz, Medical Faculty of Ege University, Department of Cardiovascular Surgery, 35100, Izmir, Turkey.
T.: +90 2324441343 F.: +90 2323900002 E-Mail: drmak100@gmail.com

Introduction

Partial anomalous pulmonary venous connection (PAPVC) to the superior vena cava (SVC) occurs in about 10% to 15% of patients with sinus venosus atrial septal defect. Various surgical techniques have been described to repair PAPVC draining into the SVC. However, repair with the 1-patch technique of high PAPVC, results in obstruction of the anomalous pulmonary veins or even the SVC. The 2-patch repair technique across the SVC-right atrial (RA) junction, designed to enlarge the cavoatrial channel, may cause sinoatrial node dysfunction [1]. Considered as an alternative to these technics, the Warden procedure itself also has complications such as sinus node dysfunction and SVC obstruction [2]. The current study reports the authors procedure of simple and corrective surgery to high PAPVC on a SVC patient.

Case Report

A 7-year-old boy was admitted to our clinic for PAPVC repair. He did not have a history of rheumatologic disease or rheumatic fever. The physical examination was within normal limits without cardiac murmur. On cardiac examination, he had pansystolic murmur in the second intercostal space on the left side. The patient's clinical vital parameters were normal and oxygen saturation was 97%. Electrocardiogram showed sinus rhythm and right axis deviation. Transthoracic echocardiogram (TTE) revealed a large sinus venosus atrial septal defect and right pulmonary veins draining anomaly. No other associated cardiac malformations were demonstrated. Contrast computer tomography revealed the same pathology (Figure 1A), but abnormal pulmonary vein drainage was high in the superior vena cava (SVC) (Figure 1B).

After the surgical consent, median sternotomy was performed. After meticulous dissection of the SVC all right sided pulmonary veins are seen draining to SVC. There was a good caliber innominate vein and larger persistent left SVC (PLSVC) draining to the coronary sinus. PLSVC prepared for cannulation; aortic-bicaval cannulation (selective high SVC cannulation) was performed, and cardiopulmonary bypass started. After aortic cross clamping and antegrade blood cardioplegia administration, a right atriotomy was performed. Coronary sinus, which was PLSVC draining into, cannulated with a separate venous cannula and snared. Autologous pericardium is used to suture the margin of the sinus venosus defect, baffling the SVC orifice to direct blood flow into the left atrium. SVC divided at the level of innominate vein junction. Right atriotomy closed primarily and the operation was complete. After an uneventful recovery, the patient was discharged on the postoperative fifth day. Postoperative anti-agregant therapy was administered for eight weeks after surgery. At the sixth month control, the patient was free of symptoms, rhythm was sinus, and computer tomography showed unobstructed flow of cephalic and subclavian veins draining to the persistent left SVC and to the right atrium via coronary sinus (Figure 2).

Discussion

Superior sinus venosus atrial septal defect is a form of interatrial defect, which in most cases is associated with partial anomalous pulmonary venous connection with the right pulmonary vein draining into the right atrium from the superior vena cava, at the cavoatrial junction or directly into the right atrium[2]. The principle for sinus venosus ASD surgical repair involves redirecting the pulmonary venous blood back to the left atrium and closure of the atrial septal defect without compromising the adjoining structures. The most threatening complications are arrhythmia and obstruction of the caval or pulmonary venous channel.

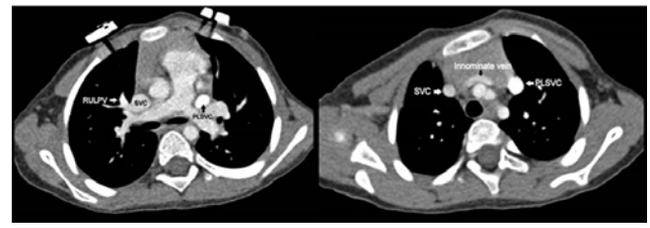

Figure 1. Preoperative CT image of abnormal pulmonary veins and left innominate vein and which are draining to superior vena cavae.

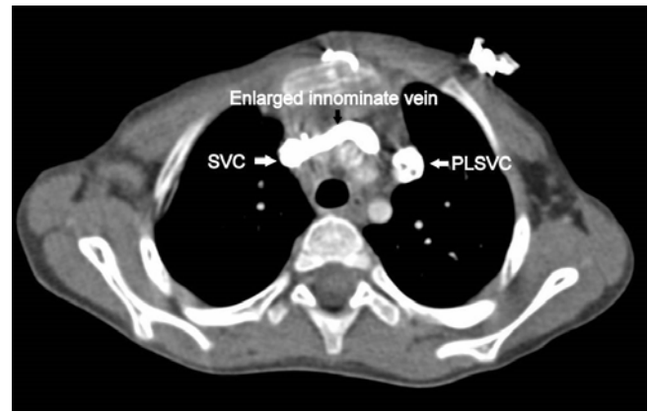

Figure 2. Postoperative CT image of right innominate vein draining to right arium via persistant left superior vena cava.

The most widely known and used surgical techniques include single patch repair, repair through transcaval incision, and Warden modifications. Among these techniques, the single patch technique offers an easy-to-perform technique and low rate of complications in the repair of defects opening to the junction of right atrium SVC. However, this technique is associated with SVC stenosis and the possible development of stenosis in the pulmonary veins in patients with high defects [3,4]. The transcaval repair technique continues to be discussed. Some authors report possible injury to the sinus node through various mechanisms and others suggest that such concerns would be unfounded when the technique was used correctly. In addition to injury to the sinus node, the necessity of a second patch for the closure of the atrium further extends the procedure [5,6]. The modifications of the Warden procedure are well-known, but are uncommonly used techniques that have remained controversial for many years. Although it was advocated that the technique avoided injury to the sinus node, the development of SVC stenosis over the long term and the need to modify the technique in cases with a long distance between the SVC stump and atrial appendix have limited the use of this technique.

In the present case, the intraoperative assessment revealed high opening of the right pulmonary veins into the SVC, and also PLSVC drained into the right atrium through the coronary sinus that had an adequate width and the communicating innominate veins were of sufficient diameter. The use of the Warden

procedure was considered to be inappropriate due to need for a conduit between the SVC stump and atrial appendix, growth potential of the patient, and the possibility of developing SVC stenosis over the long term. Instead of performing a transcaval double patch repair, dividing the SVC after opening to the left pulmonary vein to direct the blood flow to PLSVC through the innominate vein was considered to be an easy technique avoiding sinus node injury and SVC stenosis. After performing this repair, an SVC cannula was clamped, due to suspicion of right-sided venous return abnormality, and pressure monitoring was performed via central venous catheter inserted in the right internal jugular vein. The lack of increased pressure after clamping was regarded as an indication for problem-free repair in the postoperative period, and the decision was made to proceed with the operation.

This new technique reported on the current case offers a simple and safe procedure in patients with high pulmonary veins and communication through the innominate veins of a sufficient caliber that are found appropriate for the procedure after pressure measurements.

The abovementioned practical and efficient technique can also be safely applied to PLSVC cases with innominate vein connection following pressure measurement.

Competing interests

The authors declare that they have no competing interests.

References

1. Sojak V, Sagat M, Balazova E, Siman J. Outcomes after surgical repair of sinus venosus atrial septal defect in children. Bratisl Lek Listy 2008;109(5):215–9.
2. Gustafson RA, Warden HE, Murray GF. Partial anomalous pulmonary venous connection to the superior vena cava. Ann Thorac Surg 1995;60(6):614–7.
3. Nakahira A, Yagihara T, Kagisaki K, Hagino I, Ishizaka T, Koh M, et al. Partial anomalous pulmonary venous connection to the superior vena cava. Ann Thorac Surg 2006;82(3):978–82.
4. Alsoufi B, Cai S, Van Arsdell GS, Williams WG, Caldarone CA, Coles JG. Outcomes after surgical treatment of children with partial anomalous pulmonary venous connection. Ann Thorac Surg 2007;84(6):2020–6.
5. Stewart RD, Bailliard F, Kelle AM, Backer CL, Young L, Mavroudis C. Evolving surgical strategy for sinus venosus atrial septal defect: effect on sinus node function and late venous obstruction. Ann Thorac Surg 2007;84(5):1651–5.
6. Nassar M, Fouilloux V, Macé L, Kreitmann B, Metras D. Transcaval correction of partial anomalous pulmonary venous drainage into the superior vena cava. Ann Thorac Surg 2012;93(1):193-6.

How to cite this article:
Isik O, Akyuz M, Narymbetov N, Ayik MF, Atay Y. A Surgical Repair Tecnique for High Partial Abnormal Pulmonary Venous Return. J Clin Anal Med 2014;5(suppl 1): 117-9.