A Rare Case of Strangulated Meckel's Diverticulum in an Incarcerated Ventral Incisional Hernia

İnkansere Ventral Kesi Fıtığında Lokalize Nadir Bir Boğulmuş Meckel Divertikülü Olgusu

Nadir Bir Littre Fıtığı Olgusu / A Rare Case of Littre's Hernia

Murat Özgür Kılıç[1], Gürkan Değirmencioğlu[1], Önder Sürgit[1], Sibel Yenidünya[2]
[1]Department of General Surgery, [2]Department of Pathology, Turgut Özal University, Ankara, Turkey

Özet

Genel cerrahi pratiğinde en sık uygulanan cerrahi prosedürlerden biri olan kesi fıtığı veya postoperatif fıtık, çoğunlukla karın ameliyatları izleyen ilk yıllarda oluşur. İnkarserasyon veya strangülasyon bu fıtığın ciddi bir komplikasyondur ve çoğunlukla acil ameliyat gerektirir. Gastrointestinal sistemin en sık doğumsal anomalisi olan Meckel divertikülü, nadiren bir fıtık kesesi içinde bulunur ve bu sıradışı durum Littré fıtığı olarak adlandırılır. Ayrıca, bu sıradışı durumun ameliyat öncesi tanısı oldukça zordur ve hemen her zaman ameliyat sırasında keşfedilir. Literatürde az sayıda inkarsere ventral kesi fıtığında boğulmuş Meckel divertikülü vakası bildirilmiştir. Burada, barsak tıkanıklığı bulguları ile başvuran 65 yaşında bir kadındaki ventral kesi fıtığında boğulmuş Meckel divertikülünü sunuyoruz.

Anahtar Kelimeler

Kesi Fıtığı; Littre Fıtığı; Meckel Divertikülü

Abstract

Incisional or postoperative hernia, one of the most common surgical procedure in general surgery practice, mostly occurs in the first years following abdominal operations. Incarceration or strangulation is a serious complication of these hernias, and mostly requires emergent surgery. Meckel's diverticulum, the most frequent congenital anomaly of the gastrointestinal tract, is rarely found within a hernial sac and this unusual condition is called as Littre's hernia. In addition, preoperative diagnosis of this unusual condition is rather difficult and it is almost always first discovered during operation. A small number of cases of strangulated Meckel's Diverticulum in an incarcerated ventral incisional hernia have been reported in the literature. Herein, we report a strangulated Meckel's Diverticulum through a ventral incisional hernia in a 65 year-old woman who presented with clinical signs of intestinal obstruction.

Keywords

Incisional Hernia; Littre's Hernia; Meckel's Diverticulum

DOI: 10.4328/JCAM.2936 Received: 16.10.2014 Accepted: 31.10.2014 Printed: 01.02.2014 J Clin Anal Med 2014;5(suppl 1): 130-2
Corresponding Author: Murat Özgür Kılıç, Turgut Özal University, Department of General Surgery, Alparslan Türkeş Cad. No: 57 06510, Emek, Ankara, Turkey.
GSM: +905053573122 E-Mail: murat05ozgur@hotmail.com

Introduction

Incisional hernia (IH) is a well-known complication following abdominal surgery and sometimes presented with incarceration or strangulation as an emergency surgical condition. In most of the cases, omentum, small and large intestines consist the contents of hernial sac. However, very few cases of strangulated Meckel's diverticulum (MD) have been reported in the literature. MD is the most common congenital abnormality of gastrointestinal tract with an incidence of approximately 2% of general population [1]. It is a true diverticulum comprising all intestinal layers and results from the persistence of the omphalomesenteric duct which normally obliterates during early weeks of foetal development. The majority of Meckel's diverticula are usually insignificiant clinically and only 5%-16% of those become symptomatic [2]. Gastrointestinal bleeding, ulceration, perforation and intestinal obstruction are the main complications of MD. However, a ventral IH containing a strangulated MD is a rare clinical entity and can be quite difficult to diagnose preoperatively.

Case Report

A 65-year-old obese female patient presented with a painful mass at the left side of the umbilicus. The mass had been reductabl for over ten years, but it had become tense and irreducible one week earlier. She had a history of umblical hernia repair before twelve years. She had diabetes mellitus and hypertension for a long time. On physical examination, an irreducible painful mass, approximately 10 cm in size, was noted at the left corner of the previous surgical insicion due to umblical hernia repair. Abdominal X-ray demonstrated moderate nonspecific dilation of the small bowel, with no pneumoperitoneum. Ultrasonographic (US) examination revealed a mass that was thought to be originated from small bowel and an amount of fluid within the hernia sac. On addmission, inflammatory markers (WBCs: 15.2 K/ µl, CRP: 104.3 mg/l) were elevated. After sufficient resuscitation, the patient was promptly taken to the operating theatre with a diagnosis of strangulated incisional ventral hernia. At operation, a strangulated MD was seen within the hernial sac (figure 1). Segmental resection of the small intestine containing MD with followed by side to side anastomosis was performed, and the fascial defect was repaired with use of a prosthetic mesh. On histopathological evaluation, a true diverticulum was diagnosed (figure 2). The postoperative course was uneventful and the patient was discharged on day 7.

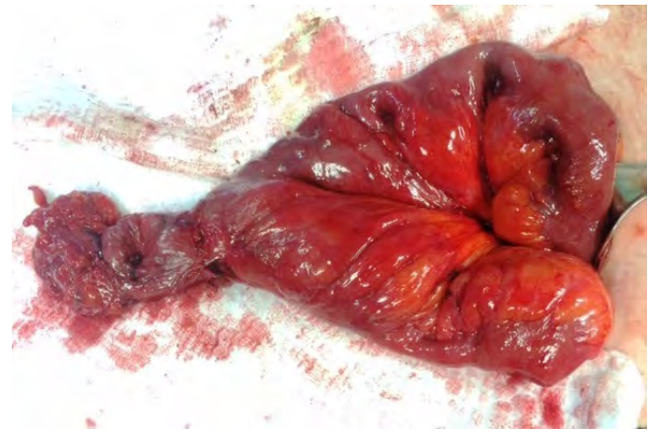

Figure 1. The appearance of incarcerated Meckel's diverticulum after removal from the hernia sac

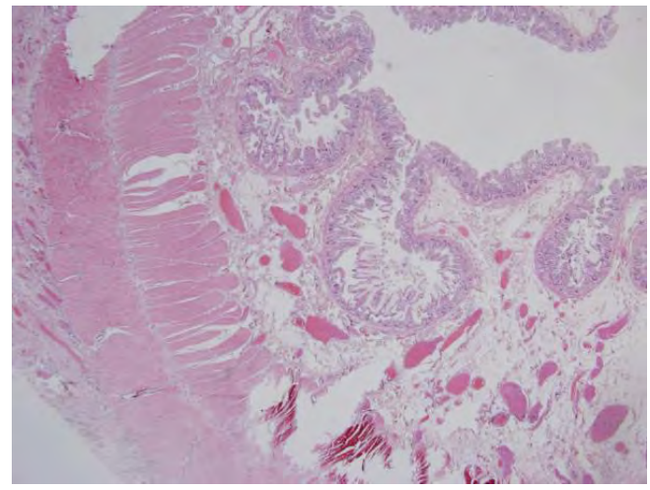

Figure 2. Mixed type of inflammatory cells including polymorphonuclear leukocytes were seen in lamina propria of the diverticulum. In addition, intense bleeding foci and inflammatory granulation tissue were observed in serosal surface (H&E×20).

Discussion

Incisional ventral hernia occurs as a complication following abdominal surgical procedures especially within the first postoperative years, with an incidence rate of approximately up to 20% of all abdominal surgeries [3]. Incarceration and strangulation are the most severe complications of IH. In a study by Ozkan et al. [4], of the emergency cases with incarceration, 14.7% had IH. In general, preperitoneal fat tissue, omentum, small and large intestines are found within the incarcerated hernia sac. MD, presenting as a strangulated ventral incisional hernia, is very uncommon, and preoperative diagnosis of this type of hernia is quite difficult. US examination usually cannot reveal this condition but computed tomography may be more helpful in diagnosis. Therefore, when a patient is presented with an incarcerated abdominal wall hernia and ultrasound is insufficient for identifing the content of the hernia, CT may provide more information to diagnose this dangerous condition. However, incarcerated IH containing MD is usually detected intraoperatively, as in our case. MD is the most common congenital abnormality of the gastrointestinal tract, represents the incomplete obliteration of the vitelline duct, and usually occurs within 100 cm proximal to the ileocaecal valve. It is a true diverticulum and usually remains asymptomatic throughout life of the general population. On the other hand, the most common presentations of symptomatic Meckel diverticula are gastrointestinal bleeding, obstruction, and diverticulitis among adult patients [2]. However, hernial strangulation of MD is an extremely rare clinical condition. The presence of a MD within an hernial orifice in the abdominal wall is known as Littre's hernia [5,6]. Although the inguinal region is the most frequent site of Littre's hernias, this entity can be rarely seen within ventral insicional defects [5,7] and may cause intestinal obstruction secondary to strangulation of the diverticulum within the hernial sac. Sometimes, MD is presented with perforation which usually accounts for 14% of all complications associated with it [8]. Although ulceration of ectopic gastric tissue is the main cause of perforation in most cases, tumours and incarceration within an abdominal

wall hernia are extremely rare cases. The treatment of asymptomatic MD is still a contraversial issue in the literature, however surgery is the mainstay of treatment for symptomatic or complicated diverticula.

In conclusion, Meckel's diverticulum, presenting as a strangulated incisional ventral hernia, is extremely rare and can be difficult to diagnose. A detailed clinical evaluation with timely operative intervention is of great importance to provide best outcomes for these patients.

Competing interests

The authors declare that they have no competing interests.

References

1. Alkan M, Guler G, Yildirim F, Doran F, Zorludemir U, Olcay I. Perforation of an Inflamed Meckel's Diverticulum in a Newborn: Report of a Case. Turk J Gastroenterol 2009;20(3):235–6.
2. Park JJ, Wolff BG, Tollefson MK, Walsh EE, Larson DR. Meckel diverticulum: the Mayo Clinic experience with 1476 patients (1950-2002). Ann Surg 2005;241(3):529-33.
3. Alaedeen DI, Lipman J, Medalie D, Rosen MJ. The single-staged approach to the surgical management of abdominal wall hernias in contaminated fields. Hernia 2007;11(1):41–5.
4. Ozkan E, Yildiz MK, Cakir T, Dulundu E, Eris C, Fersahoglu MM et al. Incarcerated abdominal wall hernia surgery: relationship between risk factors and morbidity and mortality rates (a single center emergency surgery experience). Ulus Travma Acil Cerrahi Derg 2012;18(5):389-96.
5. Citgez B, Yetkin G, Uludag M, Karakoc S, Akgun I, Ozsahin H. Littre's hernia, an incarcerated ventral incisional hernia containing a strangulated meckel diverticulum: report of a case. Surg Today 2011;41(4):576-8.
6. Aláez-Chillarón AB, Ramiro-Pérez C, Rodríguez-Velasco G, Calero-Amaro A, Latorre-Fragua R, Díez-Tabernilla M. Littré hernia: an unusual cause of intestinal obstruction. Cir Cir 2012;80(2):186-8.
7. Salemis NS. Incarceration of Meckel's diverticulum through a ventral incisional defect: a rare presentation of Littre's hernia. Hernia 2009;13(4):443-5.
8. Hager M, Maier H, Eberwein M, Klingler P, Kolbitsch C, Tiefenthaler W et al. Perforated Meckel's diverticulum presenting as a gastrointestinal stromal tumor:a case report. J Gastrointest Surg 2005;9(6):809–11.

How to cite this article:
Kılıç MÖ, Değirmencioğlu G, Sürgit Ö, Yenidünya S. A Rare Case of Strangulated Meckel's Diverticulum in an Incarcerated Ventral Incisional Hernia. J Clin Anal Med 2014;5(suppl 1): 130-2.