Amyloidosis of the Anterior Orbita: A Case Report

Ön Orbital Amiloidozis: Olgu Sunumu

Ön Orbital Amiloidozis / Amyloidosis of the Anterior Orbita

Aylin Karalezli[1], Cem Şimşek[2], Hilal Erinanç[3], Gökçen Çoban[4]
[1]Department of Ophthalmology, Konya, [2]Department of Ophthalmology, Ankara,
[3]Department of Pathology Konya, [4]Department of Radiology, Konya,
Baskent University, School of Medicine, Turkey

Özet

67 yaşında kadın hasta tek taraflı sağ üst kapağında 8 yılı aşkın süredir var olan ağrısız, fiske, nodüler, yavaş büyüyen kitle şikayetiyle kliniğimize başvurdu. Biyomikroskopik ve fundus muayenesi lezyonun kitle etkisi nedeniyle tam olarak yapılamadı. Manyetik resonance görüntülemede contrast madde verildikten sonra kitlenin etrafında belirgin yumuşak doku bulanıklığı ve yaygın kontrast artışı gözlendi. Lakrimal bez ve orbikülaris okuli kası infiltreydi. Hastaya biposi amaçlı kısmi tümor- benzeri lezyon eksizyonu yapıldı Tanı histopatolojik olarak tanımlandı. İmmunohistokimyasal incelemede dermis içinde λ-zincir-pozitifliği gözlendi. Bu bulgularla hasta primer ön orbita amiloidozisi olarak kabul edildi. Tek başına cerrahi yaklaşım erken veya geç evrede yetersiz eksizyon ve lokal nüks riski ile ilişkilidir. Radikal cerrahi eksizyon oküloplasti konusunda uzmanlaşmış merkezlerde bile göz kapağının yapısı ve fonksiyonunda bozulmalara neden olabilir.

Anahtar Kelimeler

Amiloidozis; Orbita; Pitoz

Abstract

A 67 year old woman was admitted to clinic with firm, painless, nodular, slowly growing unilateral lesion, observed for more than 8 years, in the right upper eyelid. In her ophthalmologic examination, slit lamp biomicroscopy and fundus examination could have done incompletely because of the lesions mass effect. On magnetic resonance imaging, there was prominent soft tissue haziness around the mass and diffuse prominent enhancement after contrast media administration. The lacrimal gland and orbicularis oculi muscles were infiltrated. The patient underwent partial excision of the tumour-like lesions for biopsy. The diagnosis was established on histopathology. Immunohistochemical examination revealed that marked λ -chain-positivity was present in dermis. Based on these results, the lesion was considered as primary anterior orbital amyloidosis. Surgical approach alone may often be associated with a high risk of incomplete excision and local recurrence, in the early or late postoperative period. Radical surgical excision, even in highly specialized oculoplastic centers, may cause severe impairment of both structure and function of the eyelid.

Keywords

Amyloidosis; Orbita; Pytosis

DOI: 10.4328/JCAM.2968 Received: 24.10.2014 Accepted: 23.11.2014 Printed: 01.04.2014 J Clin Anal Med 2014;5(suppl 2): 169-72
Corresponding Author: Aylin Karalezli, Başkent Uygulama ve Araştırma Hastanesi, Göz Hastalıkları, Selçuklu, 42080, Konya, Türkiye.
F.: +90 3322570637 E-Mail: akaralezli@yahoo.com

Introduction

Amyloidosis is a heterogeneous group of diseases characterized by extracellular deposition of insoluble protein fibrils, amyloid, in different organs. Amyloid is a pathologic proteinaceous substance, deposited between cells in various tissues and organs of the body in a wide variety of clinical setting. Amyloidosis may be systemic [generalized], involving several organ systems, or it may be localized, when deposits are limited to a single organ. On clinical grounds, the systemic - or generalized - pattern is sub-classified into two groups, primary amyloidosis which is associated with immunocyte dyscrasia and secondary amyloidosis, a common complication of an underlying chronic inflammatory or tissue destructive process. Although, ophthalmic presentations of Amyloidosis are not a common entity, these are generally associated with primary localized diseases. The gold standard of amyloid detection is the demonstration of apple-green birefringence on congo red staining. Localized amyloidosis has no effect on survival. Because periocular and orbital amyloidosis is rare, the definitive diagnosis may delay, which could lead to disease progression [1]. We report a case with anterior orbital amyloidosis.

Case Report

A 67 year old woman was admitted for firm, painless, nodular, slowly growing unilateral lesion of right upper eyelid. [Fig. 1]



Figure 1. Unilateral lesion of the right upper eyelid

The lesion had been observed for more than 8 years. She has not underwent any ocular examination before. Her medical history was normal. Visual acuities were 0,05 in the right eye and 0,60 in the left eye. Intraocular tension was within normal limits [TOS = 18/15 mmHg]. Slit lamp biomicroscopy and fundus examination could not have done completely because of the lesions mass effect. In the right eye, ocular motility in both adduction and abduction was limited but the eye showed orthotropia in the primary position. Computed tomography (CT) imaging demonstrated right eyelid swelling and an ill-defined isodense upper eyelid lesion. The lesion showed diffusely enhancement after contrast media administration [Fig. 2]. Magnetic resonance imaging (MRI) was performed for the best soft tissue resolution. On MRI, there was prominent soft tissue haziness around the mass and diffuse prominent enhancement after contrast media administration. The lacrimal gland and orbicularis

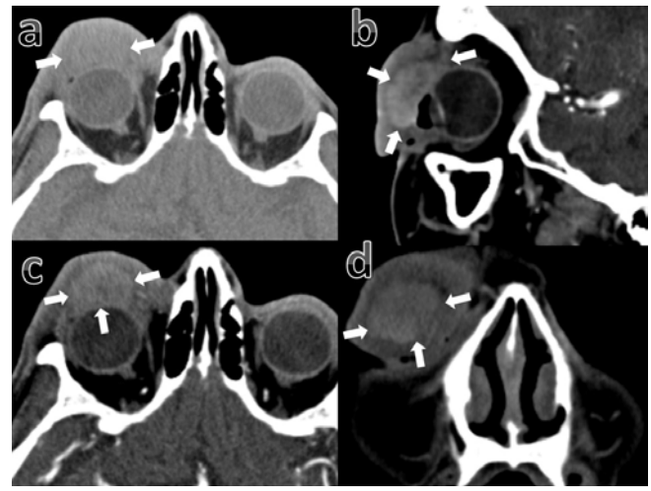

Figure 2. Computed tomography images of the upper eyelid lesion. On axial CT imaging the right eyelid swelling and an ill-defined isedense lesion is seen before contrast media administration [a]. After contrast media administration the tumor shows prominent and diffusely enhancement [white arrows] on sagittal [b], axial [c] and coronal [d] T1 weighted images.

oculi muscle were infiltrated [Fig. 3]. The patient underwent biopsy of the tumour-like lesions for histopathologic diagnosis. Evaluation by light microscopy revealed subepithelial amorphous eosinophilic deposits with Hematoxylin and eosin stained sections [Fig.4] and amyloidosis was confirmed by a positive

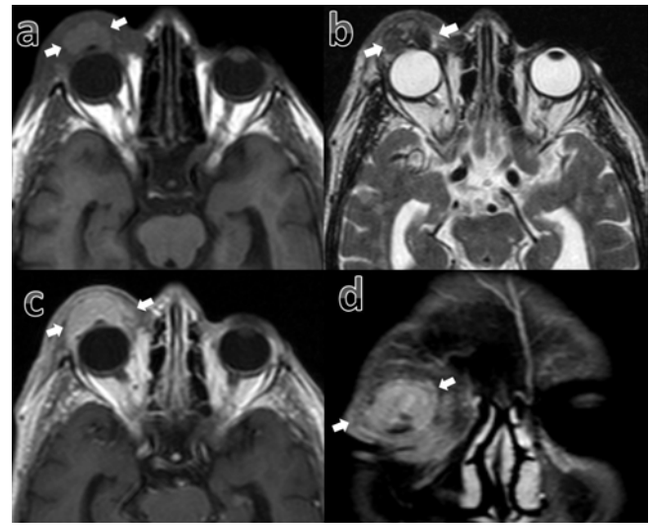

Figure 3. MR images of the the upper eyelid lesion. The tumor [white arrows] is high-intermediate signal intensity on axial T1 weighted image [a, before contrast media administration] and heterogeneous hypo-hyperintens on axial T2 weighted image [b]. There is infiltration and prominent soft tissue haziness around the mass. After contrast media administration the tumor shows prominent and diffusely enhancement [white arrows] on axial [c] and coronal [d] T1 weighted images.

Congo red staining revealing a apple-green birefringes when using with polarized light [Fig. 5]. An immunohistochemical examination revealed that marked λ -chain-positivity was present in dermis [Fig. 6]. Following the histopathologic diagnosis, the patient was investigated for systemic amyloidosis. Full blood counts, erythrocyte sedimentation rate, serum electrophoresis, urine for Bence-Jones protein, liver function studies and renal function studies were performed and the results were within normal limits. Based on these results, including histopathologic examination and laboratory tests, the lesion was considered as primary anterior orbital amyloidosis. After the histopathologic diagnosis, we recommended radiotherapy, but the patient reclaimed against the treatment.

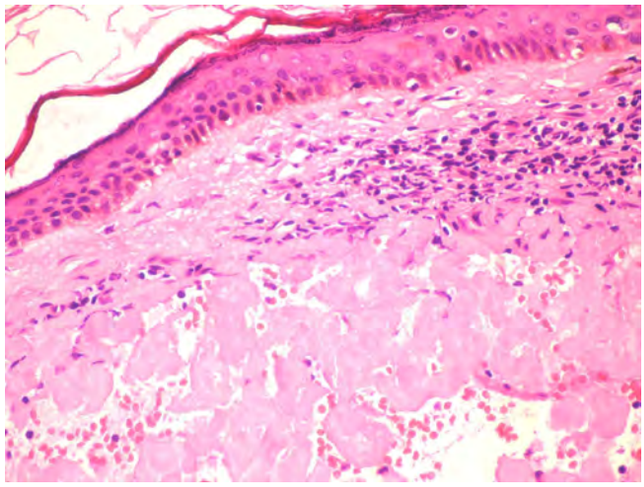

Figure 4. Histological evaluation reveals complete dermal replacement by acellular, amorphous, eosinophilic material . Hematoxylin-eosin stain; original magnifications: HEX40

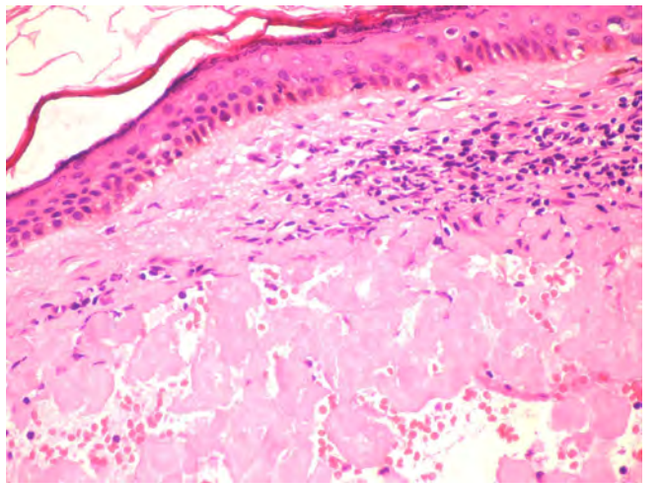

Figure 5. Birefringence in vessel walls and dermal deposition on Congo red stains viewed under polarized light.

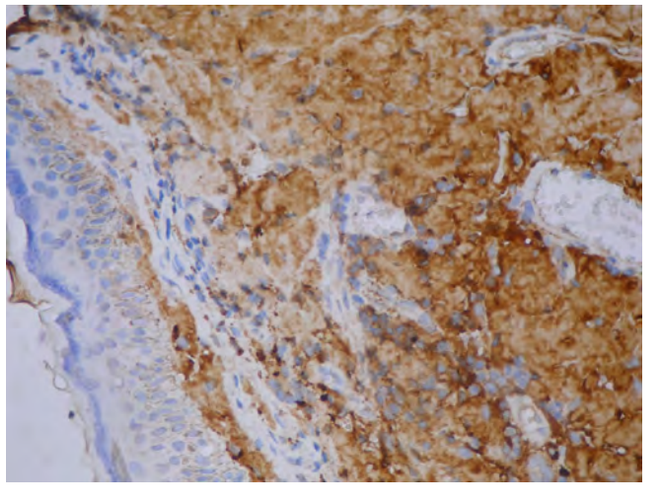

Figure 6. Immunohistochemical staining was positive for lambda light chain on amyloid. Immunohistochemical stain; original magnification: ×40.

Discussion

The clinical presentation of amyloidosis can be classified by the clinicopathological features, the disease locations and magnitude of amyloid deposits. Periocular and orbital amyloid deposition usually occur in the lacrimal gland, eyelid, conjunctiva, and ocular adnexa, and these are generally associated with primary localized diseases [2,3].

Cutaneous involvement of the eyelid is thought to be pathognomonic of primary systemic amyloidosis. Histologic evaluation is required for the diagnosis of amyloidosis. The demonstration of amyloid in and of itself is not particularly helpful to the clinician, and an accurate determination of the type of amyloid is just as important as recognizing the presence of amyloid. Primary amyloidosis is associated with systemic distribution of immunoglobulin light chain [AL] type of protein. Most of the AL proteins analyzed are composed of λ light chains or their fragments, but in some cases kappa chains have been identified. Immunhistochemical staining can determine the type of amyloidosis. Positive staining for kappa and lambda indicates AL amyloidosis [1]. In many of primary amyloidosis cases, the patient has some form of plasma cell dyscrasia. The diagnosis of AL amyloidosis also requires demonstration of a plasma cell dyscrasia. In approximately 10% of cases the disorder overlaps with overt multiple myeloma [4]. Although AL amyloidosis is a systemic disorder, that can present with variety of symptoms and almost all patients have multisystem amyloid deposition, it is not uncommon to present with evidence of single organ involvement. It is also important that AL amyloidosis should be distinguished from localized amyloidosis. All patients should be investigated to rule out systemic involvement. In contrast to systemic disease, monoclonal proteins constituting localized amyloid deposits arise from a small number of plasma cells surrounding the lesion. Monoclonal light-chain does not circulate or deposit outside the target organ.

Primary orbital amyloidosis is a rare clinical entity that often leads to misdiagnosis. Macroscopically gross differential diagnosis includes basal cell or squamous cell carcinoma, lacrimal gland carcinoma or lymphoma [5]. Radiological examinations, like tomography or ultrasound, although not diagnostic, are important to establish the relationships of the masses with the surrounding structures before surgery. They are useful for the correct therapeutical approach and to exclude a possible systemic involvement of the disease.

Some treatment modalities like medical treatment, surgical debulking, radiotherapy and observation have been proposed for localized amyloidosis. Although the recurrences have been reported surgery is thought to be gold standard of management which should be as conservative as possible. The surgical approach is based on the resection of the affected structures, or it might be more complex including different reconstructive procedures in cases of greater extent of lesions. Radiotherapy may be useful for reducing the size of the tumourous mass before surgery [6]. In localized form of amyloidosis, amyloid infiltration of blood vessels may contribute to the bleeding diathesis. The medical treatment is based on the use of ascorbic acid to reduce the bleeding tendency of these lesions and anti- inflammatory drugs, locally or systemically. Other therapeutic options are electro- cauterization, cryotherapy, and selective debridement. In our case, we recommended radiotherapy after the biopsy, but the patient reclaimed against the treatment.

Before the operation, general clinical examination and ophthalmologic tests are also indicated to choose a correct therapeutic strategy. In fact, a surgical approach alone may often be associated with a high risk of incomplete excision and local recurrence, in the early or late postoperative period. Radical surgical

excision, even in highly specialized oculoplastic centers, may cause severe impairment of both structure and function of the eyelid. For these reasons, other methods such as electro cauterization, cryotherapy, selective curettage and radiotherapy have already been described in addition to surgery as useful tools to remove amyloid vegetations [7].

In conclusion the present case, localized form of amyloidosis of the anterior orbita,is an uncommon condition, of which presentation may be unusual and diagnosis may be delayed.

Competing interests

The authors declare that they have no competing interests.

References

1. Picken MM. Amyloidosis-where are we now and where are we heading? Arch Pathol Lab Med 2010;134(4):545–51.
2. Ramsey MS, Fine BS, Cohen SW. Localized corneal amyloidosis: case report with electron microscopic observations. Am J Ophthalmol 1972;73(4):560-5.
3. Bozkurt B, Kiratli H, Soylemezoglu F, Irkec M. In vivo confocal microscopy in a patient with conjunctival amyloidosis. Clin Experiment Ophthalmol 2008;36(2):173-5.
4. Gertz MA. The Classification and Typing of Amyloid Deposits. Am J Clin Pathol 2004;121(6):787-9.
5. Spitellie PH, Jordan DR, Gooi P, Brownstein S, Burns BF. Primary localized conjunctival amyloidosis simulating a lymphoproliferative disorder. Ophthal Plast Reconstr Surg 2008;24(5):417-9.
6. Pecora JL, Sambursky JS, Vargha Z. Radiation therapy in amyloidosis of the eyelid and conjunctiva: a case report. Ann Ophthalmol 1982;14(2):194-6.
7. Demirci H, Shields CL, Eagle RC Jr, Shields JA. Conjunctival amyloidosis: report of six cases and review of the literature. Surv Ophthalmol 2006;51(4):419-33.

How to cite this article:
Karalezli A, Şimşek C, Erinanç H, Çoban G. Amyloidosis of the Anterior Orbita: A Case Report. J Clin Anal Med 2014;5(suppl 2): 169-72.