Orjinal Görüntü
JCAM
Original Image

# Bilateral Multiple Giant Juvenile Fibroadenomas

## Bilateral Multipl Dev Juvenile Firoadenomalar

Dev Juvenile Fibroadenom / Juvenile Giant Fibroadenoma

Metin Altınkaya[1], Naime Altınkaya[2], Halil İbrahim İnal[3]
[1]Department of General Surgery, Çukurova Dr. Aşkım Tüfekçi State Hospital, [2]Department of Radiology, Baskent University Medical School,
[3]Department of Plastic and Reconstructive Surgery, Çukurova Dr. Aşkım Tüfekçi State Hospital, Adana, Turkey

A 14 year-old girl presented to our breast center with bilateral rapidly enlarging breast lumps that had developed over the 3 months prior (Fig. 1). She was otherwise healthy and had no history of trauma, nipple discharge, fever, fatigue, or weight loss. There was no evidence of risk factors for breast malignancy. Upon physical examination, both the left and right breasts were enlarged and multiple palpable masses were evident. The masses were mobile, slightly tender, and well-defined. No skin ulceration was apparent and no lymph node enlargement was detected in the axillary regions.

Ultrasonography of both breasts revealed multiple, well-circumscribed, homogenous hypoechoic masses (Fig. 2). Breast MRI showed bilateral T1-weighted hypointensity, T2-weighted hyperintensity, and well-circumscribed multiple masses. T1-weighted imaging after intravenous administration of gadolinium contrast material revealed diffuse intense enhancement of the tumors (Fig. 3).

Multiple ultrasound-guided core biopsies revealed benign proliferative breast lesions. The patient was treated using the inverted "T" technique for excision of the bilateral breast lumps. The right-sided lump measured 23×16×12 cm and weighed 1,920 g. The left-sided lump measured 23×14×9 cm and weighed 1,525 g (Fig. 4a-b). Postoperatively, the patient recovered well, and returned to our clinic 2 months later showing good cosmetic results (Fig. 5).

Fibroadenomas >5 cm in diameter or exceeding 500 g in weight are commonly classified as giant fibroadenomas. When such enlarged masses are found in young females (in their teens or early 20s), they are often termed giant juvenile fibroadenomas, which are rare clinical entities. Giant fibroadenomas constitute 4% of all fibroadenomas, and giant juvenile fibroadenomas only 0.5%. Bilateral giant juvenile fibroadenomas are extremely rare. Patients with juvenile fibroadenomas typically present with rapidly enlarging breasts. Skin ulceration, or prominent, distended superficial veins, may also be noted.

Mammograms are generally not helpful and are not recommended for patients of this age group. Sonographically, a fibroadenoma appears as a well-circumscribed, round, oval or macrolobulated mass of fairly uniform hypoechogenicity. Fibroadenomas vary in appearance upon MR imaging. In terms of overlapping features, fibroadenomas cannot be differentiated from phyllodes tumors by imaging alone.

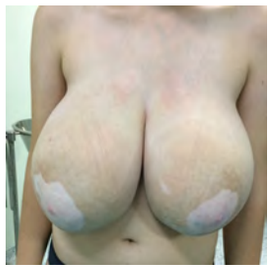

Fig.1. Preoperative gross appearance of the bilateral breast tumors.

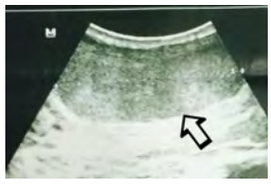

Fig. 2. Ultrasonography reveals well-circumscribed, homogenous hypoechoic masses.

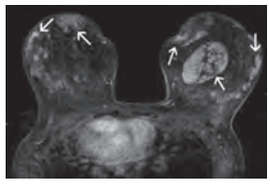

Fig. 3. On breast MRI, a bilateral axial T1-weighted image taken after intravenous administration of gadolinium contrast material reveals diffuse intense enhancement of the tumors.

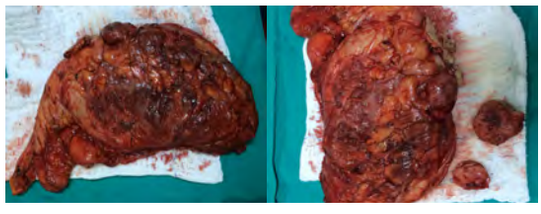

Fig. 4. Gross appearance of the bilateral lumpectomy specimens (A,B).



Fig. 5. A postoperative photograph of the patient showing that tumor resection had preserved the breasts; an excellent cosmetic outcome is apparent.

DOI: 10.4328/JCAM.3647 Received: 02.06.2015 Accepted: 13.06.2015 Printed: 01.04.2014
Corresponding Author: Metin Altınkaya, Çukurova Dr. Aşkım Tüfekçi Devlet Hastanesi, Yeni Baraj Mah. Hacı Ömer Sabancı Cad. Seyhan, Adana, Turkey.
T.: +90 3222259329/2105 F.: +90 3222253758 E-Mail: altinkayametin@hotmail.com