Anomalous Separate Origination of All Three Coronary Arteries From Right Sinus of Valsalva

Sağ Sinüs Valsalva'dan Ayrı Ayrı Orijin Alan Üç Koroner Arter Anomalisi

Koroner Arter Anomalileri ve Angina / Coronary Artery Anomalies and Angina

Akif Serhat Balcıoğlu[1], Davran Çiçek[1], Murtaza Emre Durakoğlugil[2], Uğur Abbas Bal[3], Haldun Müderrisoğlu[3]
[1]Başkent Üniversitesi Alanya Uygulama ve Araştırma Merkezi, Kardiyoloji Anabilim Dalı, Antalya,
[2]Recep Tayyip Erdoğan Üniversitesi Tıp Fakültesi, Kardiyoloji Anabilim Dalı, Rize,
[3]Başkent Üniversitesi Tıp Fakültesi, Kardiyoloji Anabilim Dalı, Ankara, Türkiye

Özet

Koroner arter anomalilerinin bir alt grubu olan sol koroner arterin karşı sinüsten orijin alma anomalisi özellikle gençlerde egzersiz sırasındaki ani ölümlerin önemli nedenlerinden biridir. Bu anomalinin en ciddi bulgusu ani ölüm olmasına rağmen, nefes darlığı, çarpıntı, angina pectoris ve senkop gibi semptomlar erişkinlerde daha sık görülür. Koroner angiografi ile tanı konulduğunda, anomalili koroner arterlerin büyük damarlarla olan ilişkisini (interarterial-malign seyir) belirlemek için diğer görüntüleme yöntemleri kullanılmalıdır. Tedavide medikal tedavi ile takip, perkütan koroner girişim ve cerrahi onarım seçenekleri vardır. Biz bu yazıda, kan basıncı regülasyonunun bozulmasıyla başlayan efor anginası olan bir hastada, sağ sinüs valsalvadan ayrı ayrı orijin alan üç koroner arter anomalisini sunuyoruz.

Anahtar Kelimeler

Angina Pektoris; Koroner Angiografi; Koroner Arter Anomalisi

Abstract

As a subgroup of coronary artery anomalies, anomalous origination of left coronary artery from the opposite sinus (left-ACAOS) is an important cause of sudden death during exertion, especially in young people. Although sudden death is the gravest manifestation of left-ACAOS, dyspnea, palpitation, angina pectoris and syncope are more frequently seen in older adults. When diagnosed with coronary angiography, other imaging modalites should be used to identify for the relationship of anomalous vessels with great arteries (interarterial-malign course). The treatment options of left-ACAOS include medical therapy with close follow up, percutaneous coronary intervention and surgical repair. Hereby, we present a case with anomalous separate origination of all three coronary arteries from right sinus of Valsalva and exertion-induced angina following dysregulation of hypertension.

Keywords

Angina Pectoris; Coronary Angiography; Coronary Artery Anomaly

DOI: 10.4328/JCAM.2243 Received: 21.12.2013 Accepted: 04.01.2014 Printed: 01.06.2014 J Clin Anal Med 2014;5(suppl 3): 309-11
Corresponding Author: Akif Serhat Balcıoğlu, Başkent Üniversitesi Alanya Uygulama ve Araştırma Merkezi, Kardiyoloji Anabilim Dalı, 07400, Alanya, Antalya, Türkiye.
T.: +90 2425102525 F.: +90 2425115563 E-Mail: serhatbalcioglu@gmail.com

Introduction

CAAs have been associated with chest pain, sudden death, cardiomyopathy, syncope, dyspnea, ventricular fibrillation and myocardial infarction. Several types of CAAs have been defined and the incidence ranges from 1 to 5% [1, 2]. Simply, CAAs can be classified as anomalies of origination and course, anomalies of intrinsic coronary arterial anatomy, anomalies of coronary termination, and anomalous anastomotic vessels [2]. The most frequent anomaly is the split right coronary artery [2]. Anomalous origination of a coronary artery from the opposite sinus (ACAOS) has the most potentially severe prognosis [3]. The clinical manifestation of CAAs ranges from asymptomatic status to angina, acute myocardial infarction, ventricular arrhythmias with syncope, and sudden cardiac death according to course of the abnormal vessels and complexity of the anomaly. Hereby, we present a case with exertion-induced angina and positive exercise stress test due to ACAOS.

Case Report

A 42-year-old woman without previous heart disease was admitted to our outpatient clinic with the complaint of exertional dyspnea and atypical angina, which were present for a few months. She had a history of hypertension, without additional risk factors including diabetes mellitus, hyperlipidemia, smoking, and family history of premature coronary artery disease. The patient complained of uncontrolled hypertension despite taking anti-hypertensive medication. Admission electrocardiogram did not reveal any ST-T deviations. Echocardiographic examination demonstrated mild left ventricular hypertrophy and stage I diastolic dysfunction. Due to presence of 1 to 2 mm ST segment depressions with concomitant chest pain, exercise stress test was decided as positive for obstructive coronary artery disease.

Coronary angiography revealed anomalous origin of both left anterior descending (LAD) and left circumflex (LCX) arteries from the right sinus of Valsalva via separate ostia without a left main coronary artery. The right coronary artery (RCA) was dominant and also originated from right sinus of Valsalva (Figure 1). Multi-slice computed tomography showed that LAD, LCX and right coronary arteries originated from 3 separate ostia (Figure 2). While LAD travelled through anterior aspect of aorta and pulmonary artery (Figure 3), LCX had a course between posterior side of aorta and anterior side of pulmonary veins (Figure 4). No occlusive atherosclerotic coronary artery disease was present.

By revising patient's antihypertensive treatment, her blood pressure fell into the normal range and chest pain complaint disappeared.

Discussion

Coronary artery anomalies (CAAs) have been associated with chest pain, sudden death, cardiomyopathy, syncope, dyspnea,

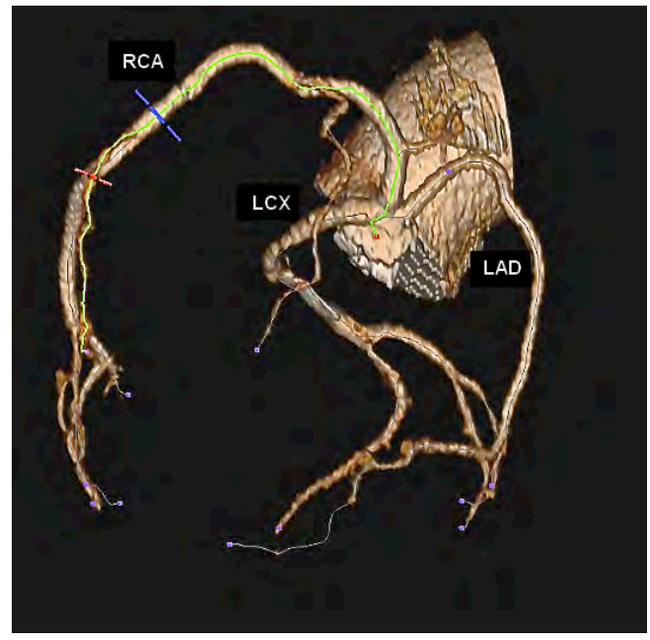

Figure 2. Three-dimensional CT angiographic image of left anterior descending (LAD), left circumflex (LCX) and right coronary arteries (RCA)

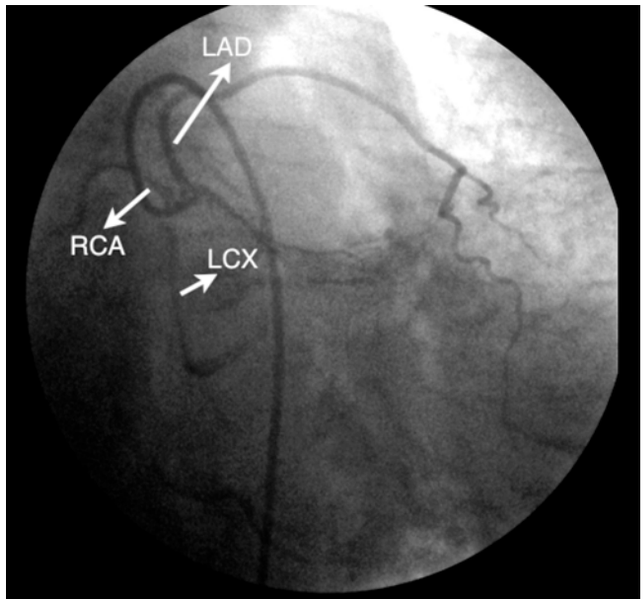

Figure 1. Coronary angiographic image of left anterior descending (LAD), left circumflex (LCX) and right coronary arteries (RCA) in caudal view.

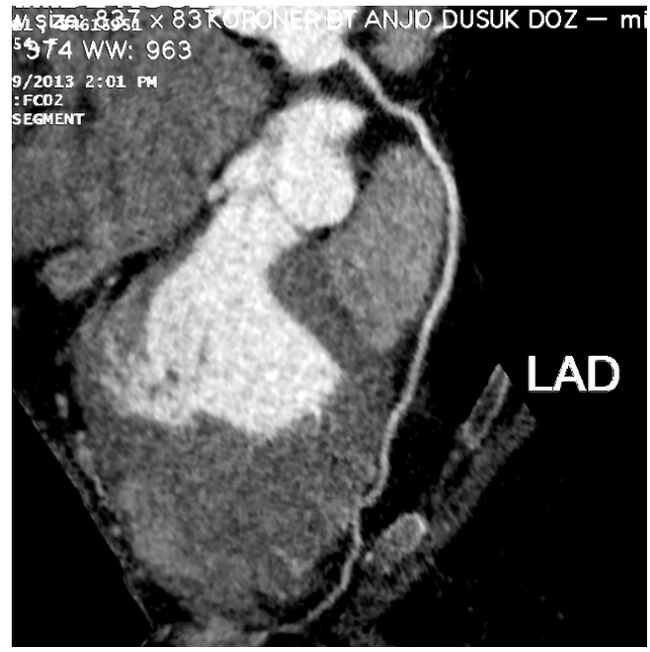

Figure 3. Multi-planar reformatted multi-slice CT image of left anterior descending (LAD) artery

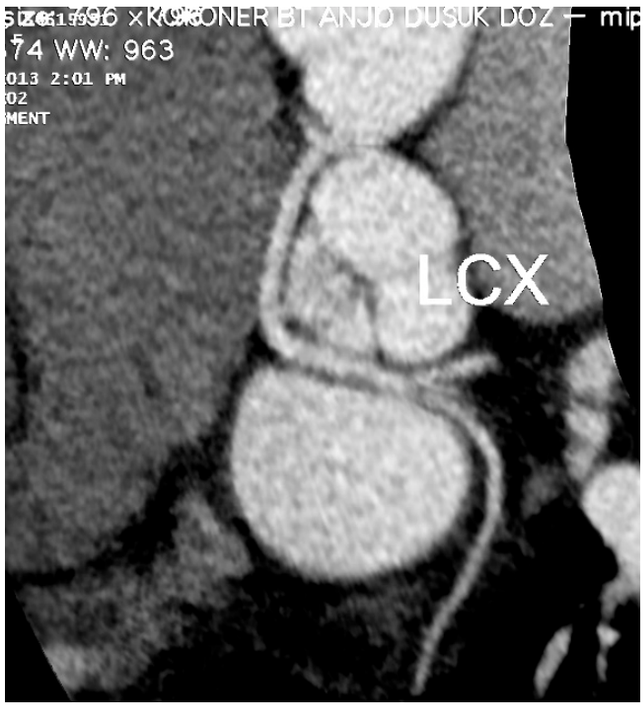

Figure 4. Multi-slice CT image of left circumflex artery (LCX)

ventricular fibrillation and myocardial infarction[4, 5]. Incidence of these wide variety of anomalies were reported as about 1-5% in angiographic series and 0.3% in autopsy series [1, 2]. Most of the CAAs (approximately 81%) [1] are anatomic variants and have a favorable prognosis, remaining anomalies may cause severe symptoms and cardiac death[4].

As a subgroup of CAAs, anomalous origination of a coronary artery from the opposite sinus (ACAOS) has the highest risk for adverse events. In a series of 6.3 million 18 year-old recruits who underwent intense military training, 64 cardiac deaths were observed. According to clinical and necropsy findings, 21 (33%) deaths were related to ACAOS. Interestingly, all of the cases had left coronary artery involvement (left-ACAOS), and other CAAs did not result in cardiac death [6]. Severe adverse events like myocardial infarction and sudden cardiac death are associated with interarterial course of any coronary artery between aortic root and right ventricular outflow tract (malignant form). Incidences of anomalous origination of the RCA from the left sinus and left coronary artery from the right sinus of Valsalva were reported as 0.92% and 0.15%, respectively (a total incidence of 1.07% for ACAOS) [4]. Angelini et al described the following pathologies in the proximal segment of left coronary artery using intravascular ultrasound in cases with left-ACAOS: 1) an intramural course inside the aortic wall, 2) hypoplasia, as determined by its circumference, 3) a cross-sectional ovoid deformity (lateral compression) with phasic and exercise induced worsening of the deformity [7]. Exercise or hypertension causes expansion of great vessels that leads to compression of coronary vessel, and may also increase the angulation of the coronary artery that decreases the luminal diameter in the proximal portion of coronary artery because of stretching. Moreover, although sudden death is the gravest manifestation of ACAOS, dyspnea, palpitation, angina pectoris and syncope are more frequently observed [2]. Sudden cardiac death is usually linked with extreme exercise in young adults whereas the other symptoms are frequently perceived in older adults especially women, which may be related to new-onset or uncontrolled hypertension [2], such as our case.

Resting electrocardiograms are usually normal and stress tests may not be always positive. Coronary angiography is the gold standard for diagnosis. Multi-slice computed tomography, cardiac magnetic resonance, and transesophageal echocardiography are complementary methods for detecting the relationship of anomalous vessels with great arteries and other cardiac structures.

The treatment options of ACAOS include medical therapy with close follow up, percutaneous coronary intervention (PCI) and surgical repair[7, 8]. There are 2 interventional surgical approaches can be used for left-ACAOS: first one is local, direct repair of the anomalous origination in the aortic root and the second is coronary artery bypass surgery [7]. Percutaneous coronary intervention is technically difficult and challenging[9].

Conclusions

Anomalous origin of coronary arteries is uncommon and all three coronary arteries arising from right sinus of Valsalva is very rare. This anomaly can even cause sudden cardiac death in young individuals, if there is an interarterial course of any coronary artery. The other manifestations of ACAOS are more frequently seen in older adults. Coronary angiography should be complemented with other imaging modalities. When diagnosed, immediate therapy should be personalized case by case to prevent fatal outcome.

Competing interests

The authors declare that they have no competing interests.

References

1. Yamanaka O, Hobbs RE. Coronary artery anomalies in 126,595 patients undergoing coronary arteriography. Cathet Cardiovasc Diagn 1990;21(1):28-40.
2. Angelini P. Coronary artery anomalies: an entity in search of an identity. Circulation 2007;115(10):1296-305.
3. Frescura C, Basso C, Thiene G, Corrado D, Pennelli T, Angelini A, et al. Anomalous origin of coronary arteries and risk of sudden death: a study based on an autopsy population of congenital heart disease. Hum Pathol 1998;29(7):689-95.
4. Angelini P, Villason S, Chan AV, Diez JG. Normal and anomalous coronary arteries in humans. In: Angelini P, editor. Coronary Artery Anomalies: A Comprehensive Approach. Philadelphia: Lippincott Williams & Wilkins; 1999. p. 27-150.
5. Bugan B, Celik T. Causes of acute coronary syndrome in young adults. J Clin Anal Med 2014;5(1):80-4.
6. Eckart RE, Scoville SL, Campbell CL, Shry EA, Stajduhar KC, Potter RN, et al. Sudden death in young adults: a 25-year review of autopsies in military recruits. Ann Intern Med 2004;141(11):829-34.
7. Angelini P, Walmsley RP, Libreros A, Ott DA. Symptomatic anomalous origination of the left coronary artery from the opposite sinus of valsalva. Clinical presentations, diagnosis, and surgical repair. Tex Heart Inst J 2006;33(2):171-9.
8. Surucu H, Tatli E, Degirmenci A, Kurtoglu N. Anomalous origin of coronary arteries from three separate ostiums in the right sinus of Valsalva: three case reports and review of the literature. Int J Cardiol 2006;106(2):264-7.
9. Panduranga P, Riyami A. Separate origin of major coronary arteries from the right sinus with angioplasty and stenting of anomalous left circumflex and left anterior descending arteries. J Invasive Cardiol 2009;21(2):E33-6.

How to cite this article:
Balcıoğlu AS, Çiçek D, Durakoğlugil ME, Bal UA, Müderrisoğlu H. Anomalous Separate Origination of All Three Coronary Arteries From Right Sinus of Valsalva. J Clin Anal Med 2014;5(suppl 3): 309-11.