A Case of Pediatric Henoch-Schönlein Purpura with Severe Melena Treated by Plasmapheresis

Ağır Melenası Plazmaferez ile Tedavi Edilen Henoch-Schönlein Purpuralı Çocuk Olgu

Plazmaferez ile Tedavi Edilen Henoch-Schönlein Purpuralı Çocuk / Pediatric Henoch-Schönlein Purpura Treated by Plasmapheresis

Tugba Koca[1], Nagehan Aslan[2], Selim Derecı[1], Ayca Esra Kuybulu[3], Mustafa Akcam[1]
[1]Division of Pediatric Gastroenterology, Hepatology and Nutrition, [2]Department of Pediatrics, [3]Division of Pediatric Nephrology, Department of Pediatrics, Süleyman Demirel University School of Medicine, Isparta, Turkey

Özet

Henoch-Schönlein purpurası genellikle kendini sınırlayan iyi seyirli bir hastalıktır. Hastaların büyük çoğunluğunda tedaviye gerek olmamakla birlikte steroidler ve immunsupresif ilaçlar sistemik tutulumu olan olguların tedavisinde ilk seçenektir. Dirençli olguların tedavisinde bu ilaçlar da etkili olmayabilir. Ciddi olgularda plazmaferez alternatif bir tedavi seçeneği olabilir. Literatürde çocukluk çağında gastrointestinal tutulum nedeniyle plazmaferez ile tedavi edilen vaka oldukça nadirdir. Burada şiddetli melenanın da dahil olduğu ciddi belirtilerle başvuran, steroid ile siklofosfamid tedavisine cevap vermeyen ve plazmaferez ile tedavi edilen dokuz yaşında erkek olgu sunuldu. Gastrointestinal sistem tutulumu Henoch-Schönlein purpurasında yaygındır, ancak hayatı tehdit eden gastrointestinal kanama çok nadirdir. Henoch-Schönlein purpurasının akut dönem morbiditesi çoğunlukla gastrointestinal tutulum ile ilişkilidir ve plazmaferezin bu durumda iyi bir tedavi seçeneği olduğu göz önünde bulundurulmalıdır.

Anahtar Kelimeler

Çocukluk Çağı; Gastrointestinal Tutulum; Henoch-Schönlein Purpurası; Plazmaferez

Abstract

Henoch–Schönlein purpura nature is usually benign. The majority of patients improve spontaneously. In cases with systemic involvement, steroids and immunosuppressive drugs are the first choice, although these drugs may not be efficient in some patients with a resistant or severe course. Plasmapheresis may be an alternative treatment choice in critical cases. In childhood, cases treated with plasmapheresis because of gastrointestinal involvement are very rare in literature. The case is here presented of a 9-year old boy with serious manifestations including severe melena, who did not respond to steroid and cyclophosphamide, but was successfully treated with plasmapheresis. Gastrointestinal tract involvement is common in Henoch–Schönlein purpura but life-threatening gastrointestinal bleeding is very rare. The acute phase morbidity of Henoch–Schönlein purpura is mostly associated with gastrointestinal involvement and plasmapheresis should be considered as a good option in the treatment steps in this situation.

Keywords

Childhood; Gastrointestinal Involvement; Henoch–Schönlein Purpura; Plasmapheresis

DOI: 10.4328/JCAM.3128 Received: 03.12.2014 Accepted: 11.02.2015 Printed: 01.06.2014 J Clin Anal Med 2014;5(suppl 3): 382-4
Corresponding Author: Tugba Koca, Department of Pediatrics, Süleyman Demirel University School of Medicine, Çünür, Isparta, Turkey.
T: +90 2462119303 F.: +90 2462112830 E-Mail: tgkoca@gmail.com

Introduction

Henoch–Schönlein purpura (HSP) is the most common systemic vasculitis of childhood and usually affects children between the ages of 2 and 10 years old. HSP generally involves the skin, gastrointestinal tract, joints, kidneys and is rarely seen in other systems. Gastrointestinal involvement is common but diffuse massive hemorrhage is extremely rare. The nature of HSP is usually benign but atypical clinical presentation can be observed. Most patients do not need any treatment, but in selected cases, steroids and immunosuppressive drugs are the first choice. However, these drugs may not be efficient in some patients with a resistant and severe course. Therefore, plasmapheresis may be an alternative choice in critical cases. There have been a number of reports on plasmapheresis for severe renal involvement of HSP in childhood and more frequently in adult patients [1]. To the best of our knowledge, there is only one case report in literature of a pediatric case of plasmapheresis for gastrointestinal involvement, which was a 13-year old girl [2]. The case is here presented of a 9-year old boy with serious manifestations including severe melena, who was unresponsive to steroid and cyclophosphamide, but was successfully treated with plasmapheresis.

Case Report

A 9-year old boy was admitted with palpable purpura, limitation of motion in both ankles, abdominal pain, and edema on the scalp and leg in the last four days. A mild fever and cough had been ongoing for 5 days before admission. Physical examination revealed palpable purpura on the lower extremities, buttocks, the front of the trunk, back, arms, face, moderate oedema in the lower extremities, swelling of the face, lips, eyelids and scalp (Fig. 1), and tenderness and defense in the abdomen.



Figure 1. Palpable purpura and swelling at the face, lips, eyelids and scalp

The leukocyte count was 14.900/mm^3, hemoglobin 16 gr/dL, platelet count 492.000/mm^3, and ESR: 10 mm/h. The prothrombin time, activated prothrombin time, serum electrolytes, C3, C4, IgA and urinalysis values were normal. Urinary protein excretion was 14 mg/m2/h, and fecal occult blood was positive. The findings of abdominal ultrasonography were normal. Treatment of methylprednisolone (2 mg/kg/day) was started but during follow-up of the patient, massive gastrointestinal bleeding developed, purpura fulminans-like rashes occurred (Fig. 2) and

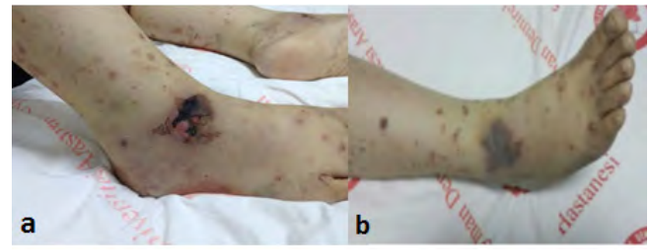

Figure 2. Necrotic rashes and edema in lower extremities (a and b)

coagulation parameters were exceeded. Oral feeding was discontinued and pulse steroid treatment was applied on alternate days. During this process, tests were performed for the etiology of vasculitis. ANA (-), p-ANCA (-), c-ANCA (-), cryoglobulin (-), anti-ds-DNA, Factor XIII, anti-thrombin-3, protein-C and Protein-S were normal. The serology of viral hepatitis (A, B and C), Cytomegalovirus, and Parvovirus B19 were negative. Anti VCA Ig M of Epstein-Barr virus was positive. Skin biopsy was consistent with leukocytoclastic vasculitis (Fig. 3a).

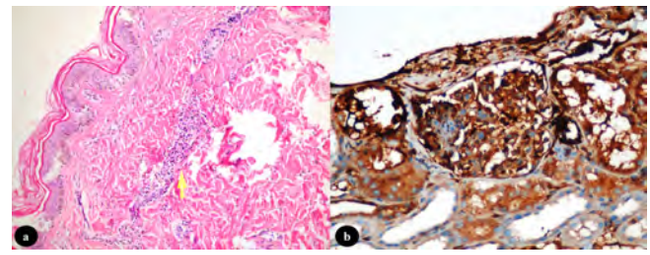

Figure 3. Histopathological examination of the skin and kidney biopsy. Leukocytoclastic vasculitis in the skin biopsy (yellow arrow) (HE, x400) (a). Positive immunreactivity for IgA in the glomerulus and adjacent tubules (Ig A, x400) (b).

A renal biopsy revealed deposition of IgA in the mesengium (Fig. 3b). When three dose pulse steroid therapy did not achieve the expected improvement in clinical and laboratory findings, 500 mg/m^2 cyclophosphamide treatment was applied. Despite this treatment with steroids and cyclophosphamide, no beneficial effect was seen and severe gastrointestinal bleeding continued. As the hemoglobin level was falling, erythrocyte transfusion was performed. Then, on the 9th day, plasmapheresis was initiated to be applied twice a week. The cutaneous lesions resolved after the first session of plasmapheresis, and the gastrointestinal bleeding was ameliorated thereafter. After 5 sessions of plasmapheresis, complete clinical recovery was obtained. Cyclosporine was given for long term remission and the patient was discharged. At 4 months after discharge, he had no complaints, and the physical examination and laboratory findings were all within the normal range.

Discussion

HSP is a childhood disorder of vasculitis of systemic small vessels of unknown etiology, which is, usually followed by an upper respiratory tract infection. Vaccination, certain foods, infec-

tions, and insect bites are thought to be important etiological factors [3]. Immunoglobulin A seems to play a central role in the pathogenesis of this disease. Diagnosis of HSP depends on history and clinical findings but in some cases, skin or renal biopsy is required. There is no specific laboratory test for diagnosis. Skin biopsy can show leukocytoclastic vasculitis, sometimes with necrosis of small blood vessels and immunostaining may reveal deposition of IgA in the walls of involved blood vessels. The histological findings of renal biopsy are diverse and may range from proliferative glomerulonephritis to glomerulosclerosis. The prognosis is generally benign, but patients with severe renal and gastrointestinal involvement need to be treated attentively and with long-term monitoring. Renal involvement in HSP is associated with a long-term prognosis but gastrointestinal involvement affects morbidity and mortality in the acute period [4]. The most serious complications in the early period are associated with gastrointestinal involvement but in the late period, the most serious complication is end stage renal failure, which is seen at rates of less than 1%. Gastrointestinal involvement usually begins with abdominal pain in patients with HSP. Vomiting, diarrhea and bloody stools can be seen. Gastrointestinal bleeding is observed in about half of patients, but the frequency of massive bleeding is 2%. In approximately 5% of these cases, as in the case presented here, severe gastrointestinal complications can be seen as fresh bloody stools and melena. A sudden increase in abdominal pain should be considered an indication of some complications such as intussusception, bowel infarction, and perforation. Intussusception may be seen in 2% of patients [5]. Particularly in HSP patients with severe gastrointestinal symptoms, an associated decrease of plasma factor XIII has been observed. Some reports have described the role of decreased factor XIII in the bleeding tendency of HSP and the therapeutic benefit of factor XIII concentrate [6]. Measuring factor XIII activity helps to identify those patients with severe gastrointestinal manifestation who may benefit from substitution therapy. In the current case, the factor XIII level was in normal range.

EBV has been reported to precede HSP [7]. Anti VCA IgM of EBV was positive in the current case, and was thought to have a possible role in the etiology. There is no specific treatment for HSP, and there is no clear evidence that treatment may change the natural history of disease. In life-threatening situations, methylprednisolone pulse therapy, immunosuppressive drugs, plasmapheresis, leukocytapheresis therapy have been reported [8]. Plasmapheresis in combination with immunosuppression should be considered as a therapeutic option in rapidly progressive life-threatening HSP.

In conclusion, to the best of our knowledge, this report is the second publication of a case in the pediatric age group, and is the youngest child with steroid-cyclophosphamide resistant HSP with severe gastrointestinal bleeding, who was successfully treated with plasmapheresis. Gastrointestinal tract involvement is common in HSP but life-threatening gastrointestinal bleeding is very rare. Acute phase morbidity of HSP is mostly associated with gastrointestinal involvement and plasmapheresis should be considered as a good option in the treatment steps in this situation.

Competing interests

The authors declare that they have no competing interests.

References

1. Kawasaki Y, Suzuki J, Murai M, Takahashi A, Iome M, Nozawa R, et al. Plasmapheresis theraphy for rapidly progressive Henoch-Schönlein nephritis. Pediatr Nephrol 2004;19(8): 920-3.
2. Acar B, Arikan FI, Alioglu B, Oner N, Dallar Y. Successful treatment of gastrointestinal involvement in Henoch-Schönlein purpura with plasmapheresis. Pediatr Nephrol 2008;23(11):2103.
3. Peru H. Soylemezoglu O, Bakkaloğlu S A. Elmas S, Bozkaya D, Elmaci AM, et al. Henoch Schonlein purpura in childhood: clinical analysis of 254 cases over a 3-year period. Clin Rheumatol 2008;27(9):1087-92.
4. Mir S, Yavascan O, Mutlubas F, Yeniay B, Sonmez F. Clinical outcome in children with Henoch-Schonlein nephritis. Pediatr Nephrol 2007;22(1):64-70.
5. Trapani S, Micheli A, Grisolia F, Resti M, Chiappini E, Falcini F, et al. Henoch Schonlein purpura in childhood: epidemiological and clinical analysis of 150 cases over a 5-year period and review of literature. Semin Arthritis Rheum 2005;35(3):135-7.
6. Kawasaki K, Komura H, Nakahara Y, Shiraishi M, Higashida M, Ouchi K. Factor XIII in Henoch-Schonlein purpura with isolated gastrointestinal symptoms. Pediatr Int 2006;48(4):413-5.
7. Islek I, Kalayci AG, Gok F, Muslu A, Dilber C. Henoch-Schonlein purpura associated with hepatitis A infection. Pediatr Int 2003;45(1):114-6.
8. Niaudet P, Habib R. Methylprednisolone pulse therapy in the treatment of severe forms of Henoch-Schonlein purpura nephritis. Pediatr Nephrol 1998;12(3):238-43.

How to cite this article:
Koca T, Aslan N, Derecı S, Kuybulu AE, Akcam M. A Case of Pediatric Henoch-Schönlein Purpura with Severe Melena Treated by Plasmapheresis. J Clin Anal Med 2014;5(suppl 3): 382-4.