Glioblastoma Multiforme Presenting as Spontaneous Intracerebral Hemorrhage

Spontan İntraserebral Hemoraji ile Ortaya Çıkan Glioblastoma Multiforme

Hemorajik Glioblastoma Multiforme / Hemorrhagic Glioblastoma Multiforme

Çağatay Özdöl[1], Tolga Gediz[1], Nalan Çiçek Özdöl[2], Aykut Recep Aktaş[3]
[1]Neurosurgery Clinic, Antalya Education and Research Hospital, Antalya,
[2]Radiology Clinic, Antalya Education and Research Hospital, Antalya,
[3]Department of Radiology, Faculty of Medicine, Süleyman Demirel University, Isparta, Turkey

Özet

Beyin tümörlerine eşlik eden intraserebral kanama nadir bir durumdur. Kanama bir beyin tümörünün ilk prezentasyonu açısından özellikle tümör küçük ve kanama yoğun ise bazı tanısal problemler oluşturabilir. Bu makalede ani başlayan baş ağrısı, sağ gözde görme bulanıklığı ve yürüme bozukluğu acil servise başvuran 47 yaşında erkek hasta bildirilmektedir. Kontrast madde verilmeden çekilen kraniyal tomografisinde sağ oksipital bölgede iyi sınırlı, aynı taraf ventriküle baskı yapan, yoğun periferal ödem alanı içeren hematom saptandı. Hastaneye yatışının altıncı saatinde nörolojik durumu bozulan hastaya acil kraniyotomi yapıldı ve hematom boşaltıldı. Kitlenin histopatolojik incelemesi glioblastoma multiforme ile uyumlu geldi. Tümörler spontan intraserebral kanamaların arkasına saklanabilirler. Neoplazmı gösteren preoperatif radyolojik belirtileri doğrulamak için histolojik örnekleme ve incelemeler yapılmalıdır.

Anahtar Kelimeler

Bilgisayarlı Tomografi; Glioblastoma Multiforme; Spontan; İntraserebral Hemoraji; Cerrahi

Abstract

Brain tumors with concomitant intracerebral hemorrhage are rarely encountered. Hemorrhage as the initial presentation of a brain tumour may pose some diagnostic problems, especially if the tumour is small or the hemorrhage is abundant. We present a 47-year-old man who admitted to the emergency department with sudden onset headache, right blurred vision and gait disturbance. A non-contrast cranial computerized tomography scan performed immediately after his admission revealed a well circumscribed right occipitoparietal haematoma with intense peripheral edema causing compression of the ipsilateral ventricles. On 6th hour of his admission the patient's neurological status deteriorated and he subsequently underwent emergent craniotomy and microsurgical evacuation of the haematoma. The histopathological examination of the mass was consistent with a glioblastoma multiforme. Neoplasms may be hidden behind each case of spontaneous intracerebral hemorrhage. Histological sampling and investigation is mandatory in the presence of preoperative radiological features suggesting a neoplasm.

Keywords

Computerized Tomography; Glioblastoma Multiforme; Spontaneous; Intracerebral Hemorrhage; Surgery

DOI: 10.4328/JCAM.3187 Received: 26.12.2014 Accepted: 16.01.2015 Printed: 01.06.2014 J Clin Anal Med 2014;5(suppl 3): 336-8
Corresponding Author: Çağatay Özdöl, Antalya Education and Research Hospital, Neurosurgery Clinics, 07100, Muratpaşa, Antalya, Turkey.
T.: +90 2422494400 F.: +90 2422494462 E-Mail: drcagatayozdol@gmail.com

Introduction

Glioblastoma multiforme (GBM) are highly invasive and vascular tumors comprising 80% of all malignant gliomas. The abundant angiogenic activity of the tumor, together with tumor cell dissemination in the brain, is largely responsible for tumor recurrence and poor prognosis despite treatment. The physical findings depend on the location, size, and rate of growth of the tumor, as with any other central nervous system tumor.

Brain tumors with concomitant intracerebral hemorrhage are rarely encountered [1]. Although current advances in radiological investigations enable proper preoperative diagnosis especially when the border between the tumoral mass and haematoma is clear, this may not be always possible if the hemorrhage is abundant. In such cases, the tumoral mass is masked by hemorrhage in preoperative radiological imaging and definite diagnosis can only be possible after surgery by histopathological examination.

We report a GBM case presenting with intracerebral haematoma as the initial preoperative diagnosis and briefly highlight the radiological and clinical features of these rare entities.

Case Report

A 47-year-old man with a previous history of appendectomy was admitted to the emergency department with sudden onset headache, right blurred vision and gait disturbance. Neurological examination revealed a Glasgow Coma Scale (GCS) score of 13/15 and left hemiparesia. A non-contrast cranial computerized tomography (CT) scan performed immediately after his admission revealed a well circumscribed right occipitoparietal haematoma with intense peripheral edema causing compression of the ipsilateral ventricles (Figure 1a). On magnetic resonance imaging (MRI) scans, occipitoparietal haematoma surrounding by a hypointens rim belongs to hemosiderin was seen in non-gadolinium enhancement axial T-1 weighted MRI section (Figure 1b). There was no specific contrast enhancement reminding of a tumor (Figure 1c-e), but there was extensive perifocal edema on the T-2 weighted images with enhanced cortical venous congestion reminding of a vascular malformation (Figure 1f). On 6th hour of his admission the patient's neurological status deteriorated to a GCS score of 11 and he subsequently underwent emergent craniotomy and microsurgical evacuation of the haematoma. Peroperatively, a gray-yellow coloured mass in close proximity to the ventricle was identified and totally removed. Following surgery the patient was taken to the intensive care unit and postoperative CT scan revealed total removal of the lesion (Figure 1g). The histopathological examination of the mass was consistent with a glioblastoma multiforme.

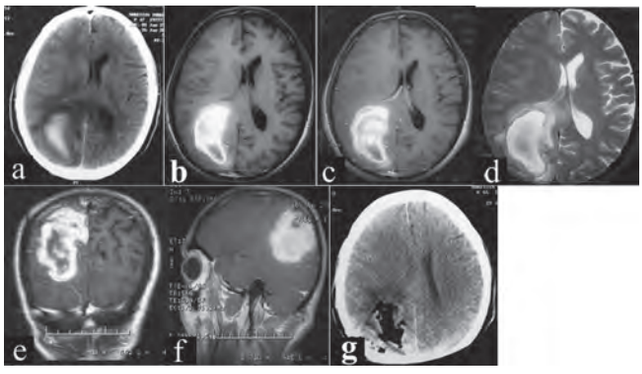

Figure 1. Axial CT scan (a) section shows a right occipitoparietal haematoma with intense peripheral edema causing compression of the ipsilateral ventricles. Occipitoparietal haematoma surrounding by a hypointens rim belongs to hemosiderin was seen in non- gadolinium enhancement axial T-1 weighted MRI section (b). Axial (c-d), coronal (e) and sagittal (f), gadolinium enhanced MRI sections showing no specific contrast enhancement. T-2 weighted MRI section (d) showing intense peripheral edema. Postoperative axial CT section (g) revealed total removal of the lesion.

Discussion

Intracerebral hemorrhage secondary to pathological changes initiated by chronic hypertension is responsible for approximately 75% of all cases of spontaneous intracerebral hemorrhages [2]. Hemorrhage secondary to a primary or metastatic brain tumors accounts for less than 10% of all intracerebral haematomas [3]. Metastatic brain tumors are reported to be the most frequent cause of tumour-related hemorrhage followed by malignant gliomas [4]. Accordingly, the present case of glioblastoma multiforme manifesting as acute hemorrhage is exceptionally rare.

The symptomatic presentation of GBM's include nonspecific and site specific symptoms which usually coexist. Nonspecific symptoms are the result of increased intracranial pressure and most commonly include chronic headache, nausea, drowziness and visual obscurations. Site specific symptoms include neurological deficits which are directly related with the location of the tumor. In the present case, after evaluating the factors and such as the relatively young age of the patient, lack of hypertension history, and atypical haematoma location hypertensive hemorrhage has been ruled and secondary causes of spontaneous hemorrhage such as the vascular malformative eitologies were considered in the differential diagnosis.

Rapidly dividing tumors such as GBMs, require a steady supply of nutrients and oxygen from the circulatory system in order to grow and continuous vascular supply is maintained by angiogenesis.Various theories have been proposed regarding the etiologies of intratumoral hemorrhage which briefly include endothelial proliferation with vascular obliteration, vessel compression and/or distortion as a result of rapid growth, vessel necrosis, tumoral invasion of the vessel wall and reduced structural quality of the newly formed vessels [5]. In the present case one or more mechanisms may have played a role in the glioblastoma cases all of these theories may be present and they cause rapid and extensive bleeding and so any case of glioblastoma may be presented with spontaneous intracerebral hemorrhage.

Intratumoral hemorrhages can easily be diagnosed by preoperative cranial CT particularly when the border between the tumor and hemorrhage is clear [6]. However diagnosing intratumoral hemorrhage may be challenging when the hemorrhage is abundant. Several features detected by CT have been reported to hint at an intratumoral hemorrhage, which include an irregular shape and an atypical location or a heterogeneous appearance with solid areas of blood, multiple hemorrhage, and a ring-shaped hemorrhage [4]. Peritumoral edema is also an important feature in the differential diagnosis because it is only rarely seen in the acute phase of spontaneous intracerebral hemorrhage, while it is a very common feature in expanding, space occupying lesions such as tumors [6]. Although administration

of contrast agents have also been suggested to aid in the differential diagnosis, in the presence of a large hemorrhage, such as the present case, the tumor may not be able to visualized, even if contrast material is used.

Although CT remains important in the acute setting, MR imaging has proved invaluable for diagnosis and work up of patients with spontaneous intracranial hemorrhage [7]. On MRI the features of the lesion and its relation with the neighbouring structures can be more readily visualized. It has been reported that on MRI, an underlying neoplasm should be suspected in any hemorrhage that evolves slowly, develops central or eccentric hyperintensity as it evolves, or exhibits a mixed-signal-intensity pattern [8]. The presence of a hemosiderin rim along the borders of the hemorrhage was also reported to hint at an intratumoral hemorrhage [8]. However, obtaining an MRI scan for every patient admitted to emergency department with spontaneous intracerebral hemorages especially in comatous condition is a quite time consuming and not cost-effective.

The indication for surgery should be based on a combination of the neurological condition on admission, estimated overall prognosis, and accompanying diseases rather than on age. The intraoperative surgical strategy should be decided according to the presence of radiological features suggesting an intratumoral hemorrhage. If the tumoral mass is identified peroperatively, such as the presented case, the surgical strategy should be aimed at total removal of the tumor along with the haematoma. If no mass is identified intraoperatively, but there is suspicion of the presence of a tumor preoperatively, samples should taken from and neighboring areas of the hematoma for further histopathological investigation.

Conclusion

A rare case of glioblastoma multiforme presenting as spontaneous intracerebral hemorrhage is presented. Neoplasms may be hidden behind each case of spontaneous intracerebral hemorrhage. Histological sampling and investigation is mandatory in the presence of preoperative radiological features suggesting a neoplasm.

Competing interests

The authors declare that they have no competing interests.

How to cite this article:
Özdöl Ç, Gediz T, Özdöl NÇ, Aktaş AR. Glioblastoma Multiforme Presenting as Spontaneous Intracerebral Hemorrhage. J Clin Anal Med 2014;5(suppl 3): 336-8.

References

1. Inamasu J, Kuramae T, Nakatsukasa M. Glioblastoma Masquerading as a Hypertensive Putaminal Hemorrhage: A Diagnostic Pitfall. Neurol Med Chir (Tokyo) 2009;49(9):427-9.
2. Manno EM, Atkinson JL, Fulgham JR, Wijdicks EF. Emerging medical and surgical management strategies in the evaluation and treatment of intracerebral hemorrhage. Mayo Clin Proc 2005;80(20):420-33.
3. Kase CS. Intracerebral hemorrhage: non– hypertensive causes. Stroke 1986;17(4):590-5.
4. Maiuri F, D'Andrea F, Gallicchio B, Carandente M. Intracranial haemorrhages in metastatic brain tumours. J Neurosurg Sci 1985;29(1):37-41.
5. Cheng SY, Nagane M, Huang HS, Cavenee WK. Intracerebral tumour-associated haemorrhage caused by overexpression of the vascular endothelial growth factor isoforms VEGF121 and VEGF165 but not VEGF189. Proc Natl Acad Sci USA 1997;94(22):12081-7.
6. Schrader B, Barth H, Lang EW, Buhl R, Hugo HH, Biederer J, et al. Spontanous intracranial hemorage caused by neoplasms. Acta neurochirur (Wien) 2000;142(9):979-85.
7. Meyer JR, Gorey MT. Differential diagnosis of nontraumatic intracranial hemorrhage. Neuroimaging Clin N Am 1998;8(2):263-93.
8. Destian S, Sze G, Krol G, Zimmerman RD, Deck MD. MR imaging of hemorrhagic intracranial neoplasms. AJR Am J Roentgenol 1989;152(1):137-44.