Congenital Hairy Polyp of the Nasopharynx

Konjenital Nazofarengeal Hairy Polip

Hairy Polip / Hairy Polyp

Medine Kara, Tolgahan Toroslu, Oğuz Güçlü, Fevzi Sefa Dereköy
Çanakkale Onsekiz Mart Üniversitesi Tıp Fakültesi, Kulak-Burun-Boğaz Hastalıkları Kliniği, Çanakkale, Türkiye

Özet

Bu çalışmada bir süt çocuğunda beslenme güçlüğü ve solunum sıkıntısı oluşturan nadir bir konjenital nazofarenks lezyonu sunulmuştur. Hırıltılı solunum, beslenme zorluğu şikayetleri olan İki aylık bir kız bebekte nazofarenksten dil posterioruna doğru sarkan pediküllü polipoid kitle total olarak çıkarıldı. Lezyonun histopatolojik incelemesi hairy polip olarak rapor edildi. Erken çocukluk döneminde solunum sıkıntısı ve beslenme güçlüğü şikayetleri olan hastalarda hairy polip ayırıcı tanıda düşünülmeli ve tanı için endoskopik muayene yapılmalıdır.

Anahtar Kelimeler

Endoskopik Muayene; Hairy Polip; Nazofarenks

Abstract

This study presents a rare congenital nasopharynx lesion in an infant with feeding difficulties and respiratory distress. A two-month old girl with wheezing and difficulty feeding had a pedicular polypoid mass hanging from the nasopharynx posterior to the tongue completely removed. Histopathological investigation of the lesion reported a hairy polyp. Patients with complaints of respiratory distress and feeding difficulties in the early newborn period should be considered for a diagnosis of hairy polyp and diagnosis should include endoscopic examination.

Keywords

Endoscopic Examination; Hairy Polyp; Nasopharynx

DOI: 10.4328/JCAM.3200 Received: 02.01.2015 Accepted: 14.01.2015 Printed: 01.06.2014 J Clin Anal Med 2014;5(suppl 3): 330-2
Corresponding Author: Medine Kara, Çanakkale Onsekiz Mart Üniversitesi Tıp Fakültesi, Kulak-Burun-Boğaz Hastalıkları Kliniği, Çanakkale, Türkiye.
GSM: +905332185350 E-Mail: medinekara@gmail.com

Introduction

Hairy polyps were first described by Brown-Kelly in 1918. They are rarely-seen benign malformations with two germ layers, originating in ectoderm and mesoderm, in the oropharynx and nasopharynx [1,2]. Hairy polyps, observed anywhere on the body, may be diagnosed at birth, a short while after birth or more rarely in adulthood [3]. Frequently they are located in the nasopharynx and may cause respiratory distress and swallowing difficulties depending on their size [1-4].

Case Report

A 2-month old baby girl with wheezing and difficulty feeding was brought to our clinic. During physical examination after gag reflex stimulation a polypoid mass about 1.5 x 1 cm hanging from the nasopharynx into the mouth posterior to the tongue was observed using a tongue depressor (Fig.A). On examination with a flexible nasopharyngoscope originating at the left posterior of the nasopharynx reaching to the oropharynx posterior to the tongue a 1.5 x1 cm pedicular polypoid lesion was observed. The patient was taken for surgery under general anesthetic and mass excision was performed by blunt dissection. Postoperative monitoring showed no complications and the patient's complaints resolved. The appearance of the macroscopic 1.5 x 1 cm grayish-pink polypoid mass after excision is shown in Fig.B. Histopathological investigation of the mass found it was a hairy polyp.

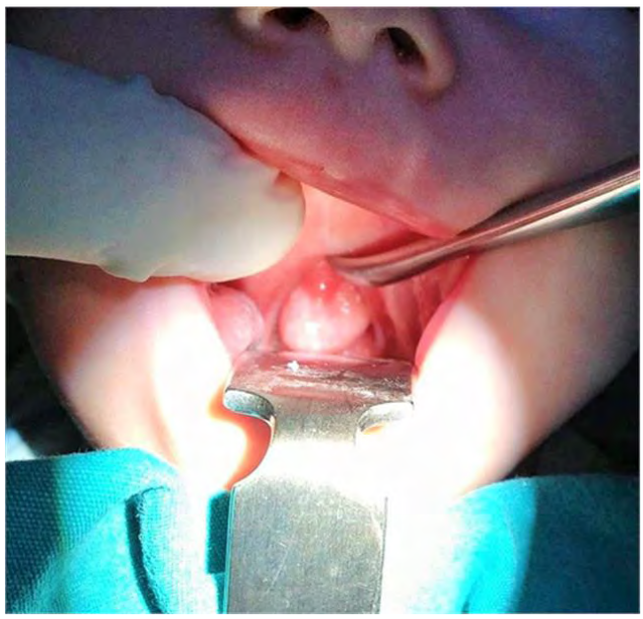

Figure 1. A polypoid mass about 1.5 x 1 cm hanging from the nasopharynx into the mouth posterior to the tongue was observed,

Discussion

The incidence of hairy polyp is 1/40000 with the most frequently observed type congenital nasopharynx masses [5]. Observed 6 times more in females than males, hairy polyps are not related to congenital syndromes and genetic predisposition has not been found [5,6]. However it may be observed with anomalies such as cleft palate, agenesis of uvula and auricula, absence of left carotid artery, osteopetrosis, ankyloglossia and facial hemihypertrophia [3-6]. Frequently it is observed in the pharynx and the stem is usually found in the side wall of the nasopharynx and above the outside of the soft palate [3].

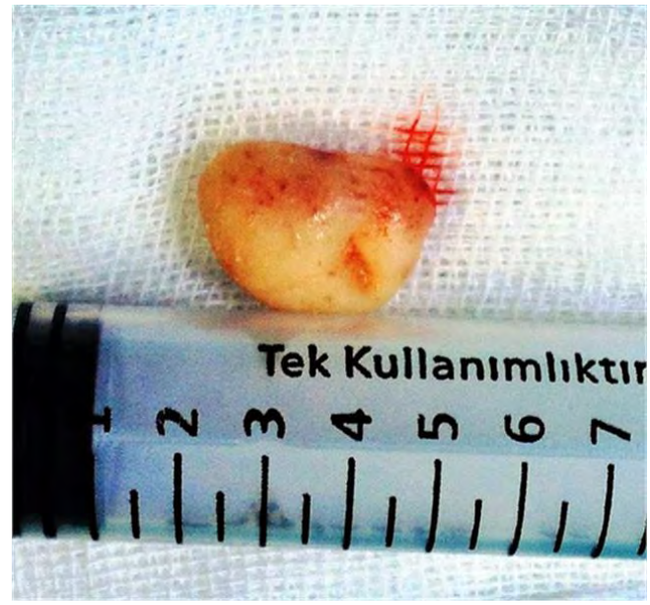

Figure 2. Image of the surgical specimen after the resection

Hairy polyps were first described by Brown-Kelly in 1918. They are rarely-seen benign malformations with two germ layers, originating in ectoderm and mesoderm, in the oropharynx and nasopharynx [1,2]. Hairy polyps, observed anywhere on the body, may be diagnosed at birth, a short while after birth or more rarely in adulthood3. Frequently they are located in the nasopharynx and may cause respiratory distress and swallowing difficulties depending on their size 1-4.

Generally patients apply with complaints of bruising, respiratory distress and feeding difficulties immediately after birth or a few days later, however small polyps may be ignored unless careful examination is made [1,3,4]. Diagnosis is made with correct physical examination and endoscopy. Imaging methods may be helpful for diagnosis [3].

Hairy polyps are benign lesions formed from two germ layers. While the central mesodermal structure may comprise fibroadipose tissue, muscle, bone, cartilage, lymph nodes and saliva glands, the ectodermal structure comprises multi-layered squamous epithelium and skin appendages [3]. As they do not involve the brain and spinal cord they are easily distinguished from craniopharyngioma. Differentiation from teratoma, dermoid tumors and hamartoma is difficult with imaging methods. The surest way to diagnose is pathological investigation. Treatment is surgical removal of the mass. As recurrence is a possibility, surgical excision should be carefully completed and postoperative monitoring is important [1,3].

Conclusion

Despite naso-oropharyngeal lesions are rare since the presentation varies from asymptomatic to life threatening naso-oropharyngeal airway obstruction, they must be considered in the differential diagnosis. These patients should be examined for accompanying congenital malformations. Surgical resection is the only treatment.

Competing interests

The authors declare that they have no competing interests.

References
1. Yilmaz M, Ibrahimov M, Ozturk O, Karaman E, Aslan M. Congenital hairy polyp of the soft palate. Int J Pediatr Otorhinolaryngol 2012;76(1):5-8.
2. Agrawal N, Kanabar D, Morrison GA. Combined transoral and nasendoscopic resection of an eustachian tube hairy polyp causing neonatal respiratory distress. Am J Otolaryngol 2009;30(5):343-6.
3. Jarvis SJ, Bull PD. Hairy polyps of the nasopharynx. J Laryngol Otol 2003;116(6):467-9.
4. Burns BV, Axon PR, Phade A. "Hairy Polyp" of the pharynx in association with an ipsilateral branchial sinus: evidence that the "hairy polyp" is a second branchial arch malformation. J Laryngol Otol 2001;115(2):145-8.
5. Gambino M, Cozzi DA, Aceti MG, Manfredi P, Riccipetitoni G. Two unusual cases of pharyngeal hairy polyp causing intermittent neonatal airway obstruction. Int J Oral Maxillofac Surg 2008;37(8):761-2.
6. Kalcioglu MT, Can S, Aydin NE. Unusual case of soft palate hairy polyp causing airway obstruction and review of the literature. J Pediatr Surg 2010;45(12):e5-8.

How to cite this article:
Kara M, Toroslu T, Güçlü O, Dereköy FS. Congenital Hairy Polyp of the Nasopharynx. J Clin Anal Med 2014;5(suppl 3): 330-2.