Dense Persistent Pupillary Membrane in an Adult Patient

Yetişkin Bir Hastada Yoğun Persistan Pupiller Membran

Yoğun Persistan Pupiller Membran / Dense Persistent Pupillary Membrane

Yeşim Altay, Özgür Balta, Ayşe Burcu
Department of Ophthalmology, Ankara Training and Research Hospital, Ankara, Turkey

Özet

Persistan pupiller membran (PPM) tunika vaskuloza lentis'in tam olmayan gerilemesi sonucunda ortaya çıkan ve yetişkinlerde nadir rastlanan bir konjenital anormalidir. Otuz yaşındaki erkek hasta sol gözde ilerleyici görme bulanıklığı ve her iki gözde farklı görünen pupil varlığı yakınmalarıyla başvurdu. Muayenede, düzeltilmemiş görme (Snellen) sağ gözde 20/100, sol gözde 20/640 idi ve solda amblyopi mevcut idi. Biyomikroskopik incelemede, bilateral dens PPM ve sol gözde kataraktı vardı. Sağ ve sol gözün görme alanı incelemesinde, görme alanlarında belirgin daralma saptandı. Biz bu olguyu PPM'lı hastalarda tedaviyi planlarken, görme alanı incelemesinin de en az santral görme kadar önemli olduğunu vurgulamak amacıyla sunduk. PPM'lı hastaların tedavisini planlarken görme bozukluğu, pupiller açıklığın boyutu ve görme alanının muayenesi dikkate alınmalıdır.

Anahtar Kelimeler

Persistan Pupiller Membran; Katarakt; Ambliyopi; Görme Alanı; Konjenital Oküler Anomaliler

Abstract

Persistent pupillary membranes (PPM) are congenital abnormalities which results from an incomplete involution of tunica vasculosa lentis and are rarely seen in adults. A thirty-year old man applied to the hospital with the complaint of uncommon-looking pupils and progressive blurring of vision in the left eye. On examination, uncorrected visual acuity (Snellen) were 20/100 in the right eye and 20/640 in the left eye with amblyopia. On biomicroscopic examination, there were bilateral dense PPM and cataract in the left eye. Visual field analysis of right and left eyes showed great narrowing of visual fields. We present our case in order to emphasize that analysis of visual field of patients with PPM is as important as central vision when planning its treatment. For planning treatment of patients with PPM, visual impairment, size of pupillary opening, and visual field analysis should be considered.

Keywords

Persistent Pupillary Membrane; Cataract; Amblyopia; Visual Field; Congenital Ocular Anomalies

DOI: 10.4328/JCAM.3204 Received: 03.01.2015 Accepted: 12.02.2015 Printed: 01.06.2014 J Clin Anal Med 2014;5(suppl 3): 397-9
Corresponding Author: Yeşim Altay, 48. Cadde Yonca Apt. No: 33/31, Cukurambar, Ankara, Turkey.
GSM: +905324902298 E-Mail: altayye@yahoo.com

Introduction

Persistent pupillary membrane (PPM) is an ocular congenital anomaly which results from an incomplete involution of tunica vasculosa lentis. Although familial forms have been reported, most cases are sporadic in nature [1].

The incidence of PPM ranges from 30% to 95% in normal newborns, and majority of them regress within the first year of life [2]. Dense PPMs are rare in adult eyes.

We report a case of 30 years old man diagnosed with bilateral dense persistent pupillary membrane and unilateral cataract.

Case Report

30 year old man presented to the Ophthalmology Clinic of our hospital with the complaint of uncommon-looking pupils and progressive blurring of vision in the left eye. The patient claimed that his vision of both eyes was inadequate from childhood and there were no documented systemic or ocular illnesses.

On examination, uncorrected visual acuity (Snellen) were 20/100 in the right eye and 20/640 in the left eye with amblyopia. Best corrected visual acuity were 20/32 in the right eye and 20/100 in the left eye with myopic correction.

On biomicroscopic examination, both eyes had clear corneas and normal deep anterior chambers. Examination revealed the pupils were covered with a network of pigmented tissue, running from the iris surface spreading over the pupils. (Figure 1)

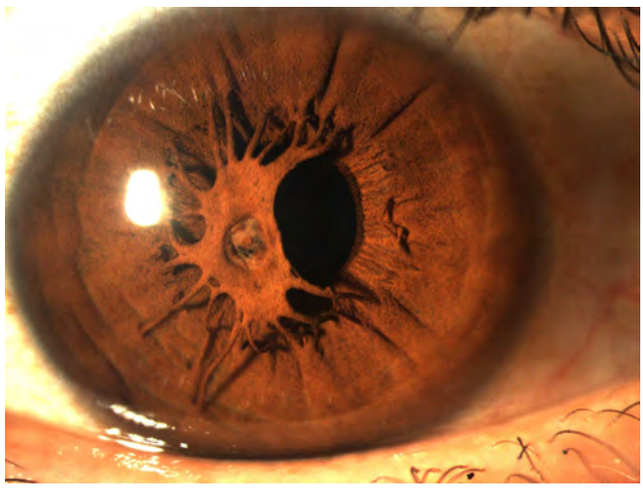

Figure 1. Persistent pupillary membrane of the right eye.

In the left eye this tissue was sticky to the lens and there was a cataractous change (Figure 2). Gonioscopy results were normal in both eyes. Intraocular pressure were 20 mmHg in the right eye and 22 mmHg in the left eye. Axial length of right and left eye 23,05 mm and 23,86 mm respectively.

Evaluation with pentacam corneal topography revealed that central corneal thickness was 590 µm in the right eye and 596 µm in the left eye and there were bilateral bowtie corneal astigmatism (Figure 3 a-b). Vision analysis of right and left eyes showed great narrowing of visual field. (Figure 4 a-b) After the pupils were dilated both fundi were within normal limits.

We planned surgical excision of membranes and cataract surgery for the left eye. But the patient refused the treatment.

Discussion

During intrauterine life, the lens receives nourishment from the

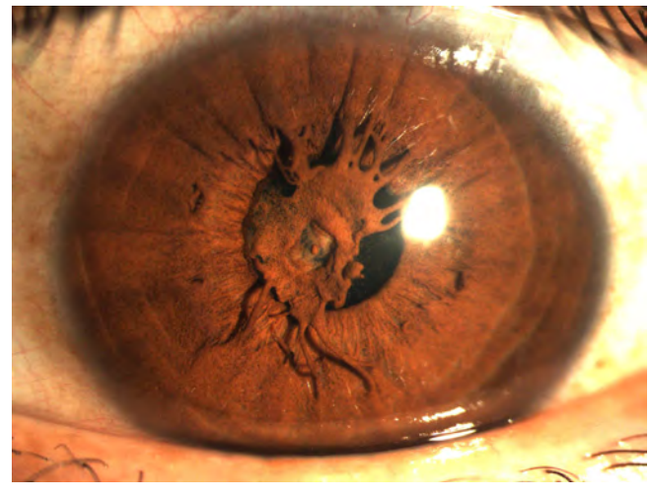

Figure 2. Persistent pupillary membrane with cataract of the left eye.

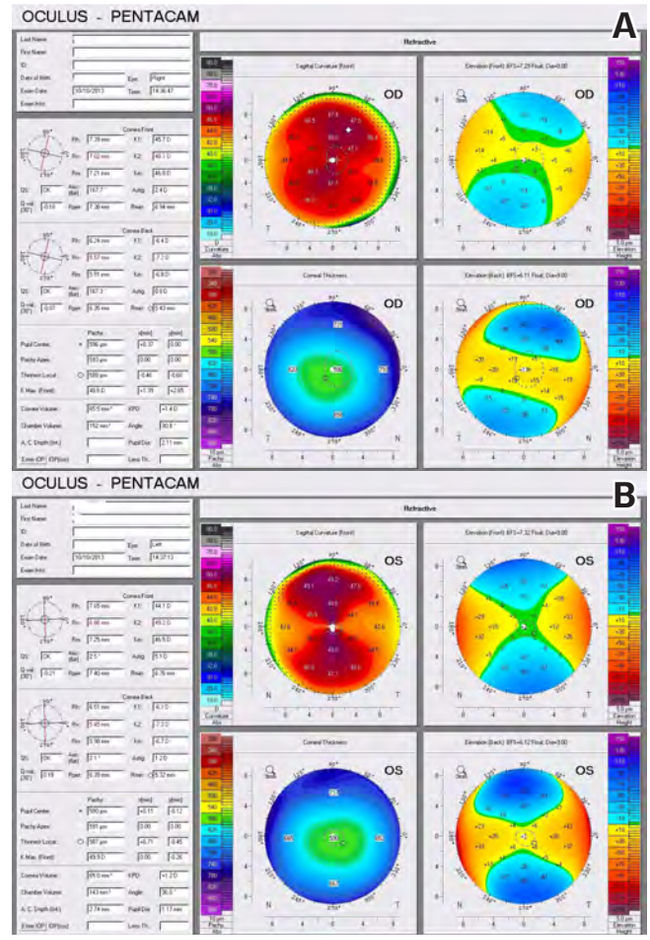

Figure 3. Pentacam corneal topography of the right eye(A). Pentacam corneal topography of the left eye(B).

posterior and anterior tunica vasculosa lentis [2]. The persistent pupillary membrane (PPM) represents the congenital remnant of the anterior tunica vasculosa lentis. The pupillary membrane itself begins to regress in the sixth month and dissappears completely by the eight month of gestation, if an arrest occurs in this process it will result in PPM [3]. PPM may be seen as isolated or in association with other ocular pathologies like microcornea, posterior keratoconus and macular hypoplasia [4,5].

PPM often spans the pupil from its insertion in the iris collarate, and attachment of it to the lens can cause cataract and visual deprivation as in our case. PPM may not affect central vision

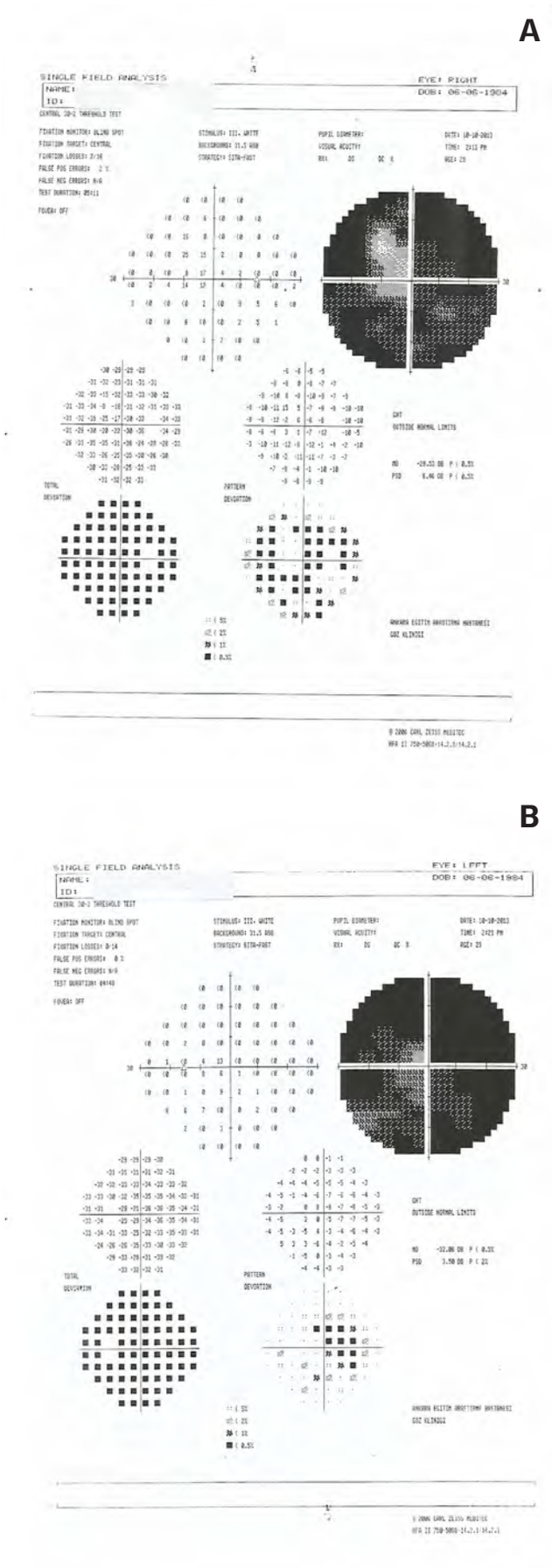

Figure 4. Visual field analysis of the right eye (A). Visual field analysis of the left eye (B).

unless the pupillary opening is less than 1,5 mm in size. Thus it seems that most cases are not significant enough to have visual impairment and so may go undetected [6]. However, as in this patient's right eye, although visual acuity was good, visual field analysis might show impairment despite enough pupillary opening. Besides PPM, narrowing of the visual field of the left eye might be affected by cataract as well.

Primary indications for the treatment of PPM are restoration of vision and prevention of amblyopia in children [6].

First-line treatment in patients with visual impairment generally consist of medical therapy with mydriatic agents. If medical therapy is ineffective, surgical removal is an alternative management. Treatment options include Nd-YAG or Argon laser therapy to the central portion of the membrane and surgical excision of the membranes [7]. Argon laser treatment reported as causing less hyphema than Nd-YAG laser [7].

Since surgical excision may be associated with complications such as cataract, hyphema and infection, some authors recommend a conservative approach if a patient have a good vision, even in the case of dense PPMs [8].

In conclusion, bilateral dense persistent pupillary membranes are rare congenital abnormalities in adults. Although patients with PPM have adequate central vision due to pinhole effect, PPM may cause significant decrease in visual field as in our patient. We presented this case in order to emphasize that analysis of visual field of patients with PPM is as important as central vision when planning its treatment. We have not found any reported case or case series in literature evaluating visual field of patients with PPM. For planning treatment of patients with PPM, visual impairment, size of pupillary opening, and visual field analysis should be considered.

Competing interests

The authors declare that they have no competing interests.

References

1. Norris HJ, Backhouse OC. The congenital pinhole:a persistant pupillary membrane. Clin Exp Optom 2010;93(2):100-1.
2. Forrester JV, Dick AD, McMenamin P, Lee WR. Embryology and early development of the eye and adnexa. In: Forrester JV, Dick AD, McMenamin P, Lee WR, editors.The Eye Basic Sciences in Practice.2nd edition. Edinburgh: WB Saunders;2002.p.99-129.
3. Wright KW, Speigel PH, Buckley EG. Embryology. In: Wright KW, Speigel PH,editors.Pediatric Ophthalmology and Strabismus.2nd edition. New York: Springer-Verlag; 2003.p.17.
4. Viswanathan D, Padmanabhan P, Johri A. Hyperplastic persistant pupillary membranes with congenital corneal anomalies. J Cataract Refract Surg 2007;33(6):1123-6.
5. Altun A, Kurna SA, Bozkurt E, Erdoğan G, Altun G, Olcaysu OO, et al. Bilateral persistant pupillary membrane with tetralogy of fallot: A case report and review of the literature. Case Reports in Ophthalmological Medicine 2014; doi:10.1155/2014/581273
6. Lee SM, Yu YS. Outcome of hyperplastic persistant pupillary membrane. J Pediatr Ophthalmol Strabismus 2004;41:163-71.
7. Bucan K, Znaor L, Jurasin K, Buban D, Galetovic D, Lesin M. Laser management of persistant pupillary membrane prior to cataract surgery. Acta Clin Croat 2008;47(Suppl. 1):7-9.
8. Meyer-Rüsenberg B, Thill M, Vujancevic S, Meyer-Rüsenberg HW. Conservative management of bilateral persistant pupillary membranes with 18 years of follow up. Graefes Arch Clin Exp Ophthalmol 2010;248:1053-4.

How to cite this article:
Altay Y, Balta Ö, Burcu A. Dense Persistent Pupillary Membrane in an Adult Patient. J Clin Anal Med 2014;5(suppl 3): 397-9.