An Unusual Presentation of Lung Cancer Metastasis: Perianal Abscess

Akciğer Kanseri Metastazının Nadir Bir Prezentasyonu: Perianal Apse

Akciğer Kanserinin Perianal Metastazı / Perianal Metastasis of Lung Cancer

Murat Özgür Kılıç[1], Meral Şen[1], Ahmet Türkan[1], Ümran Yıldırım[2], Aslı Köktener[3]
[1]Department of General Surgery, [2]Department of Pathologia, [3]Department of Radyology,
School of Medicine, Turgut Özal University, Ankara, Turkey

An abstract of this manuscript has been presented in 19. National Surgery Congress as a poster.

Özet

Akciğer kanseri, hem erkeklerde hem de kadınlarda en sık görülen kanserlerden biridir. Akciğer kanserlerinin en sık uzak metastaz yerleri plevra, karaciğer, böbreküstü bezleri, iskelet sistemi ve beyin olmasına karşın, perianal bölge nadir bir metastaz yeri olarak bildirilmiştir. Bir erkek hasta uzun süredir varolan perianal apse ile acil servise başvurdu. Apse drenajı sırasında, apse poşunun tabanında bir kitle fark edildi ve bir biyopsi alındı. Patolojik olarak, skuamöz hücreli karsinom metastazı olarak rapor edildi, bu nedenle birincil kanser odağını belirlemek için bazı radyolojik tetkikler ve endoskopik işlemler uygulandı. PET/BT' de primer tümör olarak düşünülen, pulmoner kitle saptandı. Hem primer ve hem de metastatik perianal tümörler nadiren bir apse oluşumu ile ortaya çıkabilirler. Bu durumda, esas tanıda gecikmeyi önlemek için lezyondan bir biyopsi yapılmalıdır.

Anahtar Kelimeler

Perianal Apse; Perianal Metastaz; Akciğer Kanseri

Abstract

Lung cancer is one of the most commonly diagnosed cancers in both men and women. Although the most frequent sites of distant metastasis of lung cancers are the pleura, liver, adrenal glands, skeletal system and brain, perianal region has been rarely reported as a metastasis site. A male patient was admitted to our emergency room with a long standing perianal abscess. During abscess drainage, a mass was noticed at the base of the abscess pouch, and thus a biopsy was taken. Pathologically, it was reported as a metastasis of squamous cell carcinoma, therefore some radiological investigations and endoscopic procedures were performed to determine the primary focus of cancer. A pulmonary mass was revealed in PET/CT, and was considered as primary tumor. Both primary and metastatic perianal tumors can be rarely presented as an abscess formation. In this situation, a biopsy should be performed from the lesion to avoid misdiagnosis.

Keywords

Perianal Abscess; Perianal Metastasis; Lung Cancer

DOI: 10.4328/JCAM.3249 Received: 19.01.2015 Accepted: 02.02.2015 Printed: 01.06.2014 J Clin Anal Med 2014;5(suppl 3): 369-71
Corresponding Author: Murat Özgür Kılıç, Department of General Surgery, School of Medicine, Turgut Özal University, Emek, Ankara, Türkiye.
T.: +90 3122035555 GSM: +905053573122 F.: +90 3122213670 E-Mail: murat05ozgur@hotmail.com

Introduction

Lung cancer is one of the most commonly diagnosed cancers in both men and women worldwide [1]. Liver, pleura, adrenal glands, skeletal system and brain are the most frequent sites of distant metastasis of lung cancers [2]. However, perianal region is an uncommon metastasis site. As is well known, perianal abscess is one of the most common surgical disorders and is treated with incision and drainage traditionally. When there is a suspicion of an underlying mass during abscess drainage, a biopsy should be taken to avoid a delay in diagnosis. Herein, we reported a rare case of lung cancer metastasis to the perianal region in the form of an abscess.

Case Report

A-73-year-old male patient with a 50-year smoking history was admitted to our institution with a painful perianal abscess for one week. The patient had chronic obstructive pulmonary disease and coronary artery disease, and the parental history was negative for cancer. On examination, approximately 5×5 cm in size, an indurated and hyperemic area with fluctuation was observed at the left side of the anus. Luminal pathologia was not determined in digital rectal examination. Further investigations demonstrated normal hemoglobin concentration and high leukocyte count of 12900/ml. Incision and drainage with a biopsy from the suspected mass located at the base of the abscess pouch were performed. Magnetic resonance imaging (MRI) showed a peripherally contrast enhancing ischioanal fossa abscess with the external sphincter inflammation on the left side of the anal canal (figure 1). The result of biopsy was reported as metastasis of squamous cell carcinoma (figure 2,3). Colonoscopy and thorax computed tomography (CT) were applied for detecting of primary tumor. On CT, some changes of thick-walled honeycomb appearance were detected in the area of 7.5×4 cm in the superior lower lobe segment of the right lung with multiple calcified and non-calcified mediastinal and hilar lymph nodes (figure 4). Colonoscopic evaluation was normal. PET/CT revealed a thick-walled mass, measuring to approximately 4 cm., with specular extensions and pathological uptake of F-18 FDG (SUV max: 12.2) in the posterior segment of the upper lobe of the right lung as the focus of primary tumor. In addition, two masses with less pathological uptakes of F-18 FDG were detected in the right adrenal gland and perianal region which were considered to be metastatic lesions arising from the primary lung cancer (figure 5). The bronchoscopic biopsy was also consistent with squamous cell carcinoma.

A written consent was obtained from the patient for this study, and after healing of the perianal abscess he was referred to the Medical Oncology Department for adjuvant treatment.

Discussion

Lung cancer is known to be the most common cause of cancer-related mortality worldwide. Early detection of this malignancy is infrequent, and most cases can not be diagnosed and treated until they are at advanced stage. Similarly, we detected a lung cancer which was metastasized to the left adrenal gland and perianal area in our patient. It is well known that lung cancer frequently metastasizes to the pleura, liver, bony skeleton, adrenal glands and brain, but rarely presented in the form of a

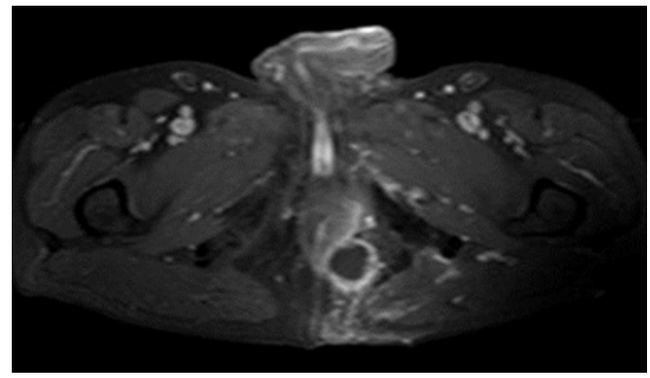

Figure 1. Axial post-contrast fat-saturated T1W MR image shows peripherally contrast-enhancing ischioanal fossa abscess with external sphincter inflammation on the left side.

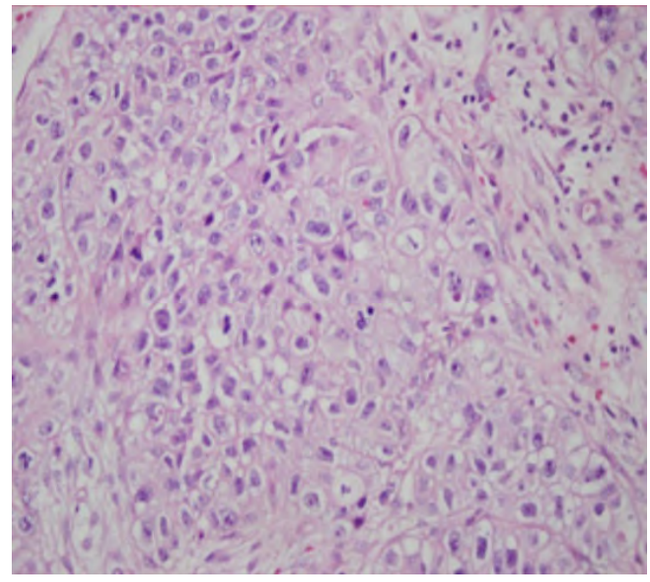

Figure 2. Tumor characterized by atypical cells with large eosinophilic and clear cytoplasm, massive hyperchromatic nucleus, distinctive nucleoluses and presenting with big cell groups in desmoplastic stroma (H&E×400).

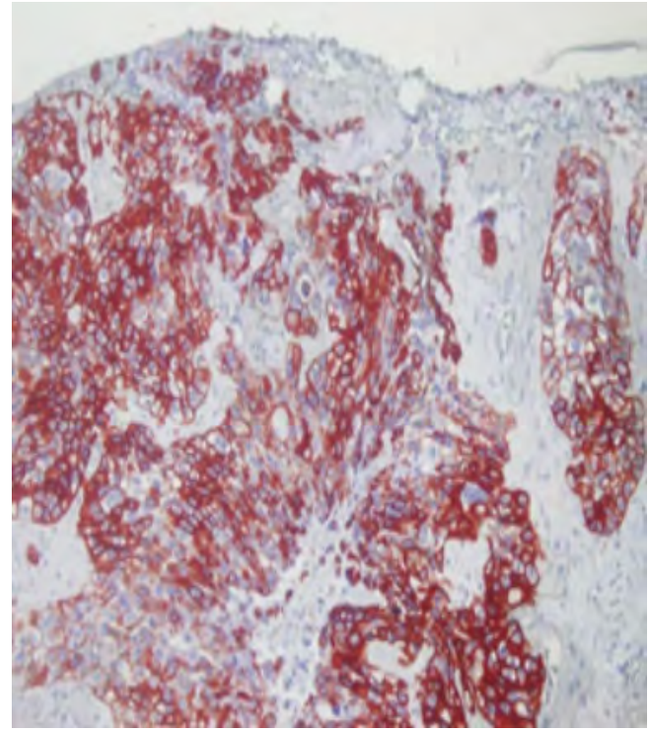

Figure 3. Immunohistochemically diffuse intense staining with cytokeratin 14 was observed (cytokeratin 14×200).

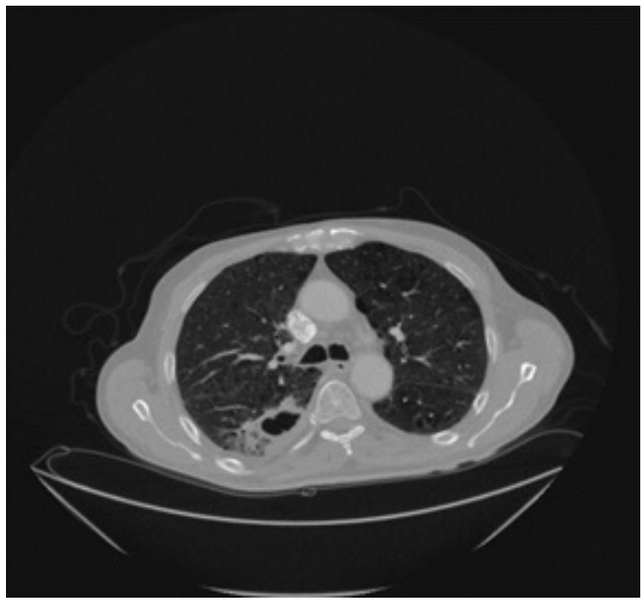

Figure 4. Contrast- enhanced transverse CT scan of the chest shows peripherally located cavitated mass in the superior lower lobe segment on the right side.



Figure 5. PET/CT images of the body show a mass in the right lung, adrenal mass on the right side, and mass in the left ischioanal fossa with radiotracer uptake

perianal abscess. Perianal abscess is a common surgical problem that caused by infection of anal glands. It usually presents as a painful lump close to the anal margin, and its diagnosis is mainly based on physical examination. However, imaging methods such as CT, MRI and endoanal ultrasound may be needed to diagnose some cases with deeper perianal abscess. This surgical entity is often treated with incision and drainage with a high rate of success.

On the other hand, tumors of the perianal region are uncommon and can occur in a variety of ways. Secondary tumors usually occur as result of infiltration of anorectal cancers, and constitute to the most of perianal tumors. Tumors located in the perianal region may mimic the symptoms and signs of anorectal sepsis, thus this condition can easily lead to a delay in diagnosis and treatment of primary disease [3]. Our patient was also admitted with complaint of severe perianal abscess, and while draining the abscess, an irregular mass was detected in the abscess pouch. Therefore, a biopsy was taken from the suspected mass. Later on, detailed radiological and endoscopic investigations were performed to detect the primary tumor. In the literature, several cases of perianal tumors presented as a perianal abscess have been reported [4,5]. In addition, a case of perianal metastasis of non-small cell lung cancer that was mimicking hemorrhoidal disease was reported by Imai et al. [6], as an interesting and rare clinical condition. However, metastatic tumors of perianal region, especially in the form of abscess formation, are extremely rare. To the best of our knowledge, there are only two case reports similar to our case in the literature [7,8].

In conclusion, primary or secondary perianal tumors may present as an abscess formation. In this case, a biopsy should be taken when there is a suspicion of underlying mass within the abscess pouch, and these patients should be evaluated in detail.

Competing interests

The authors declare that they have no competing interests.

References

1. Siegel R, Naishadham D, Jemal A. Cancer statistics, 2012. CA Cancer J Clin 2012;62(1):10-29.
2. Cheng L, Eng C, Nieman LZ, Kapadia AS, Du XL. Trends in colorectal cancer incidence by anatomic site and disease stage in the United States from 1976 to 2005. Am J Clin Oncol 2011;34(6):573–80.
3. Bracey EE, Mathur P, Dooldeniya M, Joshi A, Dawson PM. Unusual perianal tumours masquerading as abscesses. Int J Clin Pract 2003;57(4):343-6.
4. Ganeshan A, Soonawalla ZF, Baxter JN. Perianal abscess: an unusual presentation of non-Hodgkin's lymphoma. Eur J Surg 2002;168(11):657-9.
5. Leung TH, Lee HH, Chang SC. Perianal eccrine adenocarcinoma. World J Surg Oncol 2007;5:100.
6. Imai H, Inafuku K, Wakuda K, Ono A, Taira T, Kenmotsu H et al. Perianal metastasis of non-small cell lung cancer. Intern Med 2014;53(11):1149-52.
7. Srikanth B, Sankar NS, Kong KC, Bassily AA. Lessons to be learned: a case study approach: metastatic bronchogenic carcinoma presenting as a gluteal abscess. J R Soc Promot Health 1999;119(4):264-7.
8. Tek I, Iyidir OT, Utkan G, Ceyhan K, Buyukcelik A, Yalcin B et al. Lung cancer metastasis mimicking gluteal abscess. South Med J 2007;100(3):334-5.

How to cite this article:
Kılıç MÖ, Şen M, Türkan A, Yıldırım Ü, Köktener A. An Unusual Presentation of Lung Cancer Metastasis: Perianal Abscess. J Clin Anal Med 2014;5(suppl 3): 369-71.