Retrieval of a Stuck Coronary Stent with a Micro Snare: A Modified Employment of a Familiar Device

Sıkışmış Koroner Stentin Mikro Snare ile Çıkarılması: Tanıdık bir Aletin Farklı Kullanımı

Sıkışmış Koroner Stentin Çıkarılması / Retrieval of a Stuck Coronary Stent

Ahmet Karakurt[1], Hamit Serdar Başbuğ[2], Abdurrezzak Börekçi[1], Macit Bitargil[2]
[1]Department of Cardiology, [2]Department of Cardiovascular Surgery,
Kafkas University Faculty of Medicine, Kars, Turkey

This paper was accepted as oral presentation in 11th International Congress of Updates in Cardiology and Cardiovascular Surgery.

Özet

Perkütan koroner girişimlerde bir çok komplikasyon izlenebilir. Koroner arter içinde stent sıkışması nadir fakat öldürücü bir komplikasyondur. Stent çoğunlukla açılmamıştır ve bu yüzden yabanci cisim gibi davranır. Akut koroner sendrom, açık kalp cerrahisi gereksinimi ve mortalite gibi daha ciddi komplikasyonları önlemek için cismin acil olarak çıkarılması gereklidir. Bu amaç için kullanılan farklı alet ve metodlar mevcuttur. Bu olguda, tam açılmaksızın sıkışmış bir koroner stentin, farklı şekilde kullanılan bir mikro snare yardımıyla çıkarılma işlemi sunulmaktadır.

Anahtar Kelimeler

Sıkışmış Stent,; Mikro Snare; Çıkarılma; Teknik

Abstract

Considering percutaneous coronary interventions, there are various complications. Stent stuck inside the coronary artery is a rare but deadly condition. The stent is often unopened so it behaves like a foreign body. Urgent withdrawal of the material is crucial to prevent further complications like acute coronary syndrome, progression to open cardiac surgery and finally death. There are some methods and devices for this purpose. In this case, modified employement of a micro snare for the retrieval of an unopened stuck coronary stent is presented.

Keywords

Stuck Stent; Micro Snare; Retrieval; Technique

DOI: 10.4328/JCAM.3250 Received: 19.01.2015 Accepted: 04.02.2015 Printed: 01.06.2014 J Clin Anal Med 2014;5(suppl 3): 375-8
Corresponding Author: Hamit Serdar BAŞBUĞ, Kafkas University Faculty of Medicine, Department of Cardiovascular Surgery, Kars, Turkey.
GSM: +905052612372 F.: +90 4742251193 E-Mail: s_basbug@hotmail.com

Introduction

As a coronary stent, slipping away prematurely over its balloon and sticking in an inappropriate location of the lesion, is a rare but life threading condition [1,2]. An interventional cardiologist should be familiar with the complication of unwanted site of early stent deployment behaving like an intracoronary foreign body, and be experienced on the alternative possible treatments. Despite the presence of a guideline referring this complication, there may be more other different techniques [3]. In this case, withdrawal of a stuck stent in the circumflex coronary artery with a 0.014 inch guide wire accompanied Loop Snare (LS) is presented. According to the previous literature regarding the withdrawal of the stuck stents, this technique is the first ever mentioned.

Case Report

A 45-year-old male patient suffering typical angina pectoris, left arm pain and cold sweating was admitted to the emergency department. Blood pressure and pulse rate was 97/72 mmHg and 75/min respectively. The Electrocardiogram (ECG) on admission, showing sinus rhythm with ST segment elevation in the derivations of D1, D2, D3 and V5, V6. Biochemical tests revealed that blood Troponin I (>25 ng/mL, Normal: <0.3ng/mL), CK-MB (92.8 U/L, Normal range: 0-24 U/L), and CK (1407 IU, Normal range: 0-170 IU) levels were increased.

Depending on a strong clinical, electrocardiographic and biochemical evidence of an Acute Myocardial Infarction (AMI), it was decided to perform a Coronary Angiography (CAG) first and subsequent primary Percutaneous Coronary Intervention (PCI) if then needed. Antiplatelet agents as Acetyl Salicylic Acid (300 mg), Clopidogrel (600 mg) and Heparin (80U/kg IV bolus) were given prior to CAG as a premedication. The CAG revealed one vessel disease with 100% occlusion in proximal Circumflex Artery (CxA) prior to the first obtuse marginal branch. There were no existing critical lesion in the Left Anterior Descending (LAD) and Right Coronary Artery (RCA) (Fig 1A). After setting the diagnosis of Coronary Artery Disease (CAD) depending on CAG, it was decided to perform PCI to the occluded arterial segment.

A Guiding catheter (7F) was settled to the Left Main Coronary Artery (LMCA) ostium and a 0.0014 inch floppy guide wire was advanced to the CxA through the totally occluded, thrombotic and the tight lesion (Fig 1A). During the progression of the guide wire through the lesion, TIMI (Thrombolysis In Myocardial Infarction) grade 2 distal coronary arterial flow was achieved. A dimensionally appropriate (2,5 mm x 26 mm), Sirolimus-eluting stent (Orsiro, hybrid drug eluting stent, Biotronik AG, Switzerland) was advanced but failed to cross the proximal CxA and stuck in the tight lesion. While withdrawing the stent carrying system back into the guiding catheter, the stent wriggled out over the carrying balloon and remained unopened in the lesion lodge (Fig 1B).

The stuck stent was intended to be removed using an LS. As removal of the stuck stent with LS in the absence of a guide wire was considered to be difficult, a 0.014 inch guide wire progressed distally through the CxA and placed inside the artery. After the proximal end of the guide wire passed through the eye of LS noose, excessive part was withdrawn back into the snare catheter and slipped forward over the wire. Inside the guiding

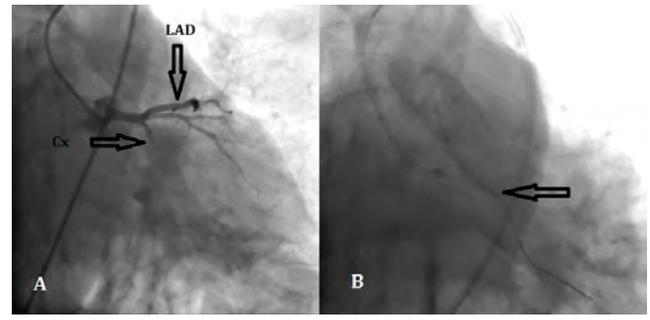

Figure 1. RAO caudal view showing total occlusion in the proximal left circumflex artery (A). Stuck unopened stent in the proximal left circumflex artery (B).

catheter, LS slipped forward over the fixed guide wire until it reaches the proximal end of the stuck stent. LS noose was re-opened wide 5 mm proximal to the stent by simply progressing the snare wire forwardly inside the fixed snare catheter. After a few attempt, the proximal end of the stent was caught by the noose of the LS. Catheter of the LS was progressed to reduce the size of the noose and also by the help of the 0.014 inch guide wire, the stent was clutched and secured. All of the equipment, consisting of the 0.014 inch guide wire, LS catheter and the gripped stuck stent were pulled back into the guiding catheter (Fig 2). And finally, the 7F guiding catheter was then withdrawn out through the 7F femoral sheath (Fig 3).

Another guiding catheter was placed to the left main coronary

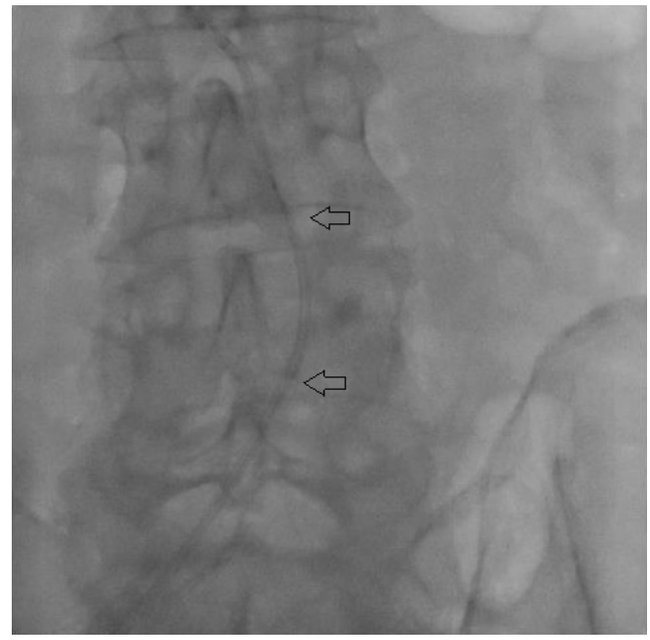

Figure 2. The angiographic view of the entrapped stent within the 7F guiding catheter, with Loop Snare and 0.014 inch guidewire.



Figure 3. Picture of the stent, snare and wire after the retrieval.

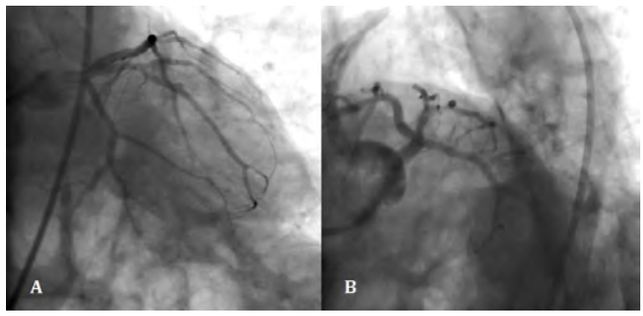

Figure 4. Final angiogram showing TIMI 3 flow with no residual lesion in the proximal left circumflex artery. (A.Caudal view, B.Spider view)

ostium and the lesion was passed distally by another 0.014 inch guide wire again. After the pre-dilatation by balloon (2.0 mm x 20 mm) twice, a stent (2.5 mm x 28 mm) was successfully implanted inside the lesion. After the procedure, TIMI flow grade 3 in the occluded CxA was achieved (Fig 4). All the procedure, including the initial withdrawal of the stuck stent and the second attempt of PCI took 46 minutes.

Discussion

Regarding the coronary stenting procedure, there are many complications including stent loss, stent damage, stent migration, balloon rupture, balloon shaft fracture, coronary artery damage and device entrapment [1,2]. One of the serious, rare and life-threatening complications during PCI is stuck of unopened stent in the coronary arteries. This potential complication can cause coronary occlusion and thrombosis, myocardial infarction, systemic embolization and even death during this treatment procedure [1,4,5]. Factors predisposing to the stent entrapment include calcification and long lesion, lack or inadequate pre-dilatation of lesion, angulated and tortuous vessel, manually crimped stents, repeated forth and back movements while trying to cross lesion, and lack of guiding catheter support [2]. However, the incidence of stuck stent and subsequent stent loss during coronary stenting procedure has decreased due to the remarkable improvement of the stent and stent delivery systems [6,7]. Its incidence reported 0.32-8.3% in the present studies [1,8].

Different maneuvers including “proximal grab”, “distal wire grab”, “coaxial snare”, “lateral grasp”, guide wire as a snare”, “hairpin trap”, “two-wire”, “small balloon catheter” techniques and different device including “stone retrieval baskets/dormia baskets”, “intravascular retrieval forceps”, “biliary or myocardial biopsy forceps”, “loop snare”, “a new device for removal of vascular stents (no named)” were developed to salvage the entrapped, mispositioned or embolized foreign body [9,10]. As the simplest solution of stuck stent, repositioning of the stent or embedding of the unopened stent with the help of another stent into the coronary arterial wall is recommended [3]. In this case, withdrawal of the stent was planned firstly as it was stuck inside the proximal CxA lesion. For this purpose, LS, which is designed and is one of the frequently used devices was used [2]. LS is made of a steel wire and nitinol catheter carrying the wire. At the end of the wire, a noose which is designed 90 degrees of angle with its wire is present to facilitate the grasping of the targeted object. There are different types of snares exist with the noose diameters varying from 2 mm to 35 mm [3,9].

Stent removal using LS is achieved in two ways. In the first way, LS is direct approaches forward through the guiding catheter without using a guiding catheter. In the second way of this case, LS noose is progressed over the 0.014 inch guide wire inside the guiding catheter, providing support and interventional precision with more accurate and refined approximation up to the stent.

We had two major troubles. Firstly, due to weak radial and longitudinal support of the 0.014 inch guide wire, the LS could hardly be progressed through the guiding catheter over the wire. For the prevention of kinking and breaking of the guide wire, the progression was made slowly and carefully. Harder wires can support better. Secondly, due to again lack of enough support of the guide wire, catching the stuck stent with LS noose was not easy. LS was either misplaced along the side of the stent causing rebound of the guiding catheter and guide wire. Another trouble which we haven’t had, could be the inability to withdraw the LS, guide wire and stent trio back inside the guiding catheter. Contrary to our performance, withdrawal maneuver is recommended at level iliac artery to prevent lethal complications due to stent emboli [11]. Using guiding catheter with larger calibers, picking the stuck stent just at the tip and providing the exact longitudinal alignment of the stent and the catheter can facilitate the procedure.

As a conclusion, stuck stent during PCI can cause complications like acute coronary syndrome, progression to the coronary artery bypass surgery and death. It is curable and various methods exist. Each patient must be evaluated individually. Depending on the operator experience and interventional laboratory equippment, safer, shorter and less risky treatment method should be chosen.

Conflict of Interest: The authors declared no conflict of interest.
Declaration: This paper was accepted as oral presentation in 11th International Congress of Updates in Cardiology and Cardiovascular Surgery.

Competing interests

The authors declare that they have no competing interests.

References

1. Iturbe JM, Abdel-Karim AR, Papayannis A, Mahmood A, Rangan BV, Banerjee S, et al. Frequency, treatment, and consequences of device loss and entrapment in contemporary percutaneous coronary interventions. J Invasive Cardiol 2012;24:215-21.
2. Brilakis ES, Best PJ, Elesber AA, Barsness GV, Lennon RJ, Holmes DR Jr, et al. Incidence, retrieval methods, and outcomes of stent loss during percutaneous coronary intervention: a large single-center experience. Catheter Cardiovasc Interv 2005;66(3):333-40.
3. Ellis SG, Holmes DR. Strategic approaches in coronary intervention (3rd edition). Baltimore: Lippincott Williams & Wilkins; 2005.p.421-35.
4. Bolte J, Neumann U, Pfafferott C, Vogt A, Engel HJ, Mehmel HC, et al. Incidence, management, and outcome of stent loss during intracoronary stenting. Am J Cardiol 2001;88(5):565-7.
5. Kammler J, Leisch F, Kerschner K, Kypta A, Steinwender C, Kratochwill H, et al. Long-term follow-up in patients with lost coronary stents during interventional procedures. Am J Cardiol 2006;98(3):367-9.
6. Eggebrecht H, Haude M, vonBirgelen C, Oldenburg O, Baumgart D, Herrmann J, et al. Non-surgical retrieval of embolized coronary stents. Catheter Cardiovasc Interv 2000;51:432-40.
7. Lohavanichbutr K, Webb JG, Carere RG, Solankhi N, Jarochowski M, D’yachkova Y, Dodek A. Mechanisms, management, and outcome of failure of delivery of coronary stents. Am J Cardiol 1999;83(5):779-81.
8. Cantor WJ, Lazzam C, Cohen EA, Bowman KA, Dolman S, Mackie K, et al. Failed coronary stent deployment. Am Heart J 1998;136(6):1088-95.
9. Woodhouse JB, Uberoi R. Techniques for intravascular foreign body retrieval. Cardiovasc Intervent Radiol 2013;36(4):888-97.

10. Tsuchida M, Kawashiri MA, Uchiyama K, Sakata K, Nakanishi C, Tsubokawa T, et al. An enhanced device for transluminal retrieval of vascular stents without surgical procedures: experimental studies. J Interv Cardiol 2010;23(3):264-70.
11. Moussa ID, Bailey SR, Colombo A. Complications of Interventional Cardiovascular Procedures: A Case-Based Atlas. New York: Demos Medical; 2012.p.156-9.

How to cite this article:
Karakurt A, Başbuğ HS, Börekçi A, Bitargil M. Retrieval of a Stuck Coronary Stent with a Micro Snare: A Modified Employment of a Familiar Device. J Clin Anal Med 2014;5(suppl 3): 375-8.