Left Coronary Artery Originated from Right Sinus of Valsalva: Case Report

Sağ Sinüs Valsalvadan Çıkan Sol Koroner Arter: Vaka Takdimi

Sol Koroner Anomali / Left Coronary Anomaly

Kemal Karaağaç, Alkame Akgümüş, Fahriye Vatansever, Erhan Tenekecioğlu, Mustafa Yılmaz
Bursa Yuksek Ihtisas Education and Research Hospital, Cardiology Clinic, Bursa, Turkey

Özet

Tek bir koroner ostiumundan çıkan ve diğer koroner ostiumun olmadığı tek koroner arter (TKA) çoğunlukla asemptomatikdir. Bu konjenital anomalinin bazı tipleri göğüs ağrısı ve ani kardiyak ölüm gibi çeşitli klinik belirtilere neden olabilir. Biz tipik göğüs ağrısı nedeniyle koroner anjiyografi yapılan 50 yaşındaki bayan hastada ortaya çıkan izole TKA sunduk.

Anahtar Kelimeler

Koroner Damar Anomalisi; Anjina Pektoris; Koronar Arter Hastalığı

Abstract

The “single coronary artery” (SCA) arises from the aortic root by a single coronary ostium and in the absence of another ostium mostly has an asymptomatic course. Some types of this congenital anomaly may cause various clinical manifestations such as chest pain, sudden death. We present a 50-year-old woman whose coronary angiography for typical chest pain revealed an isolated SCA.

Keywords

Coronay Vessel Anomalies; Angına Pectoris; Coronary Artery Disease

DOI: 10.4328/JCAM.3270 Received: 27.01.2015 Accepted: 12.02.2015 Printed: 01.08.2014 J Clin Anal Med 2014;5(suppl 4): 446-8
Corresponding Author: Kemal Karaağaç, Kardiyoloji Kliniği, Bursa Yüksek İhtisas Eğitim ve Araştırma Hastanesi, Yıldırım, Bursa, Turkey.
T.: +90 2242605050 F.: +90 2243605055 E-Mail:drkaraagac2001@gmail.com

Introduction

Coronary artery anomalies occur in 0.2 -1.2% of the general population [1]. Clinical significance of such findings has been speculated and a few variants implicated as a cause of sudden death, especially in young athletes. The left main coronary artery arising from the right sinus of valsalva is found in 0.03% [2].

Case Report

A 50-year-old female patient was admitted to our polyclinic with exertional chest pain. She stated that the pain radiating to the left arm for the last 2 to 4 months and was starting after walking about 150 meters and was recovering with resting for 10 to 15 minutes. The patient had several coronary risk factors including age, smoking and hypertension. He had used Amlodipin for the last nine months. The patient's electrocardiogram was in sinus rhythm and rate was 75 beats/min; there were not any other features. There was no pathological finding detected in the patient's transthoracic echocardiography. 170/100 mmHg of blood pressure was measured on physical examination. The effort stress test was terminated and evaluated as symptom (chest pain)-positive at the end of the second stage of test. The patient underwent coronary angiography revealing a SCA originating from the right sinus of Valsalva and we could not demonstrate the significant narrowing of all the coronary artery (figüre 1,2). Beta-blocker and angiotensin converting inhibitor was added to her treatment. Our patient had typical chest pain, and the decision to administered surgery was made since there was no regression despite intensive medical treatment.

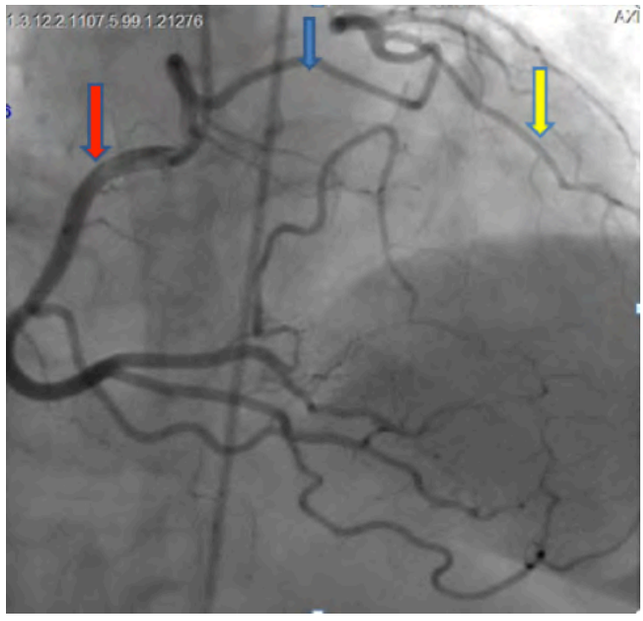

Figure 1. The left descending coronary artery (yellow arrow) and circumflex artery (blue arrow) does not originate from left coronary sinus, where it originates from the right coronary artery (red arrow).

Discussion

Coronary artery anomalies are quite rare, and discovered incidentally during coronary angiography or autopsy. Very infrequent type is a type in which all coronary artery systems are originated from one location [1].

Lipton classified single coronary artery anomalies angiographically according to the origin whether being right or left coronary artery, the anatomical distributions on ventricular surface and the relationship with the ascending aorta and the pulmonary artery. According to classification, in single coronary anomalies arose from right sinus of valsalva (that gives anomaly the first letter R), left system may originate from its distal after the natural course of right coronary artey (R-1 type) or may arise from the proximal root as an another artery (left main coronary artery R-2 type) or may bifurcate from proximal root as two different arteries, left anterior descending and circumflex (R-3 type) [3]. Our case was found to be consistent with R-3 type.

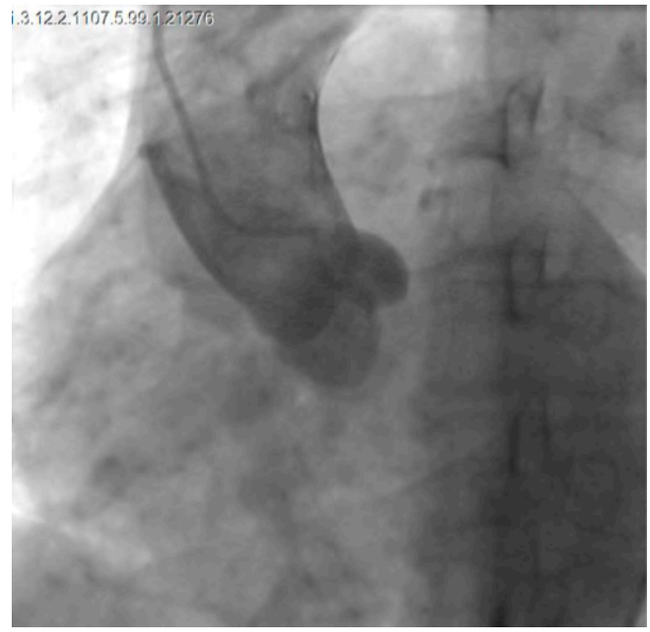

Figure 2. Aortography in the left anterior oblique view demonstrating absence of left coronary ostium in the left sinus of Valsalva.

The single coronary artery anomaly is usually asymptomatic, but may present as myocardial ischemia, syncope, or sudden cardiac death depending on its course and the presence and severity of atherosclerosis. Increased tendency of atherosclerosis have also been reported in cases with SCA anomalies [4]. Myocardial ischemia or sudden cardiac death are usually associated with its course between the aorta and main pulmonary artery [5]. The treatment strategy for SCA is not clear. The course and associated coronary atherosclerosis should guide the therapy. Coronary artery bypass surgery may be beneficial in patients whose anomalous coronary artery courses between the aorta and main pulmonary artery or/and patients with atherosclerosis may benefit from revascularization strategies. Successful percutaneous coronary intervention has also been reported in some cases [6,7].

In conclusion, SCA anomaly is a rarely, which may cause chest pain without atherosclerosis., The treatment strategy of SCA is still controversial and there are no studies comparing surgical with medical treatment and long-term follow-up studies are needed.

Competing interests

The authors declare that they have no competing interests.

References

1. Yamakama O, Hobbes RE. Coronary anomalies in 126,595 patients undergoing

coronary arteriography. Cathet Cardiovasc Diagn 1990; 21(1):28-40.
2. Fernendes ED, Kadivar H, Hallman GL, Reul GJ, Ott DA, Cooley DA. Congenital malformation of the coronary arteries: the Texas Heart Institute experience. Ann Thorac Surg 1992;54(4):732-40.
3. Lipton MJ, Barry WH, Obrez I, Silverman JF, Wexler L. Isolated single coronary artery: diagnosis, angiographic classification, and clinical significance. Radiology 1979;130(1):39-47.
4. Akgüllü Ç, Sural S, Eryılmaz U, Güngör H, Zencir C. Single Coronary Artery Anomaly Causing Chest Pain. Koşuyolu Heart Journal 2014;17(3):192-94.
5. Shirani J, Roberts WC. Solitary coronary ostium in the aorta in the absence of other major congenital cardiovascular anomalies. J Am Coll Cardiol 1993;21(1):137-43.
6. Raddino R, Pedrinazzi C, Zanini G, Leonzi O, Robba D, Chieppa F, et al. Percutaneous coronary angioplasty in a patient with anomalous single coronary artery arising from the right sinus of Valsalva. Int J Cardiol 2006;112(3):e60-2.
7. Karaağaç K, Özlük Ö, Yılmaz M, Arslan B, Topal D. Isolated Single Coronary Artery Originating From A Single Right Coronary Ostium in A Patient with Non ST-Segment Elevation Myocardial Infarction. Kocatepe Medical Journal 2013;14(3):154-6.

How to cite this article:
Karaağaç K, Akgümüş A, Vatansever F, Tenekecioğlu E, Yılmaz M. Left Coronary Artery Originated from Right Sinus of Valsalva: Case Report. J Clin Anal Med 2014;5(suppl 4): 446-8.