Traumatic Dissecting Aneurysm of Superficial Temporal Artery: A Case Report

Yüzeyel Temporal Arterde Travmatik Diseksiyon Anevrizması: Olgu Sunumu

Travmatik Diseksiyon Anevrizma / Traumatic Dissecting Aneurysm

Ali Riza Gezici[1], Yasar Dagistan[1], Kamil Gurel[2], Emine Dagistan[2], Nezih Ozkan[1]
[1]Neurosurgery, [2]Radiology, Abant Izzet Baysal University, Medical School, Bolu, Turkey

Özet

Süperfisial temporal arterin (STA) travmatik anevrizmaları çok nadir olarak oluşur. Burada, nadir görülen ve künt travmaya bağlı oluşan STA'nın diseksiyon anevrizması olgusunu sunduk. 22 yaşında erkek bir hasta sağ temporal bölgede ağrısız ve pulsatil tek bir şişlik şeklindeki kitle ile başvurdu. Sekiz ay önce kafatası'nda kırık olmaksızın sağ temporal bölge üzerinde izole travmatik bir yaralanması mevcuttu. STA'nın travmatik anevrizması tanısı koyuldu. Anestezi altında anevrizma komplet eksize edildi.

Anahtar Kelimeler

Süperfisial Temporal Arter; Travmatik Anevrizma; Cerrahi Eksizyon

Abstract

Traumatic aneurysms of the superficial temporal artery (STA) are a rare occurrence. Here, we report a very rare case of dissecting aneurysm of superficial temporal artery caused by blunt trauma. 22 year man, admitted with a solitary painless, pulsatile swelling in the right temporal region. 8 mounts ago, he had closed head injury over right temporal region without a skull fracture. A traumatic aneurysm of the STA was diagnosed. Under anesthesia, the aneurysm was completely excised.

Keywords

Superficial Temporal Artery; Traumatic Aneurysm; Surgical Excision

DOI: 10.4328/JCAM.3301 Received: 08.02.2015 Accepted: 25.02.2015 Printed: 01.08.2014 J Clin Anal Med 2014;5(suppl 4): 472-4
Corresponding Author: Yasar Dagistan, Abant Izzet Baysal University, Medical School, Bolu, Turkey.
T.: +90 3742534656 F.: +90 3742534615 E-Mail:dagistanyasar@hotmail.com

Introduction

Traumatic aneurysms (true or pseudo) of superficial temporal artery (STA) are a rare and most of the cases are caused by blunt trauma. Young men are predominantly affected. Symptoms usually develop 2–6 weeks after the initial injury [1,2]. The pseudoaneurysms are more common than true STA aneurysm [2,3]. In the English literature, there was a single case published as a dissecting aneurysm in STA and it was reported as a spontaneous dissecting aneurysm, not traumatic [4]. Most of the aneurysms of STA are on the anterior branch; the proximal STA or its posterior branch is more rarely affected [5].

Case Report

A 19-year-old gentleman presented with a solitary painless, pulsatile swelling in the right temporal region. 8 mounts ago, he had closed head injury over the right temporal region without a skull fracture. 2 months later the patient noticed gradually growing, painless pulsatile mass in this region. Also, the mass expanded when the patient coughed or exercised. On the examination, the mass was well defined, pulsatile, non-tender and measured about 2 cm x 1 cm (Fig. 1). The pulsations in the swelling diminished when pressure was applied proximally over the STA. He was investigated with Doppler USG, CT with contrast and selective external carotid angiography (ECA). Doppler USG confirmed the presence of blood flow and thrombus within the mass and diagnosis of the superficial temporal artery (STA) aneurysm (Fig. 2). ECA demonstrated a thrombosed 2-3 cm fusiform aneurysm with 7-8 mm intimal dissection flap, both the true and pseudo lumen, arising from parietal branch of the right STA (Fig. 3a-b).

Under local anesthesia, following the identification of the aneurysm and parent vessels with careful and meticulous dissection of the surrounding tissue, the proximal and distal parent vessels of the aneurysm were ligated; the aneurysm was completely excised (Fig. 4). Histologic examination exhibited the presence of intimal separation but there was no evidence of atherosclerosis.

Discussion

The mechanism underlying the development of an aneurysm is unknown but commonly is considered that injury leads to a dissection of the arterial wall. The pseudoaneurysm is characterized by complete or incomplete break in arterial wall, with subsequent hematoma formation. Eventually, lyses of the organized hematoma results in a connective tissue sac which communicates with arterial circulation. This leads to ongoing pseudo aneurismal expansion. Whereas, the development mechanism of traumatic true aneurysms may be different; the vessel walls usually are weakened by a trauma, without a break in the wall. So, the true aneurysms are localized or diffuse arterial dilations that all the layers of arterial wall are intact [6]. Also, weaknesses in a vessel wall in true aneurysms may be congenital or associated with atherosclerosis [7]. In this case,



Fig. 1. Small pulsatile mass at the right temporal scalp (arrow)

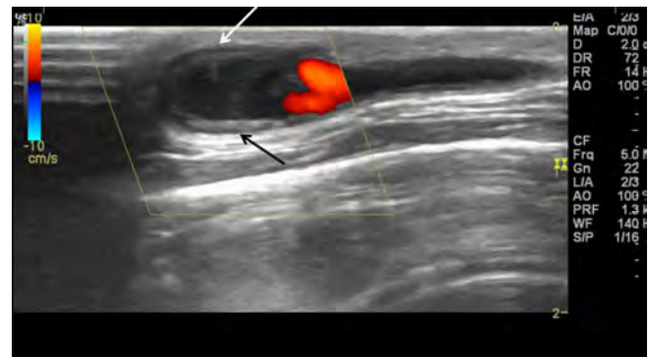

Fig. 2. Doppler view demonstrating thrombus and flow (red color) within the aneurysm

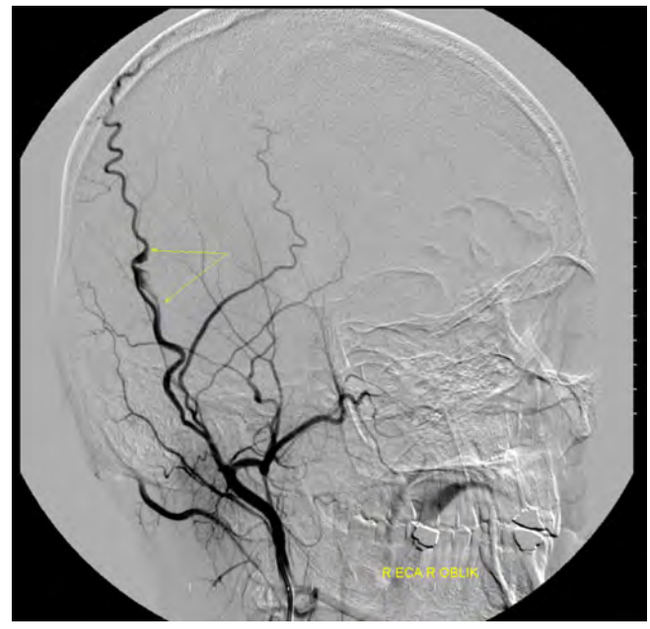

Fig. 2. Doppler view demonstrating thrombus and flow (red color) within the aneurysm

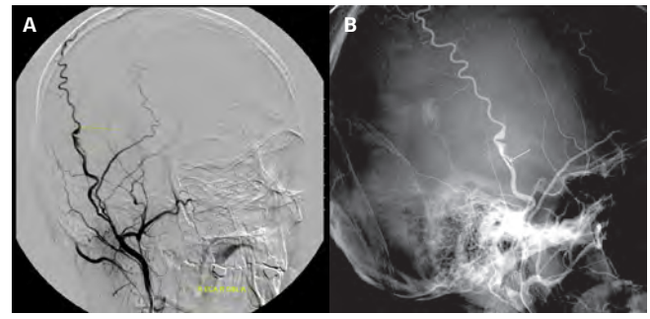

Fig. 3. The fusiform aneurysmal dilatation of parietal branch of superficial temporal artery (arrows) is seen on right external carotid artery injection image obtained in right oblique projection(A). The intimal flap is clearly seen within the fusiform aneurysmal dilatation of superficial temporal artery (arrow) on native image of right external carotid artery injection obtained in lateral projection (B).

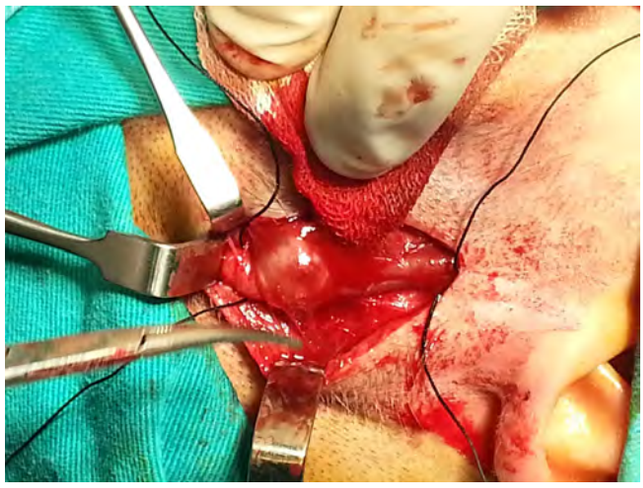

Fig. 4. View of the aneurysm excised.

the trauma probably leads to injury the intimal layer and then separation of the intimal layer from the media. So, consisting of the fusiform aneurysm may be considered a pseudo aneurysm.

These aneurysms may have visible or palpable pulsations as a consequence of a progressive dilatation of damaged arterial wall. But sometimes cause of complete thrombosis of the aneurismal sac, pulsations may be absent. Therefore, the differential diagnosis should be made from a sebaceous cyst, lymphadenopathy, lipoma, arteriovenous fistula, simple haematoma, neuroma of the supra orbital nerve or an abscess [2,8].

The time from injury to detection of aneurysm diagnosis is approximately 2-6 weeks [2,8]. The most common presenting symptom is a pulsatile, constantly increasing mass at the temporal-parietal region accompanied by a throbbing headache [9]. The history and physical examination supported by Doppler USG evaluation are often sufficient to make the diagnosis of STA aneurysms. Other imaging techniques such as CT with contrast, CT and MRI angiography may be necessary in cases where intracerebral aneurysms are suspected [5]. Also; conventional angiography may be reserved for diagnosis of more complicated cases or endovascular treatment.

Although STA aneurysms have a relatively benign course, life-threatening hemorrhages also have been reported [7,10]. Therefore, when a STA aneurysm is diagnosed, surgery is recommended. Accepted other indications for surgery are pain, rapidly increasing size and cosmetic problems.

Superficial temporal artery aneurism treatment options may be divided into tree section; conservative approach, endovascular embolization and surgical excision. Intermittent compression technique can be used for small aneurysms, but usually results in failure [11]. The endovascular techniques, in regions less accessible to surgical intervention can be used. Also direct embolic or thrombotic agent injection into the aneurysm is a simple method, but complications, such as an allergic reaction, risk of re-canalization, intravascular thrombosis, scalp necrosis and a distal ischemia have been reported. Currently, standard surgery remains the definitive treatment and includes ligation of the afferent and efferent vessels of STA, followed by lesion excision under local anesthesia [8]. Vascular supply is very rich in this area and therefore reconstructions of the vessels are not necessary. The standard surgical procedure is simple and effective with no reported recurrences.

Competing interests

The authors declare that they have no competing interests.

References

1. Inoue Y, Iwamoto T, Kitoh M, Yoshimura K, Ono T. Traumatic aneurysm of the temporal artery: a report of five cases. J Dermatol 1997;24(4):246-8.
2. Evans CC, Larson MJ, Eichhorn PJ, Taylor RS. Traumatic pseudoaneurysm of the superficial temporal artery: two cases and review of the literature. J Am Acad Dermatol 2003;49(5):S286–8.
3. Johnston KW, Rutherford RB, Tilson MD, Shah DM, Hollier L, Stanley JC. Suggested standards for reporting on arterial aneurysms. Subcommittee on Reporting Standards for Arterial Aneurysms, Ad Hoc Committee on Reporting Standards, Society for Vascular Surgery and North American Chapter, International Society for Cardiovascular Surgery. J Vasc Surg 1991;13(3):452-8.
4. Fujii S, Kajikawa H, Yamamura K, Wada M, Shimamoto F. Spontaneous dissecting aneurysm of the superficial temporal artery: a case report. No Shinkei Geka 1995;23(9):797-800.
5. Conner WC III, Rohrich RJ, Pollock RA Traumatic aneurysms of the face and temple: a patient report and literature review, 1644 to 1998. Ann Plast Surg 1998;41(3):321–6.
6. Ysa A, Arruabarrena A, Bustabad MR, Perez E, del Campo A, Garcia-Alonso J. Images in vascular medicine. True aneurysm of the superficial temporal artery. Vasc Med 2008;13(3):295-6.
7. Pipinos II, Dossa CD, Reddy DJ. Superficial temporal artery aneurysms. J Vasc Surg 1998;27:374–7.
8. Park SK, Bong HJ, Jang DK, Yoon WS, Han YM, Jang KS. Traumatic true aneurysm of the superficial temporal artery. Aesthetic Plast Surg 2012;36(4):934-7.
9. Lewis EC 2nd, Southwick EG. Aneurysm of the superficial temporal artery. Arch Dermatol 1978;114(4):587-8.
10. Uchida N, Sakuma M. Atherosclerotic superficial temporal artery aneurysm: report of a case. Surg Today 1999;29(6):575-8.
11. Myer CM 3rd, Donegan JO. Traumatic aneurysm of the proximal superficial temporal artery. Head Neck Surg 1982;5(2):181-5.

How to cite this article:
Gezici AR, Dagistan Y, Gurel K, Dagistan E, Ozkan N. Traumatic Dissecting Aneurysm of Superficial Temporal Artery: A Case Report. J Clin Anal Med 2014;5(suppl 4): 472-4.