Iliac Artery and Vein Injury Without Pelvic Fracture Due To Blunt Trauma: A Rare Case

Künt Travmaya Bağlı Pelvis Kırığı Olmaksızın İliak Arter ve Ven Yaralanması: Nadir Bir Vaka

İliak Damar Yaralanması / Iliac Vascular Injury

Mustafa Cüneyt Çiçek[1], Ömer Faruk Çiçek[1], Kanber Karakurt[2], Barış Çankaya[3]
[1]Department of Cardiovascular Surgery, Turkiye Yuksek Ihtisas Educational and Research Hospital, Ankara,
[2]Department of Emergency Medicine, Nevşehir State Hospital, Nevşehir,
[3]Department of Anesthesiology, Nevşehir State Hospital, Nevşehir, Turkey

Özet

İliak damar yaralanmaları yüksek morbidite ve mortalite ile ilişkilidir. Penetran abdominal ve pelvik vasküler yaralanmalar künt travmalara göre daha sıktır. Künt pelvik damar yaralanmalarına çoğunlukla pelvis kırığı eşlik eder. 23 yaşında erkek hasta motor kazası sonrası acil servisimize kabul edildi. Şok tablosunda olan hastada sol femur şavt kırığı vardı ve yapılan Doppler ultrasonografide arteryel ve venöz akım izlenmedi. Hasta acil olarak operasyona alındı. Sol ana iliak arter ve ven normaldi fakat eksternal iliak ven iki yerinden lasereydi, sol external iliak arterin ise bir yerinde damar duvar bütünlüğü bozulmuştu. Sunulan olguda künt travmaya bağlı pelvis kırığı olmaksızın iliak arter ve ven yaralanmasının klinik prezentasyonu ve travmatik retroperitoneal hematom yönetimi tartışılmaktadır.

Anahtar Kelimeler

İliak Arter; İliak Ven; Vasküler Travma; Künt Travma

Abstract

Iliac vascular injuries have high morbidity and mortality rates. Penetrant abdominal and pelvic vascular injuries are more common compared to blunt traumas. Pelvic vascular injuries associated with blunt trauma are quite likely to occur in accompaniment with pelvic fracture. A 23 year old male patient was admitted to the emergency room due to a motorcycle accident. Shock picture was prevalent in the patient. Shaft fracture was present in left femur and flow was not detected in arterial and venous colour Doppler ultrasonography. Patient underwent emergency surgery. Left main iliac artery and vein were normal, however, external iliac vein was lacerated in two spots, and blood vessel wall integrity was damaged in one part of left external iliac artery. Clinical presentation and traumatic retroperitoneal hematoma management of iliac artery and venous injuries due to blunt trauma without pelvic fracture are discussed in the presented case.

Keywords

Iliac Artery; Iliac Vein; Vascular Trauma; Blunt Injury

DOI: 10.4328/JCAM.3319 Received: 16.02.2015 Accepted: 04.03.2015 Printed: 01.08.2014 J Clin Anal Med 2014;5(suppl 4): 487-9
Corresponding Author: Ömer Faruk Çiçek, Department of Cardiovascular Surgery, Türkiye Yüksek İhtisas Educational and Research Hospital, 06100, Ankara, Turkey.
GSM: +905057721661 E-Mail: farux@hotmail.com

Introduction

Iliac vascular injuries associated with abdominal and pelvic traumas may cause severe outcomes. Mortality rates in iliac vascular injuries are between 30-50% [1]. The most significant factors affecting mortality are blood loss and related shock, accompanying injuries, and the time between the injury and operation [2,3]. While failure to perform sufficient compression to the bleeding vein in preoperative period, and isolation and difficulty of control resulting from the retroperitoneal course of iliac veins along with hematoma in intraoperative period render the bleeding control problematic and make the shock picture more severe [4]. Abdominal and pelvic vascular injuries may occur as blunt, penetrant, and iatrogenic. In literature, penetrant abdominal and pelvic vascular injuries are more common compared to blunt traumas [5]. Pelvic vascular injuries associated with blunt trauma are quite likely to occur in accompaniment with pelvic fracture [6]. Clinical presentation and traumatic retroperitoneal hematoma management of iliac artery and venous injuries without blunt trauma-associated pelvic fracture are discussed in the presented case.

Case Report

A 23-year-old male patient was admitted to the emergency room of our hospital from an epicentre 6 hours after a motorcycle accident. Blood pressure of the patient was 60/40 mmHg, pulse was 140 beats per minute and respiration was tachypneic. Shock picture was prevalent in the patient. Physical examination revealed diameter increase and ecchymosis in the left thigh without sensory or motor deficits. The same extremity was slightly cold and femoral pulse was absent. However, there was no clinically significant leg compartment syndrome. Abdominal examination was normal. When checked the laboratory results, hemoglobin; 6.5 g/dl, hematocrit: 19.4. Transthoracic echocardiography revealed no evidence of cardiac tambonade and cardiac or great vessel injuries. No fractures were observed in chest, spinal, and pelvic plain radiographs. Shaft fracture was present in left femur. Flow was not detected in arterial and venous colour Doppler ultrasonography conducted in emergency situations. Solid organ traumas were not detected in tomography. However, hematoma was present in retroperitoneal region (Figure 1).



Figure 1. Admission computerized tomography scan shows perivascular hematoma (arrow).

Patient underwent cardiac arrest in early preoperative period, but patient was resuscitated effectively and then taken to operation room. Undergoing a shock picture, patient was planned to conduct retroperitoneal hematoma exploration carried out under emergency conditions without further tests. Median laparotomy was performed under the umbilicus. No findings were established in favour of hematoma or solid organ damage. When the incision was extended to the left side, diffuse hematoma was observed in retroperitoneum. Left main iliac artery and vein were normal, however, external iliac vein was lacerated in two spots, and blood vessel wall integrity was damaged in one part of left external iliac artery (Figure 2). Lacerations in

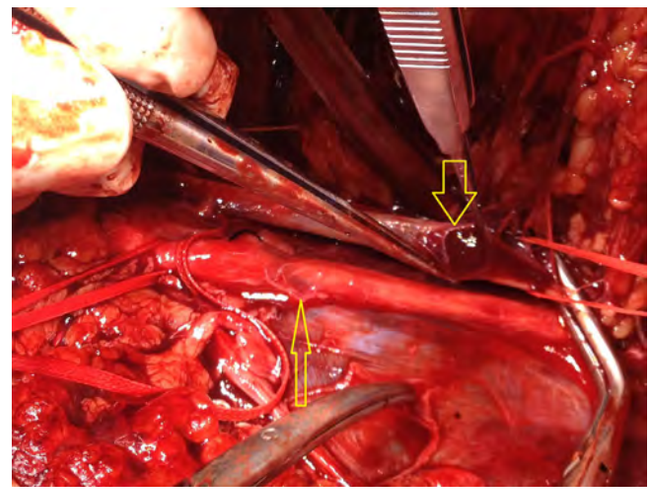

Figure . Intraoperative photograph shows the arterial hematoma (thin arrow) and venous laceration (thicker arrow).

left external iliac vein were found in two spots with a longitudinal course of 1cm consecutively and 0.5 cm in length. In one spot of left external iliac artery, blood vessel wall structure was observed to damage in a segment of around 1cm and blood was extravasating from this segment. When incision was extended to the femoral region, femoral artery and vein were observed to be intact. Bleeding was brought under control with the help of vascular clamps placed on proximal and distal of both iliac arteries. The segment of 1cm where iliac artery was lacerated was excised and end-to-end anastomosis was conducted. Then, defect in iliac vein was repaired by continuous suture technique. The operation was uneventful despite the urgent need for intervention. Following bleeding control, anatomic layers were closed accordingly and the patient was then taken to intensive care unit. Flow in femoral artery and vein was observed in bedside colour Doppler ultrasonography and vital signs were normal. However, the patient went into cardiac arrest at the postoperative first hour and died despite resuscitation.

Discussion

Mortality and morbidity of iliac vascular injuries are quite high in spite of advanced surgical techniques and developments in intensive care today. Iliac artery injuries generally occur due to penetrating injuries [5]. Iliac artery and vein injuries were demonstrated in many series along with pelvic fracture [6]. In this sense, the presented case was a rare condition in which iliac artery and vein got injured together due to blunt trauma but pelvic fracture was non-existent.

Approach to trauma-related retroperitoneal hematoma is still controversial as it was in the past. Retroperitoneal hematoma due to blunt trauma generally occurs in association with pel-

vic fracture [7]. Although mostly in pelvic and presacral veins, the source of haemorrhage can also be in major iliac artery or in branches of veins. In pelvic hematomas due to such traumas, external pelvic fixation, spontaneous tamponade and angiographic embolization approaches may be preferable. Certain exceptions to these conservative approaches were presented in a list by Feliciano. These are pelvic fracture-associated severe blood losses, hematomas through open wounds, suspected or proven major vascular injuries [8].

When the patient in the reported case was evaluated initially at the emergency room, iliac vein or arterial injury was not considered at first since the patient had femoral shaft fracture and associated hematoma in thighs. Therefore, femoral artery and/or venous injury was believed in the foreground as responsible for the current clinical picture. Due to the presence of retroperitoneal hematoma in tomography and the unstable condition of the patient, retroperitoneal exploration was decided without further tests.

While in patients that are clinically suspected to have had arterial injuries arteriography is recommended if haemodynamics is stable, it is contra-indicated in patients that are not stabilized. In such cases, duplex ultrasonography may be useful [9].

Numerous studies suggest that the time from the injury till the operation depending on the degree of major abdominal artery or venous injuries is quite critical and that it leads the factors affecting prognosis [10]. Bearing in mind the commencement of effectively fighting with shock and that diagnosis is made in major vascular injuries intraoperatively following the admittance of patient, it is life-saving to conduct emergency operation and exploration of the injured vessel by surgeon especially in cases with unstable vital signs, and also the restoration of haemostasis and critical blood flow without wasting any time.

Emergency surgical reparation is indicated following the diagnosis of major vascular injury. Mostly primary repair is suggested in literature as approaches to vascular injuries [2]. We, too, excised the dissected section of 1 cm of the iliac artery and conducted end-to-end anastomosis in our case. In continuation, we preferred primary restoration of the lesional wall of iliac vein.

There are studies reporting viewpoints on the ligation as an alternative to the reparation of bleeding artery or vein. Surgeon needs to bear in mind all the risks including ischemia that may develop when preferring ligation. All infrarenal veins can be ligated. Some studies reported that peripheral edema was observed quite low following the ligation of vena cava on infrarenal level [11,12]. In a study by Dubose et al. [13] conducted on 61 cases, ischemic complications were not observed among unstable patients with pelvic fracture and bleeding who survived following bilateral ligation and pelvic packing or internal iliac artery embolization practices.

To sum up, iliac vascular injuries without pelvic fracture due to blunt trauma are rare but high-mortality conditions. In such rare injuries, surgeons should expect quite remarkable difficulties during diagnosis, in surgical approaches, and in postoperative follow-ups. Especially in diagnosis, vascular or trauma surgeons need to be a little bit sceptical while evaluating the patient and to keep in mind the possibility of iliac vascular injuries at all times.

Competing interests

The authors declare that they have no competing interests.

References

1. Asensio JA, Petrone P, Roldán G, Kuncir E, Rowe VL, Chan L, et al. Analysis of 185 iliac vessel injuries: risk factors and predictors of outcome. Arch Surg 2003;138(11):1187-93.
2. Mullins RJ, Huckfeldt R, Trunkey DD. Abdominal vascular injuries. Surg Clin North Am 1996;76(4):813-32.
3. Bedirli A, Sözüer EM, Şakrak Ö,Yılmaz Z, Kerek M. Major abdominal vascular injuries. Ulusal Travma Dergisi 1999;2:116-9.
4. Degiannis E, Velmahos GC, Levy RD, Wouters S, Badicel TV, Saadia R. Penetrating injuries of the iliac arteries: a South African experience. Surgery 1996;119(2):146-50.
5. Burch JM, Richardson RJ, Martin RR, Mattox KL. Penetrating iliac vascular injuries: recent experience with 233 consecutive patients. J Trauma 1990;30(12):1450-9.
6. Moreno C, Moore EE, Rosenberger A, Cleveland HC. Hemorrhage associated with major pelvic fracture: a multispecialty challenge. J Trauma 1986;26(11):987-94.
7. Goins WA, Rodriguez A, Lewis J, Brathwaite CE, James E. Retroperitoneal hematoma after blunt trauma. Surg Gynecol Obstet 1992;174(4):281-90.
8. Feliciano DV. Management of traumatic retroperitoneal hematoma. Ann Surg 1990;211(2):109-23.
9. McDonald EJ Jr, Goodman PC, Winestock DP. The clinical indications for arteriography in trauma to the extremity. A review of 114 cases. Radiology 1975;116(1):45-7.
10.Feliciano DV, Burch JM, Graham JM: Abdominal vascular injury. In Mattox LK, Feliciano DV, Moore EE (eds): Trauma. New York. McGraw-Hill,2000, pp 783-805.
11. Sullivan PS, Dente CJ, Patel S, Carmichael M, Srinivasan JK, Wyrzykowski AD, et al. Outcome of ligation of the inferior vena cava in the modern era. Am J Surg 2010;199(4):500-6.
12. Oliver JC, Bekker W, Edu S, Nicol AJ, Navsaria PH. A ten year review of civilian iliac vessel injuries from a single trauma centre. Eur J Vasc Endovasc Surg 2012;44(2):199-202
13. DuBose J, Inaba K, Barmparas G, Teixeira PG, Schnüriger B, Talving P, et al. Bilateral internal iliac artery ligation as a damage control approach in massive retroperitoneal bleeding after pelvic fracture. J Trauma 2010;69(6):1507-14.

How to cite this article:
Çiçek MC, Çiçek ÖF, Karakurt K, Çankaya B. Iliac Artery and Vein Injury Without Pelvic Fracture Due To Blunt Trauma: A Rare Case. J Clin Anal Med 2014;5(suppl 4): 487-9.