Triple Primary Malignancies of Thyroid and Larynx in a Case of Retrosternal Guatr

Retrosternal Guatrlı Bir Olguda Tiroid ve Larinksin Üçlü Primer Malignitesi

Üçlü Primer Malignite / Triple Primary Malignancies

Seval Erhamamcı[1], Mehmet Reyhan[1], Nazım Emrah Kocer[2], Tuba Canpolat[2], Naime Altınkaya[3]
[1]Department of Nuclear Medicine, [2]Department of Pathology, [3]Department of Radiology,
Faculty of Medicine, Baskent University, Ankara, Turkey

Özet

Tiroid bezi ve larinks baş boyun kanserlerinin en sık lokalizasyonudur. Ancak, tiroid ve larinks kanserlerinin birlikte görülmesi nadirdir ve literatürde sınırlı sayıda vaka bildirilmiştir. Bu yazıda, retrosternal guatrlı bir olguda eşzamanlı papiller ve foliküler tiroid kanseriyle birlikte metakron larinks squamöz hücreli karsinomlu nadir bir kombinasyonu sunduk. 71 yaşındaki erkek olguya retrosternal guatr nedeniyle total tiroidektomi yapıldı. Histolojik inceleme aynı lobun iki farklı odağında papiller ve foliküler tiroid karsinomunu gösterdi. Hasta eşzamanlı tiroid karsinomu tanısından 16 ay sonra ses kısıklığı şikayeti ile başvurdu, biyopsi ile larinks squamöz hücreli karsinom tanısı aldı, bilateral boyun diseksiyonu ile birlikte total larenjektomi ve ardından kemoradyoterapi uygulandı. Hasta şu anda bu üç kanserden tam remisyondadır.

Anahtar Kelimeler

Foliküler Tiroid Karsinomu; Papiller Tiroid Karsinomu; Larinks Karsinomu; Çoklu Primer Malignite

Abstract

The thyroid gland and larynx are the most common sites for head and neck cancers. However, the co-existence of thyroid and laringeal tumors are rare, and there have been limited reports in the literature. In this paper, we present an unusual combination of simultaneous papillary and follicular thyroid carcinoma associated with metachronous laryngeal squamous cell carcinoma in a case with retrosternal guatr. A 71 year-old man who had undergone a total thyroidectomy due to a retrosternal guatr. Histological examination revealed papillary thyroid carcinoma and follicular thyroid carcinoma in two separate foci of the same thyroid lobe. Sixteen months after the diagnosis simultaneous thyroid carcinomas, the patient was admitted with complained of hoarseness, diagnosed laryngeal squamous cell carcinoma by biopsy, and underwent total laryngectomy with bilateral neck dissections and following chemoradiotherapy. The patient is currently in complete remission from these triple cancers.

Keywords

Follicular Thyroid Carcinoma; Papillary Thyroid Carcinoma; Laryngeal Carcinoma; Multiple Primary Carcinoma

DOI: 10.4328/JCAM.3348 Received: 27.02.2015 Accepted: 23.03.2015 Printed: 01.08.2014 J Clin Anal Med 2014;5(suppl 4): 511-4
Corresponding Author: Seval Erhamamcı, Baskent University Faculty of Medicine, Saray Street No. 1, 42080: Selcuklu, Konya, Turkey.
T.: +90 3322570606 F.: +90 3322570637 E-Mail: sevaler@yahoo.com

Introduction

The thyroid gland and larynx are the most common sites for head and neck malignancies. The presence of multiple primary cancers in the head and neck region are not uncommon because the patients with upper aerodigestive tract squamous cell carcinomas are generally smokers and have a high risk of developing other cancers in the smoke-exposed mucosa simultaneously or subsequently. However, the co-existence of thyroid and laringeal tumors rare event, and small series of thyroid carsinoma associated with laryngeal lesions have been reported in the literature [1-6]. Thyroid carcinomas occuring as a second primary malignancy (SPM) have been reported to be incidentally in 0.5% to 3% of surgeries for another primary head and neck cancer of non-thyroid origin [1]. Increasing incidence and good prognosis of thyroid cancer have led to increased the development of SPM [2]. Second primary cancers in patients with differentiated thyroid carcinoma (DTC), especially laringeal carcinoma are relatively rare, and limited number of cases have been described [2-6]. A triple presentation of thyroid and laryngeal malignancies in the same patient is also very rare.

Various combinations of thyroid carcinomas has been reported [7-8]. The clinical information on simultaneous occurrence of follicular thyroid carcinoma (FTC) and papillary thyroid carcinoma (PTC) is insufficient in the literature, because these two tumors are traditionally reported together as DTC. Concurrent presence of PTC and FTC has been published limitedly as case reports although one study has been presented recently [7].

In this paper, we present an unusual combination of simultaneous PTC/FTC associated with laryngeal squamous cell carcinoma in a case with retrosternal guatr and also carry out a review of the literature.

Case Report

A 70-year-old male patient presented with the history of swelling in front of the neck and dyspnea. Computed tomography of the neck demonstrated a retrosternal thyroid nodule in the left lob in size of about 7 cm, displacing the trachea and esophagus on right side of patient's (Fig. 1). The patient had a 44-year history of smoking cigarettes and of no alcohol consumption. The patient displayed subclinical hyperthyroidism as evidenced normal free triiodothronine and free thyroxine, and low thyroid stimulating hormone (TSH) (0.146 µU/mL, normal range: 0.36-4.94) in a serum thyroid function test. Haematological and biochemical investigations were within normal limits.

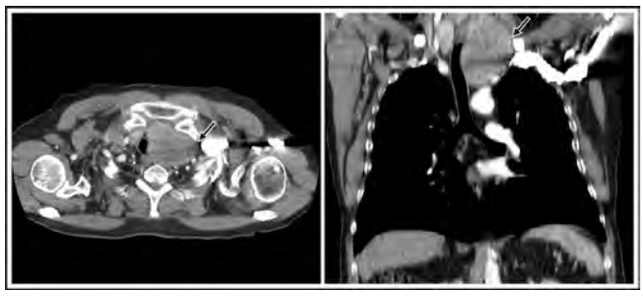

Figure 1. Contrast-enhance computed tomography findings axial and coronal MPR image demonstrated a retrosternal thyroid nodule in the left lob in size of about 7 cm, displacing the trachea and esophagus to the patient's right (arrow).

The patient underwent a bilateral total thyroidectomy. Histological examination revealed PTC (Fig. 2A) in size of 1.2 cm with another focus showing features of FTC (Fig. 2B) in size of 7 cm in the left lobe. The FTC and PTC components were separated by normal thyroid tissue. FTC was defined Hurthle-cell varyant and classified as minimally invasive. The patient presented no lymph node or distant metastases at the time of initial presentation.

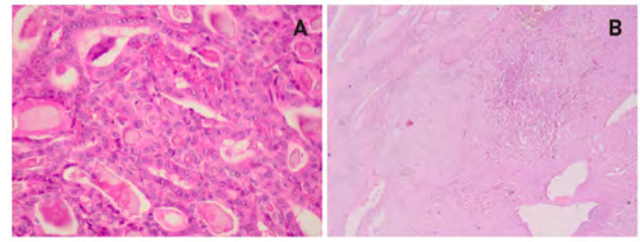

Figure 2. Papillary carcinoma (A): The microphotograph reveals follicles composed of overlapping cells with ovaloid vesicular nuclei. Nuclear grooves and intranuclear pseudoinclusions are present. Note the presence of dense and scalloped colloid in the elongated follicles lümen (hematoxylin and eosin stain, original magnification x400). Follicular carcinoma (B): Oncocytic cells invasing throughout the fibrous capsule (hematoxylin and eosin stain, original magnification x400).

RAI treatment was carried out at a dose of 100 mCi (3700 MBq) for the ablation of residual thyroid tissue. A post-therapy scan was obtained 10 days after RAI therapy (Fig 3A). After RAI ablation, the patient would have a whole body scan (WBS) at 6th months to confirm the success of ablation (Fig 3B). The patient received suppressive doses of thyroxine to maintain serum TSH concentration suppressed to undetectable levels (<0.15 mIU/l) and was follow-up at 6-and 12-months intervals. Patient was out-patiently monitored annually in accordance with a standardized follow-up protocol including clinical examination, ultrasonography of the neck and biochemical measurements of

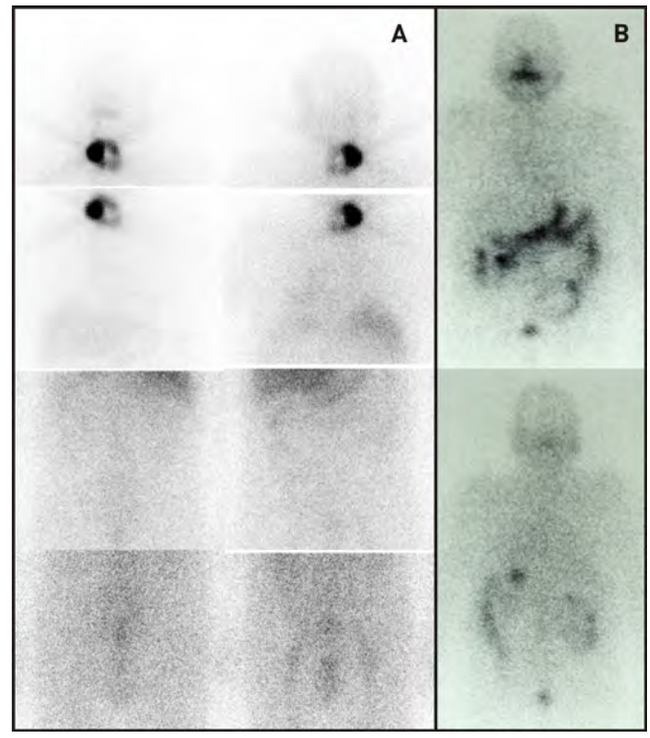

Figure 3. After RAI therapy, a post-therapy scan at 10 days showed residual thyroid tissue (A) and whole body scan at 6th months confirmed the success of ablation (B).

thyroglobulin levels.

Sixteen months after the diagnosis of simultaneous thyroid carcinomas, the patient complained of hoarseness. Computed tomography of the neck demonstrated a mass in the the right side of larynx, infiltrating into both the vocal cords, and right thyroid, cricoid and aritenoid cartilages (Fig. 4). Biopsy of the

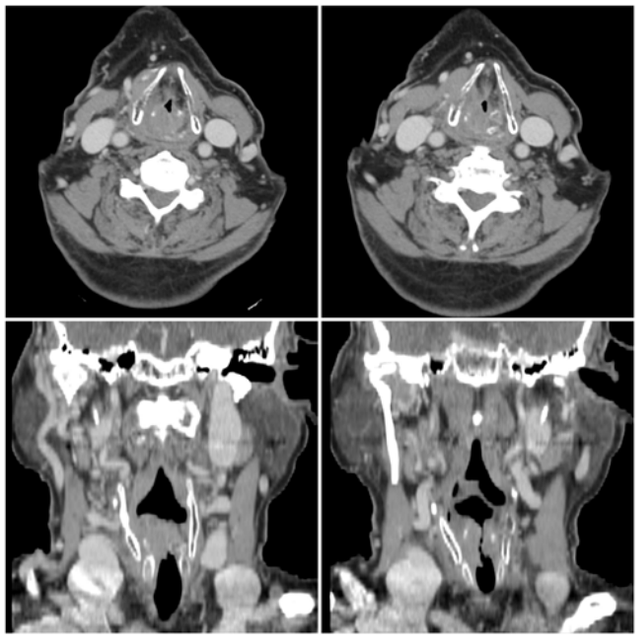

Figure 4. Contrast-enhance computed tomography of the neck demonstrated a mass in the the right side of larynx, infiltrating into both the vocal cords, and right thyroid, cricoid and aritenoid cartilages (arrows).

larynx revealed the presence of the squamous cell carcinoma. The patient underwent total laryngectomy with bilateral neck dissections for a pathological stage T4aN0M0 squamous cell carcinoma (SCC) of the larynx (Fig. 5). Histopathologic exami-

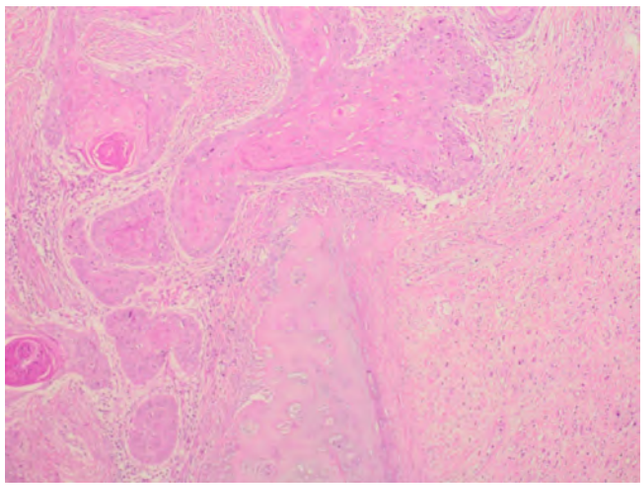

Figure 5. Squamous cell carcinoma infiltrating the epiglot cartilage (hematoxylin and eosin stain, original magnification x100).

nation of the surgical specimen revealed that the surgical margins were negative, invasion of the thyroid cartilages, and no metastases in lymph node.

After the total laryngectomy, a positron emission tomography (PET/CT) whole body scan (Discovery-STE 8; General Electric Medical System, Milwaukee, Wisconsin, USA) was performed to evaluate other possible metastases. No abnormal 18F-fluorodeoxyglucose (FDG) uptake was detected elsewhere in the body, except irreguarly increased metabolic activity in the larynx due to surgery (Fig. 6).

The patient underwent chemoradiotherapy. He is currently in complete remission from these cancers.

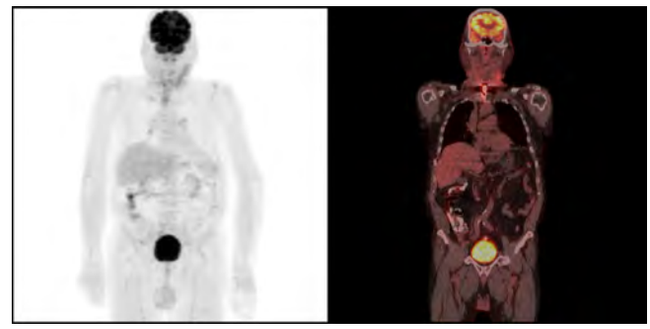

Figure 6. Maximum intensity projection and coronal fusion PET/CT images showed no abnormal FDG uptake elsewhere in the body, except irreguarly increased metabolic activity in the larynx due to surgery.

Discussion

Technical advances in early diagnosis and treatment of cancer, the incidence of multiple primary cancers has recently increased. In patients with thyroid carcinoma, the incidence of synchronous or metachronous multiple primary cancers including head and neck carcinoma and elsewhere in the body (ie, breast, prostate, kidney, brain and CNS, salivary gland, and bone marrow) has increased [2].

Thyroid carcinomas are rare tumors with the range of 1% of all malignancies, but DTC is the most frequent endocrine gland carcinomas. Of the two main subtypes, PTC and FTC account for approximately 90% of cases, derived from the same follicular thyroid cell lineage, had a similar clinical behaviour. Thyroid cancer has been increasing rapidly over recent decades due to increased cervical ultrasound and increased detection in pathological specimens. This increase has been predominantly an increase in PTC, more specifically an increase in papillary thyroid microcarcinoma.

Cases of the simultaneous occurrence of different types of primary thyroid cancer in the same gland have been reported [7,8]. However, there is insufficient clinical information concerning simultaneous existence of FTC and PTC. Only a recent study has been reported that the frequency of concurrent PTC in patients with FTC was 19% [7]. Simultaneous existence of different types of primary thyroid cancer in the same patient have been reported as usually independent and coincidental events [7,8]. Wong et al. reported that one tumor is often discovered primarily in simultaneous thyroid tumors patients, with the second tumor found incidentally after thyroidectomy [8]. In our patient, simultaneous thyroid tumors were discovered incidentally due to the symptoms related to retrosternal guatr.

Upon reviewing the literature, the synchronous or metachronous occurrence of thyroid and laryngeal tumors in the same patients is observed in two main settings: thyroid cancer occuring as the first primary malignancy or SPM. Thyroid carcinoma occurring as a SPM associated with head and neck squamous cell carcinoma is unusual, and can be discovered as palpable thyroid mass during neck surgery, as an occult carcinoma in the thyroid gland removed during laryngectomy or as thyroid can-

cer that is found in lymph nodes of the neck dissection specimen [1].

The prevalence of dual malignancies in patients with DTC was reported to be 0.45-0.5% [3,4]. Okere et al. reported one case of larinx cancer as second primary thyroid carcinoma among 4500 patients with DTC [3]. This case was diagnosed as insular type thyroid carcinoma 19 years after the detection of laryngeal carcinoma. Gandhi et al. reported one case with synchronous thyroid and larynx carcinoma among 8614 patients with DTC [4]. Omur et al. described two cases with concurrent papillary thyroid carcinoma and laryngeal carcinoma among 1680 patients with DTC [5]. In these two cases, thyroid carcinoma was incidentally discovered during the operation performed for laryngeal carcinoma. Verkooijen et al. reported high rates of two or three primary tumors (14.2%, 40 out of 282) in patients with DTC, but none of them had laryngeal carcinoma [6].

Increasing incidence and good prognosis of thyroid cancers have led to concerns about the development of SPM. Previous studies reported that the patients with treated I-131 may face a slightly increased risk of developing a SPM [2]. However, other investigators stated that overall increased incidence of SPM after DTC could be explained by shared genetic or environmental risk factors rather than I-131 radiation effect [6]. In the literature, occurrence of SPN in patients with treated for malignant thyroid carcinomas has been reported [2-6]. Most of SPM are solid tumors, and when nonthyroid cancers are the second tumors, ductal carcinoma of the female breast is the most common [3-6]. Recently, a study reported that the most common sites of SPM are head and neck in men and breasts in women [4]. Most of these tumors have very short detection intervals (including synchronous occurrences), suggesting that therapy with internal radiation was not contributory to the tumor development. Our patient had simultaneous PTC/FTC as a the first primary malignancy and was diagnosed as LSCC 16 months after diagnosis simultaneous thyroid carcinomas. Therefore, in our case, RAI treatment is not related to in the occurrence of LSCC.

The standard treatment for DTC is total or near-total thyroidectomy followed by radioiodine-131 (I-131) ablation therapy for residual or metastatic disease. Differentiated thyroid carcinoma is usually characterized by an indolent course in the majority of patients; 10-year survival rates are approximately 90%. Some reports have indicated that the DTC are related to the prognosis of SPM [5]. Therefore, quick diagnosis and treatment of SPM are essential to the prognosis of patients. The clinical course of DTC has been reported not to be affected by the presence of additional primary tumors [5].

In conclusin, multiple primary malignancies including thyroid and larinx is infrequent, and any reported similar case is of great interest as a guide to better assessment of the outcome of these patients and it is important to understand the causative factors of multiple malignancies.

Competing interests

The authors declare that they have no competing interests.

References

1. Gilbert MR, Kim S. Incidental thyroid cancer found during surgery for head and neck squamous cell carcinoma. Otolaryngol Head Neck Surg 2012;147(4):647-53.
2. Kim C, Bi X, Pan D, Chen Y, Carling T, Ma S et al. The risk of second cancers after diagnosis of primary thyroid cancer is elevated in thyroid microcarcinomas. Thyroid 2013;23(5):575-82.
3. Okere PC, Olusina DB, Shamim SA, Shandra V, Tushar M, Sellam K et al. Pattern of second primary malignancies in thyroid cancer patients. Niger J Clin Pract 2013;16(1):96-9.
4. Gandhi S, Abhyankar A, Basu S. Dual malignancies in the setting of differentiated thyroid carcinoma: their synchronous or metachronous nature, impact of radioiodine treatment on occurrence of second malignancy and other associated variables. Nucl Med Commun 2014;35(2):205-9.
5. Omür O, Ozcan Z, Yazici B, Akgün A, Oral A, Ozkiliç H. Multiple primary tumors in differentiated thyroid carcinoma and relationship to thyroid cancer outcome. Endocr J 2008;55(2):365-72.
6. Verkooijen RB, Smit JW, Romijn JA, Stokkel MP. The incidence of second primary tumors in thyroid cancer patients is increased, but not related to treatment of thyroid cancer. Eur J Endocrinol 2006;155(6):801-6.
7. Kim WG, Gong G, Kim EY, Kim TY, Hong SJ, Kim WB et al. Concurrent occurrence of medullary thyroid carcinoma and papillary thyroid carcinoma in the same thyroid should be considered as coincidental. Clin Endocrinol 2010;72(2):256-63.
8. Wong RL, Kazaure HS, Roman SA, Sosa JA. Simultaneous medullary and differentiated thyroid carcer. a population-level analysis of an increasingly common entity. Ann Surg Oncol 2012;19(8):2635-42.

How to cite this article:
Erhamamcı S, Reyhan M, Kocer NE, Canpolat T, Altınkaya N. Triple Primary Malignancies of Thyroid and Larynx in a Case of Retrosternal Guatr. J Clin Anal Med 2014;5(suppl 4): 511-4.