Giant Retroperitoneal Liposarcoma with Multi-Organ Involvement

Multiorgan Tutulumu Gösteren Dev Retroperitoneal Liposarkom

Dev Retroperitoneal Liposarkom / Giant Retroperitoneal Liposarcoma

Mustafa Ugur[1], Cem Oruc[1], Seckin Akkucuk[1], Yavuz Savaş Koca[2], Nesrin Atcı[3]
[1]Department of General Surgery, Medicine School of Mustafa Kemal University, Hatay,
[2]Department of General Surgery, Medicine School of Suleyman Demirel University, Isparta,
[3]Department of Radiodiagnostic, Medicine School of Mustafa Kemal University, Hatay, Turkey

Özet

Retroperitoneal liposarkom ender görülen, kötü prognozlu bir tümördür. Spesifik bir bulgu vermemesi nedeniyle kitleler büyük boyutlara ulaşana kadar tanı gecikebilmektedir. Cerrahi tedavi başlıca tedavi seçeneğidir. Dev liposarkomlu hastalar da çok sayıda organ rezeksiyonu gerekebilir ve kitlenin tam çıkarılamaması lokal nükslerin sebebidir. Medikal tedavi ise tartışmalıdır. Bu yazıda 2 yıl önce retroperitoneal kitle saptanarak ameliyat önerilen, ancak hasta tarafından ameliyat kabul edilmediği için dev boyutlara ulaşarak sol böbrek, sol adrenal bez ve sol kolon mezosunu tutan liposarkom olgusu sunuldu. Tümörün dev boyutlarda olması ve birçok organı tutmasının rezeksiyon açısından kontrendikasyon oluşturmadığını ve rezeksiyonun hastanın yaşam kalitesini arttırdığını göstermek için bu olguyu tartıştık.

Anahtar Kelimeler

Retroperitoneal Liposarkom; Yumuşak Doku Tümörleri; Cerrahi Tedavi

Abstract

Retroperitoneal liposarcomas are very rare tumors with poor prognosis. The diagnosis can be delayed since there are no specific symptoms and findings. Surgical resection is the primary treatment choice. Obtaining negative surgical margins should be the primary aim.,Multiple organ resections may be essential in cases with huge liposarcoma and incomplete resection leads to local recurrences. There is still an ongoing controversy in the medical treatment of liposarcoma. In this study we presented a patient with liposarcoma who was advised for surgery due to retroperitoneal mass 2 years ago but refused so the mass grew to a huge size invading left kidney, left adrenal gland and left mesocolon. We aimed to point out organ invasion and huge masses of liposarcoma are not contraindications for resection, and resections of these huge tumors improve quality of life. All retroperitoneal masses should be aggressively excised and patients should be closely followed up.

Keywords

Retroperitoneal Liposarcoma; Soft Tissue Sarcomas; Surgical Treatment

DOI: 10.4328/JCAM.3352 Received: 01.03.2015 Accepted: 19.03.2015 Printed: 01.08.2014 J Clin Anal Med 2014;5(suppl 4): 505-7
Corresponding Author: Mustafa Ugur, Department of General Surgery, Medicine Faculty of Mustafa Kemal University, Hatay, Turkey.
T.: +90 3262291000 F.: +90 32624556544 GSM: +905053463209 E-Mail: drmustafaugur@gmail.com

Introduction

Retroperitoneal liposarcomas make up 0.1% to 0.2% of all malignant tumors and 15% of all sarcomas. Liposarcomas are the most common type of retroperitoneal sarcomas (41%). It is followed by leimyosarcomas, malignant fibrous histiocytomas, fibrosarcomas and other undifferentiated sarcomas [1].

Retroperitoneal masses present with nonspecific findings. This delays diagnosis until the tumor reaches enormous sizes. For diagnosis, computerized tomography and magnetic resonance imaging gives information about the location and structure of the mass. Surgical excision is the golden standard for treatment [2,3].

In this study we presented a retroperitoneal liposarcoma case in which the patient was diagnosed as retroperitoneal mass and advised for surgery but refused to be operated so the mass grew to a huge size. The patient who could not walk and meet her own needs due to giant mass started walking and taking care of himself without any help after the surgery.

Case Report

History of 56 years old female patient hospitalized in our clinic with the diagnosis of giant retroperitoneal mass revealed that 2 years ago she attended a medical facility with abdominal pain and abdominal distention complaints where a retroperitoneal mass of 5 cm of size have been found and she was advised to be operated. But at that time by own will, the patient did not accept to be operated. She attended our clinic as the mass continued growing, and made the patient unable to walk and meet her own needs for the last 6 months.

Physical examination revealed severely distended abdomen (Picture 1). The patient who was unable to stand up and walk



Picture 1. Preoperative view of a patient with giant retroperitoneal sarcoma

due to the mass had sensitivity in all abdominal quadrants. Defense and rebound were not seen. Biochemical studies and complete blood count were normal.

Abdominal tomography showed gigantic mass lesion, localized in the left flank, neighbored by multiple solid mass lesions with the largest being 55x32 cm in size, accompanied by increase in surrounding fat tissue and dense inhomogenities at the mesentery and deplacing all abdominal organs to the right side (Picture 2). Additionally solid mass lesions of varying sizes and similar characters have been seen neighboring the lower lobe of the left kidney and inside the increased fat tissue (retroperitoneal malignant tumor? liposarcoma?). Thorax tomography did not reveal any pathology.

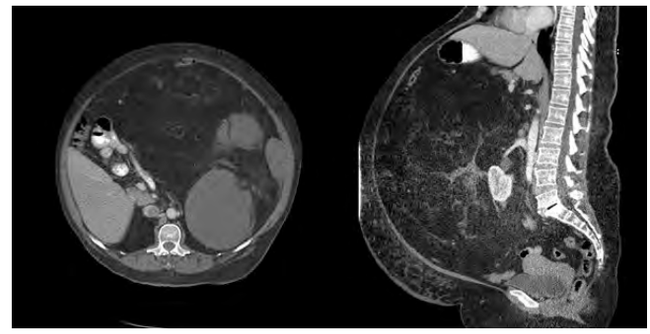

Picture 2. Abdominal computed tomography shows a heterogeneous retroperitoneal mass occupying the entire abdominal cavity

After completion of pre-operative preparations, the patient was operated. Due to the effect of giant retroperitoneal mass, right sided displacement of intraabdominal organs were seen. The mass had completely surrounded the left kidney and invaded the left mesocolon. Whereupon, excision of the mass, left hemicolectomy including its mesenter and left radical nephrectomy have been performed. The continuity of colon has been provided by end to end anastomosis (Picture 3).



Picture 3. Postoperative view of the specimen. Left colon is marked with arrow sign. Left kidney and surrenal gland are surrounded by the mass.

After a short time following the surgery, the patient started to walk and meet her own needs without any assistance. The patient who did not develop any post-operative complications was discharged.

The patient's pathology results showed a dedifferentiated liposarcoma with weight of 23 kg and dimensions of 60x40x27 cm. Tumor infiltration to left kidney capsule and the mesenter of left colon has been reported.

During controls at post-operative 3rd, 6th and 12th months, recurrence has not been seen.

Discussion

Primary retroperitoneal tumors show poor prognosis. 5 years survival rates of 5-20% have increased up to 65% with wide resections and negative surgical margins during recent years [4]. So the aim of the treatment of retroperitoneal sarcomas should be providing negative surgical margins. Difficulties of this aim are; the complexity of retroperitoneal anatomy, large tumor size and invasion of some vital organs [5]. In our case, despite gigantic size and invasion of left mesocolon, left kidney and left adrenal gland of the tumor; we tried to reach negative surgical margins so the mass with all the organs invaded have

been excised.

For prognosis; tumor size greater than 10 cm, patient older than 50 years of age, resection margins and local recurrence are important factors to determine the survival of the patient. Local recurrence depends on; large tumor size during diagnosis, inability to provide negative surgical margins and limited effectiveness of chemotherapy and radiotherapy. For cases with local recurrence, surgery and radiotherapy are advised [3,4]. In our case despite having all the negative conditions for local recurrence; during 1 year of follow-up, recurrence has not been encountered. And this proves the importance of negative surgical margins once more.

For retroperitoneal tumors, surgical excision is the most important treatment method for prolonging the survival of the patient. Also as it was with this case, retroperitoneal masses can cause advance disruption in the quality of life by preventing the patients to walk and meet their own needs. Surgical treatment can be the best option for these patients. Consequently, all retroperitoneal masses should be aggressively excised and patients should be closely followed up using techniques like computerized tomography or magnetic resonance imaging for local recurrences.

Competing interests

The authors declare that they have no competing interests.

References

1. Morandeira A, Prieto J, Poves I, Sánchez Cano JJ, Díaz C, Baeta E. Giant retroperitoneal sarcoma. Can J Surg 2008;51(4):79–80.
2. Leão P, Vilaça S, Oliveira M, Falcão J. Giant recurrent retroperitoneal liposarcoma initially presenting as inguinal hernia: Review of literature. Int J Surg Case Rep 2012;3(3):103–6.
3. Herrera-Gómez A, Ortega-Gutiérrez C, Betancourt AM, Luna-Ortiz K. Giant retroperitoneal liposarcoma. World J Surg Oncol 2008;31(6):115.
4. Lewis JJ, Leung D, Woodruff JM, Brennan MF. Retroperitoneal soft-tissue sarcoma: analysis of 500 patients treated and followed at a single institution. Ann Surg 1998;228(3):355-65.
5. Erzen D, Sencar M, Novak J. Retroperitoneal sarcoma: 25 years of experience with aggressive surgical treatment at the Institute of Oncology, Ljubljana. J Surg Oncol 2005;91(1):1-9.

How to cite this article:
Ugur M, Oruc C, Akkucuk S, Koca YS, Atcı N. Giant Retroperitoneal Liposarcoma with Multi-Organ Involvement: A Case Report. J Clin Anal Med 2014;5(suppl 4): 505-7.