Left Ventricular Pseudoaneurysm Formation Due to Free Wall Rupture

Serbest Duvar Rüptürüne Bağlı Sol Ventrikül Psödoanevrizması

Sol Ventrikül Psödoanevrizması / Left Ventricular Pseudoaneurysm

Ahmet Baris Durukan[1], Hasan Alper Gurbuz[1], Murat Tavlaşoğlu[2]
[1]Medicana International Ankara Hospital, Department of Cardiovascular Surgery, Ankara,
[2]Diyarbakır Military Medical Hospital, Diyarbakır, Turkey

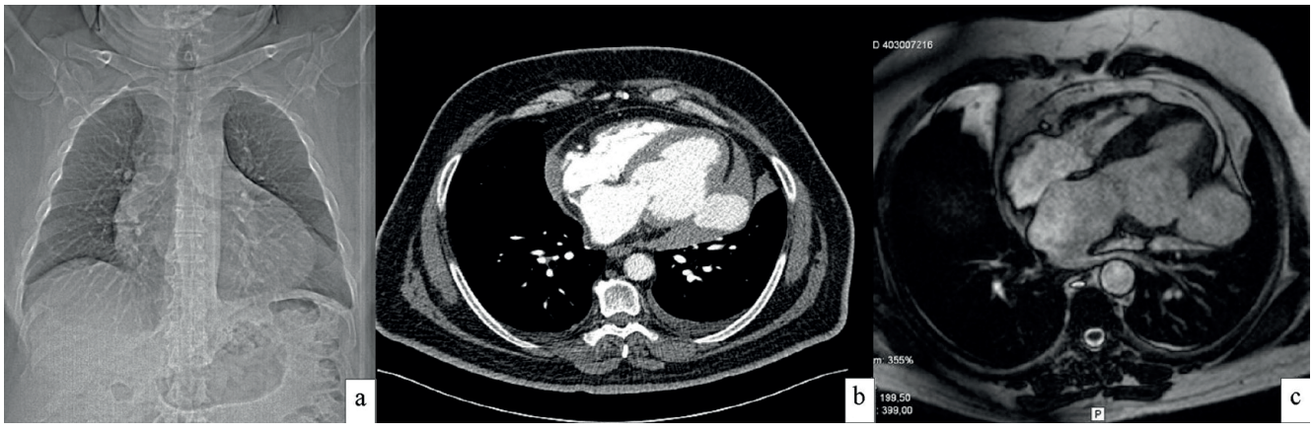

Figure1. Chest X-ray image (A), Cardiac CT image (B), Cardiac MRI image (C)
Video 1. Cardiac MRI demonstrating the defect on left ventricular free wall and pseudoaneurysm formation.

A 66 year old male patient admitted with chest pain on exertion. His coronary angiography revealed total occlusion of first obtuse marginal branch. Cardiac CT and MRI were performed and demonstrated left ventricular free wall rupture leading to pseudoaneurysm formation (Figure 1, Video 1). Cardiac CT image (Figure 1B) illustrates left ventricular free wall rupture on posterolateral aspect with pseudoaneurysm formation. Cardiac MRI (Figure 1C) revealed the defect on left ventricular free wall. The size of the defect was 20.4 mm in cranio-caudal direction. The dimensions of the pseudoaneurysm sac were measured as 49.5X42.4X46.7 mm. The patient refused surgical treatment.

DOI: 10.4328/JCAM.1448 Received: 05.12.2012 Accepted: 18.12.2012 Printed: 01.01.2015 J Clin Anal Med 2015;6(1): 141
Corresponding Author: Ahmet Baris Durukan, Department of Cardiovascular Surgery, Medicana International Ankara Hospital, Ankara, Türkiye.
GSM: +905322273814 F.: +90 3122203170 E-Mail: barisdurukan@yahoo.com