A Very Rare Cause of Chronic Groin Pain and Small-Bowell Obstruction: Obturator Hernia

Kronik Kasık Ağrısı ve İnce Barsak Obstrüksiyonunun Oldukça Nadir Bir Nedeni: Obturator Herni

Obturator Herni / Obturator Hernia

Ramazan Aydin[1], Selim Baris Gul[2], Mehmet Selim Nural[3]
[1]Department of Radiology, Samsun Training and Research Hospital, Samsun, Türkiye.
[2]Clinic of Radiology, Aksaray State Hospital, Aksaray, Türkiye.
[3]Department of Radiology, Faculty of Medicine, Ondokuz Mayıs University, Samsun, Türkiye.

A 65-year-old woman with presented to the Emergency Department (ED) with a suddenly onset of abdominal pain which was located in the left lower quadrant and left groin. She had recurrent attacks of left groin pain of about three year duration. Her pain was exacerbated by adduction and radiating to the thigh. On physical examination, she had a distended abdomen. No palpable inguinal mass or hernia was found. All biochemical laboratory tests were within the normal range. Abdominal radiography showed a small-bowel obstruction. Abdominal ultrasonography showed multiple dilated small bowel loops. Computed tomography (CT) scan was performed urgently at the emergency radiology room. CT showed a bowel loop between the left obturator externus and pectineus muscles and presence of dilated small-bowel loops, consistent with a diagnosis of small-bowel obstruction secondary to an obturator hernia (Fig. 1A, B). An emergency laparotomy was performed and the hernia was repaired.

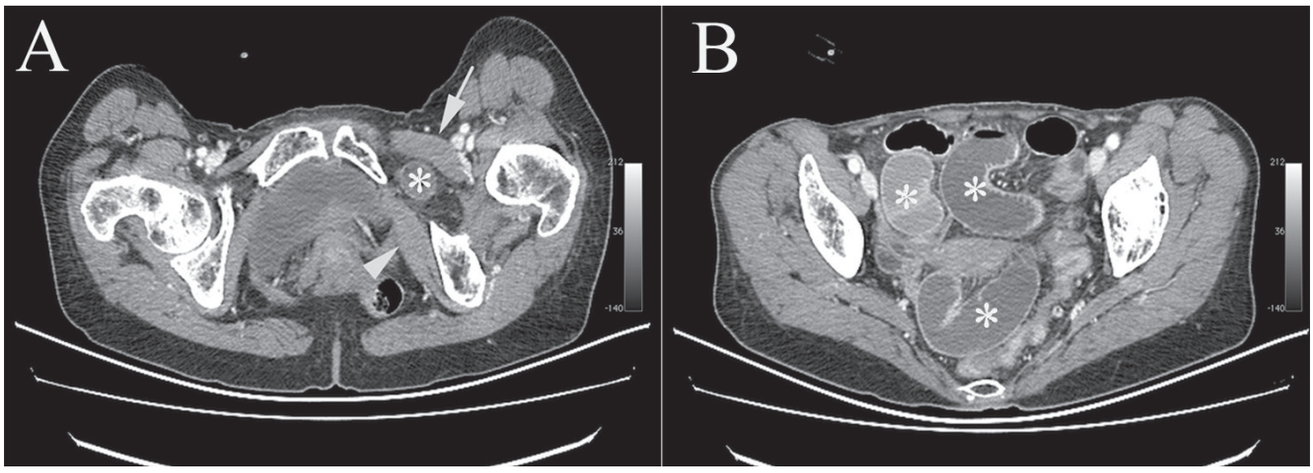

Figure 1. CT showed a bowel loop (asterisk) between the left obturator externus (arrowhead) and pectineus muscles (arrow)(A), Dilated small bowel loops filled with fluid (B), consistent with a diagnosis of small-bowel obstruction secondary to an obturator hernia.

DOI: 10.4328/JCAM.2240 Received: 19.12.2013 Accepted: 03.01.2013 Printed: 01.01.2015 J Clin Anal Med 2015;6(1): 136
Corresponding Author: Ramazan Aydin, Department of Radiology, Samsun Training and Research Hospital, Samsun, Türkiye.
T.: +90 3623121919 F.: +90 3624576041 E-Mail: raydin1984@hotmail.com