An Unusual Mass on the Skin of Scrotum: Acrochordon

Skrotum Cildinde Alışılmadık Kitle: Akrokordon

Skrotum Cildi ve Akrokordon / Scrotal Skin and Acrochordon

Ahmet Ali Sancaktutar[1], Yaşar Bozkurt[1], Abdülkadir Tepeler[2], Necmettin Penbegül[1], Murat Atar[1]
[1]Department of Urology, University of Dicle, Diyarbakır, [2]Department of Urology, University of Bezmi Alem, Turkey

Makale 9. Ulusal Androloji Kongresinde poster olarak sunulmuştur.

Özet

Akrokordonlar (skin tag, fibroepitelyal polip) vücudun herhangi bir yerinden kaynaklanabilen yumuşak, deri renginde, pediküllü lezyonlardır. Vücutta çok yaygın bulunmalarına rağmen dev akrokordonlar literatürde nadir olarak bildirilmiştir. Histolojik olarak gevşek kollajen lifleri ve dilate kapillerlerden oluşur. Biz bu yazıda skrotum cildinden kaynaklanan dev bir akrokordon vakasını sunuyoruz.

Anahtar Kelimeler

Akrokordon; Skin Tag; Skrotum Cildi

Abstract

Acrochordons (skin tag or fibroepithelial polyp) are soft, skin-colored, pedunculated lesions that can be present anywhere on the body. Although they are common in other sites of the body, giant acrochordons are reported rarely in the literature. Histologically, the polyp were covered by squamous epithelium, stroma was composed of loose collagen fibers and dilated capillaries. We present the case of one giant skin tag on scrotum.

Keywords

Acrochordon; Skin Tag; Scrotum Skin

DOI: 10.4328/JCAM.794 Received: 05.09.2011 Accepted: 03.01.2012 Printed: 01.01.2015 J Clin Anal Med 2015;6(1): 112-113
Corresponding Author: Ahmet Ali Sancaktutar, Department of Urology, University of Dicle, Diyarbakır, Turkey.
T.: 00 90 412 248 80 01 F.: 00 90 412 248 85 23 M.: 00 90 532 362 05 44 E-Mail: aasancaktutar@gmail.com

Introduction

Acrochordon is the descriptive term for the soft, fleshy, sessile or pedunculated lesions. Many synonyms were used in the literature. Among them skin tag is the most embracing and frequently used term. It is sometimes also called fibroepithelial polyp (1). They are usually diagnosed by clinical features. However, histological examination may be needed for diagnosis in unusual cases (2). Herein, we present a patient with giant achrochordon on the scrotum. To the best of our knowledge, this is the first report in the literature.

Case Report

A 63-year-old man attended to our department with the complaint of scrotal mass. Physical examination revealed a 35x30 mm, skin colored, soft, fleshy, pedunculated and baglike mass on the lower skin of the scrotum (Figure 1). Lesion had been growing slowly since six years. He did not have any other lesions at the other sites of the body. He did not have any other disease and use any medication. His liver-kidney functions and blood glucose level were normal. Under caudal blockage anesthesia the lesion was totally excised and cotherisied with a scalpel and the base of the lesion was inspected for the presence of any residual lesion. Lesion was not repeated at the end of the first year.



Figure 1. Preoperative appearance of the Acrochordon

In our case; histologically, fibroepithelial polyps contained broader stalks with dense fibrous tissue. The polyps were covered by squamous epithelium showing variable epithelial hyperplasia, dyskeratosis, and lymphocytic epitheliotropism. In the stroma were present collagen, smooth muscle, and adipose tissue. Sometimes the stroma is markedly edematous. These stromal cells were immunoreactive vimentin, demsin, steroid receptors but usually not for actin (Figure 2).

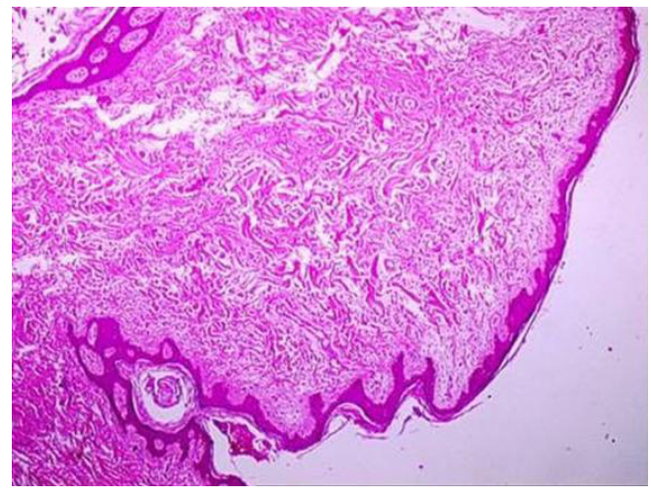

Figure 2. Fibroepithelial polyp of scrotum. HE x 100

Discussion

The incidence of these lesions on the male genitalia has not been reported in the literature. In the literature on this subject is very little information. Acrochordons have an irregular or smooth surface and most commonly located on eye lids, neck, axillae, trunk, groin, and on the lumbar area. Although usually asymptomatic, these lesions may be painful secondary to local trauma or torsion and infarction in rare cases (3). In our case, there was uncomfortable with the appearance of this lesion.

There are a few case reports of giant achrocordons including one reported on male external genitalia. Interestingly, theories about the etiology include genetic predisposition, metabolic diseases, hyperinsulinemia, and even virus infection (papilloma virus). The presence of skin tags may be an important marker for the presence of type II diabetes mellitus (4). In our case, there was no predisposing factor. If long-standing, skin tags can become fibrous, vascularised, or ischemic (2). However, none of these changes were observed in our patient. When bag-like, soft fibromas are painful and cosmetically undesirable they can be cured by simple excision. Acquired skin tags are removed by snipping with curved scissors, by cryotherapy, or electrodessication (1). According as we consider the size of the lesion was surgically excised under caudal anesthesia.

The lesions are slow growing (2). In our case, lesion appeared six years ago and gradually grew. It is important to distinguish these lesions from the hamartomatous skin lesions (multiple fibrofolliculomas) associated with Birt-Hogg-Dubé syndrome, which are histologically distinct from common skin tags (5). The microscopical examination of fibroepitelial polyp involves squamous epithelium. In the stroma, collagen, smooth muscle, and adipose tissue were present (6). In other instances it is hypercellular and/or contains scattered highly atypical stromal cells of stella shape.

Competing interests

The authors declare that they have no competing interests.

References

1. Emir L, Ak H, Karabulut A, Ozer E, Erol D. A huge unusual mass on the penile skin: acrochordon. Int Urol Nephrol 2004;36(4):563-5.
2. Banik R, Lubach D. Skin tags: localization and frequencies according to sex and age. Dermatologica 1987;174(4):180-3.
3. Margolis DJ. Cutaneous diseases of the Male External Genitalia. In: Walsh PC, Retik AB, Vaughan ED, Wein AJ, eds. Campbell's Urology. Philadelphia: Saunders Company; 2002.p.727.
4. Dianzani C, Calvieri S, Pierangeli A, Imperi M, Bucci M, Degener AM. The detection of human papillomavirus DNA in skin tags. Br J Dermatol 1998;138(4):649-51.
5. Fujita WH, Barr RJ, Headley JL. Multiple fibrofolliculomas with trichodiscomas and acrochordons. Arch Dermatol 1981;117(1):32-5.
6. Lever WF, Lever GS. Tumors of Fibrous Tissue. In: Lever WF, Lever GS, eds. Histopathology of the Skin, Philadelphia: Lippincott Company; 1990.p.664–5.