Hydrocarbon Pneumonitis; Clinical and Radiological Variability

Hidrokarbon Pnömonisi; Klinik ve Radyolojik Değişkenlik

Hidrokarbon Pnömonisi / Hydrocarbon Pneumonitis

Bunyamin Sertogullarindan[1], Aydin Bora[2], Fuat Sayır[3], Bulent Ozbay[1]
[1]Department of Pulmonary Medicine, [2]Department of Radiology,
[3]Department of Chest Surgery, Yuzuncu Yil University Medical Faculty, Turkey

Özet

Hidrokarbonların aspirasyonu basitten kritik düzeye kadar solunumsal patolojilere neden olur. Amacımız bu olgulardaki radyolojik ve klinik değişkenliğe dikkati çekmektir. Yirmi iki yaşında kaza ile dizel yakıt aspire eden genç bir erkek olguyu sunduk. Olgu Aspirasyondan üç gün sonra klinik kötüleşme nedeni ile acil servisimize başvurdu. Başvuru sırasına ait güğüs grafisinde sağ orta lobda infiltrasyon saptandı. Fakat iki gün sonra sağ alt lob atalektazisi gelişti. Bronkoskopik incelemede mukozal hiperemi ve ödem izlendi, bronş obstrüksiyonu yoktu. Sekonder bakteriyel pnomoni saptanmadı. Hasta sistemik kortikosteroid ve antibiyotik ile tedavi edildi. Tedaviden iki hafta sonra tam klinik iyileşme ve önemli radyolojik gerileme vardı. Hidrokarbon aspirasyon vakalarında klinik tablo değişkendir. Radyolojik görünüm gecikme ile gelişebilir. Önemli bir komplikasyon için yeni bir delil saptanmadıkça steroid tedaviye devam edilmelidir.

Anahtar Kelimeler

Hidrokarbonlar; Aspirasyon

Abstract

Aspiration of hydrocarbons causes respiratory pathologies from simply to critical. Our aim is to attract attention to clinical and radiological variability in these cases. We presented a 22-year old young case exposed to diesel fuel by accidental aspiration. Three days after the aspiration, because of clinical deterioration, he was admitted to our emergency clinic. In the chest radiograph on admission showed infiltration in the right middle lobe. But a right lower lobe atelectasis emerged two days later. Bronchoscopy revealed inflamed and hyperemic mucosa and no bronchial obstruction. No secondary bacterial pneumonia was seen. The patient was treated with systemic steroids and antibiotics. After two weeks of treatment there was complete clinical improvement and significant radiologic regression. In the hydrocarbon aspiration cases clinical picture is variable. Radiological picture may develop with a delay. Unless there is a new evidence for an important complication, the steroid treatment should be followed.

Keywords

Hydrocarbons; Aspiration

DOI: 10.4328/JCAM.869 Received: 17.12.2011 Accepted: 19.01.2012 Printed: 01.01.2015 J Clin Anal Med 2015;6(1): 117-119
Corresponding Author: Bunyamin Sertogullarindan, YYU Arastirma Hastanesi, K.Karabekir Caddesi 65200 Van, Turkey.
T.: +90 4322150470-6135 GSM: +905336584452 E-Mail: bunyaminsert@hotmail.com

Introduction

Products of petroleum have been used commonly in daily life. They are members of hydrocarbons. Aspiration of hydrocarbons causes respiratory pathologies from simple symptoms to critical result. Hydrocarbon pneumonitis, known also as fire-eater pneumonia, always develops after aspiration of low viscosity, volatile hydro carbides [1]. In the current article, we report a case of hydrocarbon pneumonitis of a 22-year-old young truck driver after petroleum aspiration by siphonage.

Case Report

A 25-year-old a truck driver young man was admitted to our emergency department for evaluation of moderate dyspnea, severe right-side chest pain, hemoptysis and cough. His general condition was poor. There was no previous medical history. The symptoms began after an episode of accidental diesel aspiration while siphoning from the fuel tank of a truck. His personal history was unremarkable. Clinical examination revealed chest wall tenderness and fine rales over the right midlung field. However prominent decreased breath sound was developed in the right base after two day admission. He was normotensive with a heart rate of 104 per minute and a respiratory rate of 25 breaths per minute. The remaining physical examination findings were normal.

On laboratory examination, complete blood count revealed elevated white blood cells (14.110/µl) and an erythrocyte sedimentation rate of 56 mm/h. Serum electrolytes, hepatic and renal function tests were normal. Arterial blood gas measurements; pH = 7.38, pCO2 = 36.3 mmHg, pO2 = 55 mmHg and SaO2 = 85%. Spirometer revealed moderate restriction of lung function. On admission chest radiograph demonstrated a density in the right middle lobe. A Repeated chest radiography on the 3rd day of admission showed consolidation with volume loss and blurring of diaphragmatic contour in the right lower lobe (Fig 1A, 1B). A chest computed tomography scan showed a prominent consolidation with an air bronchogram in the right middle lobe, a minimal consolidation in the left lower lobe and atelectasis in

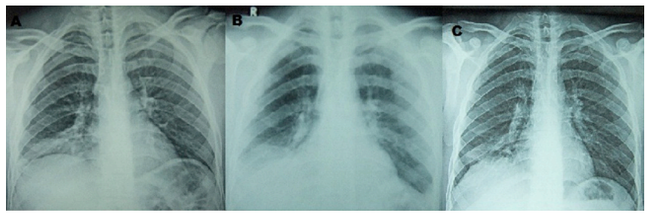

Figure 1. Chest radiographs of the patient taken on admission (A), on the 3rd (B) and 15th (C) day of the treatment.

the lower right lobe, and pleural effusion in the right hemitorax (Figs. 2 and 3). Bilateral minimal pleural effusion was seen on thoracic ultrasonography. On bronchoscopic examination, inflamed and hyperemic mucosa especially on the right side was noted. Signs of bronchial purulence or obstruction were not observed. On examination of bronchoalveolar lavage (BAL) fluid no pathogens, ie, bacteria, mycobacteria or fungi, were demonstrated, either microscopically or by culturing. Conservative therapy was initiated, which included 1 g of ampicilline/sulbactam i.v. tid, and 40 mg of metilprednisolone/day. Conservative therapy led to a marked decline of the symptoms and radiologic findings (Fig 1C), accompanied by an obvious improvement of the patient's general condition.

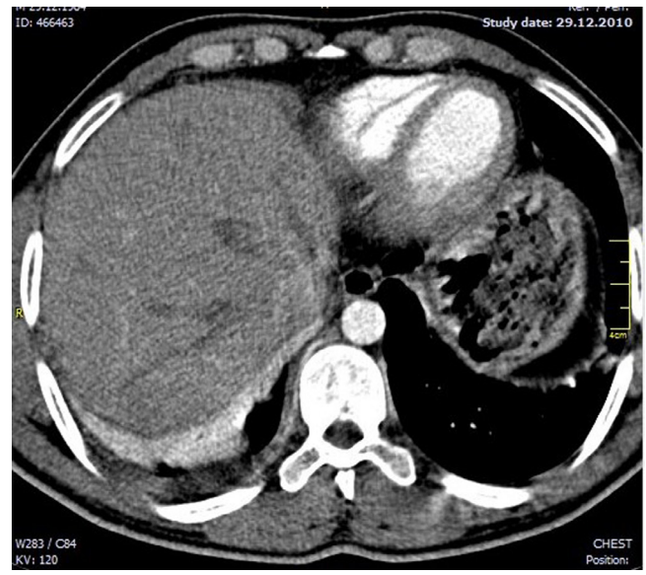

Figure 2. Computerized tomography of the thorax shows atelectasis in the right lower lobe and pleural effusion

Discussion

Exposure to hydrocarbons can happen in many forms, but it causes the most destruction with aspiration [1]. Aspiration of hydrocarbons is an acute hydrocarbon pneumonitis which may happen accidentally while siphoning from fuel tank or motor vehicles. It is occasionally seen in adults, especially drivers, farmers and auto mechanics [2-4]. The toxic potential of hydrocarbons is directly related to their physical properties. Highly volatile with low viscosity and lower surface tension hydrocarbons are more likely to be inhaled or aspirated into the respiratory system [1]. The hydrophobic nature of them let them to penetrate deep into the tracheobronchial tree. Direct contact with alveolar membranes can lead to hemorrhage, hyperemia and edema. They provoke the activation of macrophages, leading to an increased release of cytokines and a prolonged inflammatory reaction [5]. The type II pneumocytes are most affected, resulting in a decreased surfactant production. The surfactant layer, which is composed of lipids, is made soluble by hydrocarbons, causing further damage [6]. The end results of hydrocarbon aspiration are necrosing chemical pneumonitis, atelectasis, pleural effusion and hypoxemia [7].

Typical clinical symptoms and findings of patients are similar with any infectious pneumonia; chest pain, dyspnea, cough, fever, and hemoptysis can be seen [8]. Especially severe chest pain and tenderness of chest wall, which could be related to chemical pleuritis, were remarkable symptoms of the patient. Shortness of breath worsened in late-period due to atelectasis in our patient.

The radiological lesions are generally out of proportion to the clinical findings. Radiographic findings include unilateral or bilateral lung consolidation, pneumatoceles, pleural effusion, atelectasis and spontaneous pneumothorax [9]. It was reported that pneumonitis of right middle lobe might occur if the patient bent forward. while siphoning [2]. Our patient also reported that he was in similar position. Ultrasound examination revealed a small amount of bilateral pleural effusion, while there was no pneumonia on the left side on chest radiography. It is suggested that a small amount hydrocarbon aspiration can cause

pleural irritation that leads to pleural effusion. In the hydrocarbon pneumonia, the affected region can be seen directly, BAL can be performed and microbiological samples can be taken via bronchoscopy [5] .On bronchoscopy we observed bilateral hyperemia, edema and necrosis, which was more prominent on the right side.

Hydrocarbon pneumonia is a pseudo-infectious lung disease with a severe release of inflammatory cytokines with macrophage activation. The inflammatory nature of the disease suggests that steroid treatment can be useful in these patients. However there have been conflicting reports about the effectiveness of steroids [10]. Our patient had significantly improved by steroid treatment. The conflicting reports on the use of steroids could be due to different intensity of exposures and complications of pneumonitis such as microbial superinfection and acute respiratory failure. Prophylactic antibiotic therapy is usually applied in these cases. A prophylactic antibiotic therapy was also begun in our patient since he was admitted 3 days after the event. Because pathogens were not detected in bronchial samples we discontinued antibiotic treatment. The prognosis is generally good in hydrocarbon aspiration and our patient completely improved after 15 days of treatment. However some studies reported that some complications may develop, which included abscess, bronchopulmonary fistula, bacterial superinfection and acute respiratory failure and death.

Conclusion

Symptoms and radiologic findings may be not clear in early time. Also the relationship between exposure and symptoms may be overlooked in the late period. physician should be aware of that hydrocarbons can provoke a pneumonitis.

Competing interests

The authors declare that they have no competing interests.

References

1. Dyer S. Hydrocarbons. In: Wolfson AB, Editor. Harwood-Nuss' Clinical Practice of Emergency Medicine. Philadelphila USA: Lippincott Williams & Wilkins; 2005.p.1590-3.
2. Carlson DH. Right middle lobe aspiration pneumonia following gasoline siphonage Chest 1981;80(2):246-7.
3. Khanna P, Devgan SC, Arora VK, Shah A. Hydrocarbon pneumonitis following diesel siphonage. Indian J Chest Dis Allied Sci 2004;46(2):129-32.
4. Sertogullarından B, Ozbay B, Asker S, Ekin S. Hydrocarbon pneumoniae cases. The Archives of Lung 2011;12(1):33-8.
5. Burkhardt O, Merker HJ, Shakibaei M, Lode H. Electron microscopic findings in BAL of fire-eater after petroleum aspiration. Chest 2003;124(1):398-400.
6. Giammona ST. Effects of furniture polish on pulmonary surfactant. Am J Dis Child 1967;113(6):658-63.
7. Olsen KR. Poisoning. In: Tierney LM, McPhee SJ, Papadakis MA, editors. Current Medical Diagnosis and Treatment. New York McGraw-Hill Company; 2000.p.1567-8.
8. Kitchen JM, O'Brien DE, McLaughlin AM. Perils of fire eating. An acute form of lipoid pneumonia or fire eater's lung. Thorax 2008;63(5):401-39.
9. Franquet T, Gómez-Santos D, Giménez A, Torrubia S, Monill JM. Fire eater's pneumonia: radiographic and CT findings. Comput Assist Tomogr 2000;24(3):448–50.
10. Steele RW, Conklin RH, Mark HM. Corticosteroids and antibiotics for the treatment of fulminant hydrocarbon aspiration. JAMA 1972; 219(11):1434-7.