"Typhlitis"
A Rare Diagnose For Emergency Room; Case Report

"Tiflitis"
Acil Serviste Nadir Teşhis; Olgu Sunumu

Tiflitis / Typhlitis

Birdal Gullupinar[1], Aydin Sarihan[1], Hanife Ciftcioglu[1], Hakan Topacoglu[2]
[1]Department of Emergency Medicine, Dokuz Eylul University School of Medicine, Izmir,
[2]Department of Emergency Medicine, Istanbul Training and Research Hospital, Istanbul, Turkey

29-31 Ekim 2010 tarihleri arasında Antalya'da yapılan "II. EurAsian Congress on Emergency Medicine" kongresinde "poster bildiri" olarak sunulmuştur.

Özet

Tiflitis, çıkan kolon ve çekumun nekroz ve perforasyonu ile karakterize akut bir tablodur. Sıklıkla lösemi ve lenfoma ile ilişkili görülür. Maligniteli bir hastada, nötropeni, ateş, sağ alt kadranda ağrı ve hassasiyet mevcutsa ilk akla gelmesi gereken tiflitisdir. Tiflitis tanısında batın bilgisayarlı tomografisi kullanılır. Tiflitis yüksek düzeyde mortalite ve morbiditeyle ilişkilidir. Tiflitisin tedavisi medikal veya komplikasyonlara göre cerrahi tedavidir. Erken tanı konulmalı ve tedaviye başlanılmalıdır. Yazımızda, acil servislerde nadir görülen bir onkolojik acil olan "Tiflitis" olgusunu sunup, tanı ve tedavi yöntemlerini literatür bilgileri eşliğinde gözden geçirdik.

Anahtar Kelimeler

Nötropeni; Karın Ağrısı; Ateş; Enterokolit; Malignite

Abstract

Typhlitis is an acute table that is characterised by the necrosis and perforation of the ascendant colon and cecum. It is often observed to be related to leukemia and lymphoma. If neutropenia, fever, pain in lower right quadrant and sensibility is present in a patient with malignancy, the first thing to think about is typhlitis. Abdominal computed tomography is used in the diagnosis of typhlitis.Typhlitis is related to high mortality and morbidity.The theraphy for typhlitis is medical or, depending on the complications, surgical. Diagnosis should be early and therapy should be started immediately. In our paper, we have presented the "typhlitis" case, which is an oncological emergency that is rarely observed in emergency services, and examined the diagnosis and therapy methods in the light of the relevant literature.

Keywords

Neutropenia; Abdominal Pain; Fever; Enterocolitis; Malignancy

DOI: 10.4328/JCAM.878 Received: 13.12.2011 Accepted: 19.01.2012 Printed: 01.01.2015 J Clin Anal Med 2015;6(1): 123-125
Corresponding Author: Birdal Güllüpinar, Vali Hüseyin Öğütçen Bulvarı, Korutürk Mahallesi, Ilıca Apt. 37/3 35220 Balçova, İzmir, Türkiye.
T.F.: +90 2324122701 GSM: +905419400369 E-Mail: birdalg@yahoo.com

Introduction

The most important cause of morbidity and mortallity in patients with malignency is infection. Typhlitis is a rarely observed acute complication of neutropenia; it is also known as neutropenical enterocolitis and ileocecal syndrome. In cases with malignancy, typhlitis causes ulceration, necrosis, perforation in intestinal segment by causing the destructive lesion of ileocecal area [1]. Although it is often related to leukemia and lymphoma, it also seen in patients with solid tumor, multiple myeloma, aplastic anemia, AIDS and cyclic neutropenia [1,2]. Being rarely observed in adults, these days typhlitis is encountered in increasing frequency, due to agressive chemotherapy applications [3]. In neutropenic patients, interfering infections should be intervened rapidly with correct diagnosis. Otherwise mortality rate is very high. In our paper,we have presented the "typhlitis" case, which is an oncological emergency that is rarely observed in emergency services, and examined the diagnosis and therapy methods in the light of the relevant literature.

Case Report

60 years old male patient presented to the emergency room with complaints of fever, severe pain in abdomen, diarrhea, that started one day before the application. Patients biography included hypopharynx cancer that was diagnosed five months ago. Patient received eight cures of chemotherapy (Cisplatin) and two cures of radiotherapy. It was learned that he received the last chemotherapy ten days ago.

When the patient arrived his overall condition was good and he was conscious, cooperative and oriented. Patient evaluation in the emergency department revealed a blood pressure 110/80 mmHg, heart rate 112 beats per minute, a body temperature of 38.4 0C and breathing count 16/min. His physical examination showed that there was guarding and rebound tenderness in his right lower abdominal quadrant. His cardiovascular and respiratory system examinations were normal. The results of his total blood count were as follows: Hb 9.1 mg/dl, Htc 27.1 mg/dl, RBC 3840000/mm3, trombosit 180000/mm3, WBC 600 mm3 (absolute neutrophil count was 200). There was nothing extraordinary in the results of urinary and fecal analyses. His chest X-ray was normal. In his abdominal computed tomography, prevalent wall thickening in the terminal ileum, cecum and ascendant colon was detected (Figure 1).

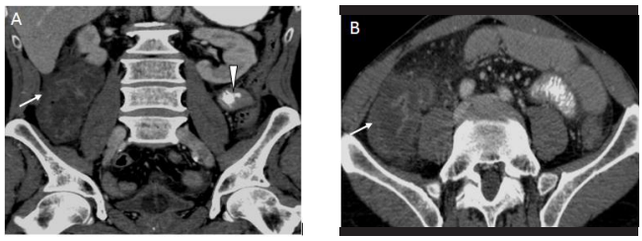

Figure 1. Prevalent wall thickening in the terminal ileum, cecum and ascending colon (A, B)

According to the fever, abdominal pain, neutropenia and CT findings, patient was diagnosed as typhlitis and his oral intake was halted. Intravenous paranteral fluid therapy, antibiotic (tazocin), Neupogen (SC) and IV analgesia therapy was started. Patient was admitted to hospital and no reproduction was detected in his blood, urine and stool cultures. Patient was discharged healthy, eight days after his admittance.

Lab values	Normal value	First day	4th day	8th day
WBC	4.000-10.000 UL	600	19.9	10.1
Hb	13.5-17.5 g/dl	9.1	10.3	8.0
RBC	4-5.7 UL	2.93	3.25	2.57
PLT	156-373 UL	180	70	83
Neu	41-73 %	30.2	93.6	87.7

Discussion

Fatal bacterial infections in neutropenic cases was first defined by Bodey in 1960. Typhlitis is the destructive lesion of the ileocecal areas in cases with malignancy. The word "tiflit" is derived from the Greek word "tiflon", meaning cecum. Abdominal pain and fever are the two components of the classical triad of typhlitis. The addition of neutropenia to these two findings supports the typhlitis diagnosis. Typhlitis is encountered in increasing frequency, due to agressive chemotherapy applications [1-3]. McCarville et al. [4] stated that the patients 16 years or older are more exposed to risk than the younger ones.

Although the pathogenesis of this syndrome is not fully known, it is a result of cytotoxic therapies that harm the gastrointestinal canal mucosa, neutropenia, and the disruption of parasite defence mechanism [5]. It is claimed that wall integrity is lost due to leukemic infiltration of colon mucosa and cytotoxic effect of chemotherapy. The disruption of defence system due to neutropenia makes the invasion of bacteria from intestinal wall easier. Bacterial endotoxin production, bacteriemia, necrosis and hemorrhage development follows. Although cecum influence is principal, the disease can also be seen in terminal ileum, other parts of intestines and ascendant and descendant colon. Transverse colon, descendant colon and even rectum retention is reported. The loss of neutropenia normal granulocyte reaction, relative stasis in intestine content in cecum, and malnutrition due to dilatation of cecum can prepare the presence of typhlitis in the cecum [6].

In typhlitis, various findings can be observed ranging from nonspecific gastrointestinal symptoms to typical symptoms. In the neutropenic patient, it is often observed with fever, abdominal and / or sensitivity [7].Gastrointestinal system hemorrhage can also be added to the table.

Although most of the patients apply with typhlitis after chemotherapy, a minority of the patients apply before chemotherapy. In some patients, typhlitis can be a application reason before diagnosis [8].

Abdominal computed tomography (abdominal CT) screening is found to be effective in differential diagnosis of Tifilitis and in the direction of the therapy [3]. Compared with colonoscopy and contrast enema, abdominal CT is a preferred method since it entails no risk of intestine perforation. Thickened cecum wall and cecal distension is observed in abdominal CT [9]. Also, inflammation in the adjoint mesenteric fat tissue is frequently observed. If the patient is unable to be taken to abdominal CT, bedside USG is a very good screening method [10].

Abdominal CT is very important in evaluating the response to therapy, as well as being helpful in detecting complications and surgery requiring complications such as pneumotosis intestinalis, pneumoperitonium, acid and abscess [9]. A new diagnostic criterion addition to clinical findings is the a more than 4 mm's

increase in intestine wall thickness (especially in the cecum area) [11]. As a CT finding, there is a direct relationship between intestine wall thickness and mortality. An intestine wall thickness equal to or above 10 mm's in USG is a bad prognosis indicator [10].

It can imitate diseases like appendicitis, colonical pseudo-obstruction, inflammatory intestine disease and diverticulitis [5]. Abdominal pain related to chemotherapy, ischemic colitis and infections developed by microbial agents that can be an infectious diarrhea factor should also be included in differential diagnosis.

In the therapy of Typhlitis, medical and surgical therapy approach is principal. Compared with early surgical therapy, medical therapy is reported in the literature to decrease mortality rates. In medical therapy, halting of oral intake, immediate starting of wide spectrum antibiotic effective against anaerobe and pseudomonas aeruginosa, intravenous parenteral nutrition, nasogastric drainage and analgesic application is recommended. Also improvement in the clinical condition is observed after use of recombined G-CSF [5,11]. Worsening of clinic, thrombocytopenia progress, persistent gastrointestinal system hemorrhage, perforation inside abdomen makes surgery necessary and wide spectrum antibiotic therapy is applied with the surgical application [6]. Typhlitis is observed as a mortally inclined disorder despite fast diagnosis and therapy. Published mortality rates range betweeen 0.8–26% [5,12].

Conclusion

Typhlitis is the inflammation of cecum, frequently accompanied by the neighboring tissues. It as an oncological emergency, observed as a rare complication of neutropenia, and that can be diagnosed by anamnesis, physical examination and radiological method. In patients where abdominal pain and neutropenia is important for early diagnosis of typhlitis that is important for early therapy and mortality.

Competing interests

The authors declare that they have no competing interests.

References

1. Hsu TF, Huang HH, Yen DH, Kao WF, Chen JD, Wang LM, et al. ED presentation of neutropenic enterocolitis in adult patients with acute leukemia. Am J Emerg Med 2004;22(4):276-9.
2. Bavaro MF. Neutropenic enterocolitis. Curr Gastroenterol Rep 2002;4(4):297-301.
3. Schlatter M, Snyder K, Freyer D. Successful nonoperative management of typhlitis in pediatric oncology patients. J Pediatr Surg 2002;37(8):1151-5.
4. McCarville MB, Adelman CS, Li C, Xiong X, Furman WL, Razzouk BI, et al. Typhlitis in childhood cancer. Cancer 2005;104(2):380-7.
5. Davila ML. Neutropenic enterocolitis. Curr Opin Gastroenterol 2006;22(1):44-7.
6. Urbach DR, Rotstein OD. Typhlitis. Can J Surg 1999;42(6):415-9.
7. Song HK, Kreisel D, Canter R, Krupnick AS, Stadtmauer EA, Buzby G. Changing presentation and management of neutropenic enterocolitis. Arch Surg 1998;133(9):979-82.
8. de Britto D, Barton E, Spearks KL, Cranmer HH, Karp SJ, Anglin D, et al. Acute right lower quadrant pain in a patient with leukemia. Ann Emerg Med 1998;32(1):98-101.
9. Frick MP, Maile CW, Crass JR, Goldberg ME, Delaney JP. Computed tomography of neutropenic colitis. Am J Roentgenol 1984;143(4):763-5.
10. Cartoni C, Dragoni F, Micozzi A, Pescarmona E, Mecarocci C, Chirletti P, et al. Neutropenic enterocolitis in patients with acute leukemia: prognostic significance of bowel wall thickening detected by ultrasonography. J Clin Oncol 2001:19(3):756-61.
11. Gorschlüter M, Mey U, Strehl J, Ziske J, Schepke M, Schmidt-Wolf IG, et al. Neutropenic enterocolitis in adults: systematic analysis of evidence quality. Eur J Haematol 2005; 75(1):1-13.
12. Cunningham SC, Fakhery K, Bass BL, Napolitano LM. Neutropenic enterocolitis in adults: case series and review of the literature. Dig Dis Sci 2005;50(2):215-20.