Aortopulmonary Fistula After the Native Aortic Valve Endocarditis

Aort Kapak Endokarditinden Sonra Aortopulmoner Fistül

Aortik Endokardit Komplikasyonu / Complication of Aortic Endocarditis

Ahmet Kırbaş[1], Nurşen Tanrıkulu[2], Melih Us[1], Ömer Işık[1]
[1]Kalp Damar Cerrahisi Kliniği, [2]Anesteziyoloji ve Reanimasyon Kliniği, Medicana Çamlıca Hastanesi, İstanbul, Türkiye

Özet

Aortopulmoner fistül(APF) mekanik aort kapak replasmanından sonra gelişen endokarditlerde sık olarak bildirilmekte iken aort kapak endokarditinden sonra literatürde nadir olarak bulunmaktadır.60 yaşında bayan olgu hastanemize iki gündür devam eden yüksek ateş,solunum sıkıntısı ile başvurdu.İnfektif endokarditten şüphelenilen hastanın kan kültüründe Staphylococcus aureus üredi. Ekokardiografi ve anjiografide ileri aort yetmezliği ve APF görüldü.Hastaya acil olarak aort kapak replasmanı ve APF'ün Contegra greft ile kapatılması operasyonu uygulandı.Hasta multiorgan yetmezliği nedeni ile postoperatif 63.gün kaybedildi.

Anahtar Kelimeler

Aort Kapak Replasmanı; İnfektif Endokardit; Cerrahi

Abstract

Aortopulmonary fistula associated with endocarditis complicating mechanical aortic valve replacement has been reported but very limited reports of aortopulmonary fistula following native aortic valve endocarditis in the literature. A 60 year old female presented to our hospital with high fever, dyspnea symptoms over two days. We suspect the endocarditis that Staphylococcus aureus was isolated from blood cultures. Echocardiogram and cathaterization showed that severe aortic regurgitation, aortopulmonary fistula.We urgently performed the aortic valve replacement and closure of both side of fistula with the Contegra® patch.The patient developed multiorgan failure as a cause of death at postoperative 63.day .

Keywords

Aortic Valve Replacement; Infective Endocarditis; Surgery

DOI: 10.4328/JCAM.944 Received: 12.03.2012 Accepted: 23.03.2012 Printed: 01.03.2015 J Clin Anal Med 2015;6(2): 260-262
Corresponding Author: Ahmet Kırbaş, Medicana Çamlıca Hastanesi Üsküdar, İstanbul
GSM: +905053480151 F.: +90 2164431836 E-Mail: ahmetkirbas@gmail.com

Introduction

Infective endocarditis is associated with substantial morbidity and mortality. Several published studies have reported in-hospital mortality of 15% to 20% and 1-year mortality of 40%. A variety of complications contribute to the high rates of morbidity and mortality in infective endocarditis, particularly heart failure (HF), which occurs in approximately 40% of patients.[1] We report a case of an aortic-pulmonary artery fistula secondary to acute bacterial endocarditis and aortic root abscess formation. The patient presented with generalized symptoms and an initial infection , then developed respiratory and cardiac failure necessitating ventilation and inotropic agents.

Case Report

A 60-year-old female with no known previous heart problem was hospitalized because of high fever, dyspnea and fatigue. We suspect the endocarditis that coagulase positive Staphylococcus aureus was isolated from blood cultures. In spite of an appropriate antibiotic regimen, developed associated with congestive heart failure, which required the administration of diuretics and inotropics.Echocardiogram and cathaterization showed severe aortic regurgitation, aortopulmonary fistula, pericardial effusion.(Figure 1,2) We decided the urgent surgical treatment because of hemodynamic deterioration. Cardiopulmonary bypass was instituted using proximal ascending aorta and right atrial single venous cannula; the aorta was crossclamped and the myocardium was protected by cold blood antegrade and retrograde cardioplegia with intermittent cardioplegic reinfusion. The aorta was transected 1 cm above the sinotubular junction. A fistulous connection approximately 2.5 cm in diameter was observed to connect the left coronary sinus to the root of the main pulmonary artery .Aortic valve and infected aortic wall tissues were excised as much as possible.Pulmonary arteriotomy was performed and a fistulous hole was seen in the main pulmonary artery. The defect on the main pulmonary artery was closed with a Contegra® patch and the defect on the aorta was closed with The Contegra® bioprosthesis (valved heterologous bovine juguler vein). The diameter of the aortic root at the level of the annulus was measured using a prosthetic valve measuring device.The mechanical valve (21 mm St.Jude medical) was implanted in the anatomical position.The patient required intraaortic balloon pump(İABP) and inotropic support during the early postoperative period. Although İABP ,inotropic and ventilation support ,the patient developed multiorgan failure as a cause of death at postoperative 63.day.

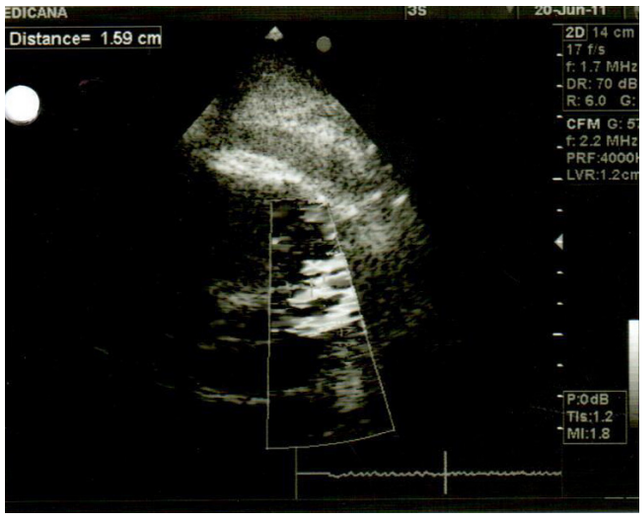

Figure 1:Echocardiography showed that turbulent flow from the fistula between the aorta and the pulmonary artery .

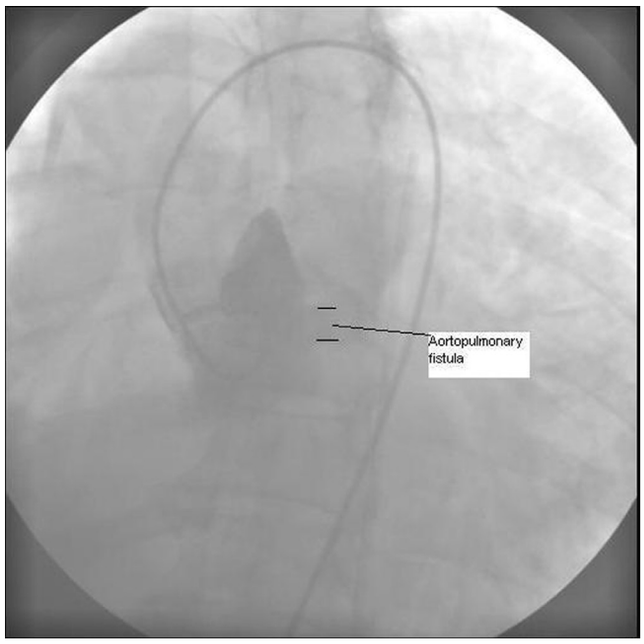

Figure 2. Angiography showed that aortopulmonary fistula during aortic ejection

Discussion

Congenital aortopulmonary fistulas are a well-known condition with congenital heart disease, acquired aortopulmonary fistulas are rare.[2] The etiology of acquired aortopulmonary fistulas includes rupture of aortic aneurysms,trauma, aortic dissection and infective endocarditis with prosthetic aortic valve replacement.Limited reported cases in which aortopulmonary fistulas developed after aortic valve replacement with a mechanical valve due to infective endocarditis.[3]Vieweg et all report that aortopulmonary septal defect due to staphylococcal endocarditis.[4]But to our knowledge that extremely rare case of an aortopulmonary fistula following native aortic valve endocarditis. The aortic valve is the most-common infected site in infective endocarditis (IE), accounting for approximately % 40-67 of the total infected IE sites .The optimal surgical method and type of valve in the presence of native valve endocarditis still controversial. Aortic valve replacement (AVR:mechanical valve, bioprosthesis or homograft) is recommended as a standard surgical procedure for most patients with symptomatic aortic valve disease. [5] Sweeney et al. , in a study of 185 patients with valve replacement for IE (65% aortic valve), found a survival advantage at 4 years (excluding operative deaths) for mechanical versus bioprosthetic valves.[6] In a meta-analysis of 32 articles describing 15 mechanical and 23 biologic valve series totalling 17 439 patients, Lund et al. found no significant difference in death rate between patients with mechanical and those with bioprosthetic valves with correction for age and well-known risk factors.[7] We known that patients with aortic valve IE receiving bioprosthetic AVR had a significantly lower overall 5-year survival rate than patients receiving mechanical AVR, especially patients <65 years because of high mortality in patients with bioprosthetic replacement is probably due to more deaths from primary valve failure and bioprostheses are usually used for elderly patients

or for young patients with co-morbidities such as liver disease history, which could have an unfavourable impact on life expectancy.For this reasons we used the mechanical valve prosthesis for the our patient.Musci et al significant risk factors for early mortality were found: preoperative development of septic shock, preoperative high doses of catecholamines , surgery performed in an emergency, preoperative necessity of ventilation or development of pulmonary oedema and abscess formation. The complication rate of ACF is high.Over % 60 of patients with ACF in different studies developed significant heart failure and over % 40 died. In agreement with these studies moderate or severe heart failure was a significant independent risk factor for death.[8]

Conclusion

Combination of paraaortic abscess and aortopulmonary fistula describe very limited report in mechanical valve endocarditis but extremely rare report this combination in native aortic endocarditis.Surgery for active infective endocarditis with paraaortic abscess and aortopulmonary fistula continues to be challenge.

Competing interests

The authors declare that they have no competing interests.

References

1.Thuny F, Habib G. When should we operate on patients with acute infective endocarditis? Heart 2010;96(11):892–7.
2. Arnett EN, Roberts WC. Clinicopathologic analysis of 22 necropsy patients with comparison of observations in 74 necropsy patients with active endocarditis involving natural left sided cardiac valves. Am J Cardiol 1976;38:281–92.
3. Aragam JR, Keroack MA, Kemper AJ. Doppler echocardiographic diagnosis of aortopulmonary fistula following aortic valve replacement for endocarditis. Am Heart J 1989;117:1392-4.
4. Vieweg WV, Oury JH, Tretheway DG, Mattern AL. Aortopulmonary septal defect due to staphylococcal endocarditis. Chest 1974;65:101-3.
5. David TE, Gavra G, Feindel CM, Regesta T, Armstrong S, Maganti MD.Surgical treatment of active infective endocarditis: a continued challenge. J Thorac Cardiovasc Surg 2007;133(1):144-9.
6. Sweeney MS, Reul Jr GJ, Cooley DA, Ott DA, Duncan JM, Frazier OH, Livesay JJ. Comparison of bioprosthetic and mechanical valve replacement for active endocarditis. J Thorac Cardiovasc Surg 1985;90(5):676—80.
7. Lund O, Bland M. Risk-corrected impact of mechanical versus bioprosthetic valves on long-term mortality after aortic valve replacement. J Thorac Cardiovasc Surg 2006;132(1):20—6.
8. Bayer AS, Bolger AF, Taubert KA et al. Diagnosis and management of infective endocarditis and its complications. Circulation 1998;98:2936–48.