

Mediastinal Irrigation in the Treatment of Descending Necrotizing Mediastinitis

Desendan Nekrotizan Mediastinit Tedavisinde Mediastinal İrrigasyon

Desendan Nekrotizan Mediastinit / Descending Necrotizing Mediastinitis

Ülkü Yazıcı, Ertan Aydın, Ali Çelik, Serdar Özkan, Nurettin Karaoğlanoğlu
Atatürk Göğüs Hastalıkları ve Göğüs Cerrahisi, Eğitim ve Araştırma Hastanesi, Göğüs Cerrahisi Kliniği, Ankara, Türkiye

Özet
Desendan nekrotizan mediastinit, morbidite ve mortalite riski oldukça yüksek seyreden, nadir görülen klinik bir durumdur. Erken tanı, etkin antibiyoterapi ve cerrahi drenaj tedavi yönetiminin temel prensibini oluşturmaktadır. Kliniğimizde DNM nedeniyle takip ve tedavi edilen iki olgunun tedavi stratejisini sunmak ve daha önceki çalışmalar ile sonuçları karşılaştırmayı amaçladık. Mortalite riski yüksek bu durumun tedavisinin mediastinal ve plevral irrigasyon ile birlikte cerrahi drenaj ve debridman olduğu kanaatindeyiz.

Anahtar Kelimeler
Desendan; Nekrotizan; Mediastinit; Cerrahi; İrrigasyon

Abstract
Descending necrotizing mediastinitis (DNM) is a rare clinical condition associated with high risk morbidity and mortality rate. Early diagnosis, effective antibiotherapy, and surgical drainage constitute the main principle of management. We present our treatment strategy of two cases of DNM and compare our results with previous studies. We believe the treatment of this high mortality rate condition should include both mediastinal and pleural irrigation together with complete surgical drainage and debridement

Keywords
Descending; Necrotising; Mediastinitis; Surgery; Irrigation

DOI: 10.4328/JCAM.1042 Received: 23.04.2012 Accepted: 15.05.2012 Printed: 01.05.2015 J Clin Anal Med 2015;6(3): 412-415
Corresponding Author: Serdar Özkan, Atatürk Göğüs Hastalıkları ve Göğüs Cerrahisi Eğitim ve Araştırma Hastanesi, Sanatoryum Cad. 06280 Keçiören, Ankara, Türkiye. F: +90 3123552135 E-Mail: drozkan78@yahoo.com

Introduction

Acute mediastinitis is a severe infection of the mediastinal organs and connective tissues. The most common causes are esophageal perforation and infection following sternotomy [1]. DNM is the most mortal of mediastinal infections. It is most often seen after infections following oropharyngeal, odontogenic, cervicofacial or cervical trauma [2]. The mortality rate is reported to be between 25-40% [3]. Poor prognostic factors include late diagnosis, inadequate medical treatment and surgical drainage [4]. Appropriate antibiotic treatment and surgical drainage are crucial for the management of DNM. The type of surgical drainage depends on the location and extent of the infection. Our objective is to present our treatment approach of DNM with the use of mediastinal irrigation technique and compare our results with previous literatures.

Case Report 1

A 21 year old female patient with fever and tooth ache was diagnosed with second molar tooth abscess and treatment with antibiotics was started. She was referred to our center when she developed shortness of breath 5 days after treatment. On admission, her general condition was moderate; she had high fever and respiratory distress; physical examination revealed swelling and tenderness on the neck; and her breath sounds were bilaterally reduced. Anterior and lateral view cervical x-rays revealed air around the trachea. Chest x-ray revealed enlargement of the mediastinum with air and bilateral pleural effusion. Cervical and thoracic computed tomography (CT) revealed bilateral air and fluid levels from the cervical region extending to the carina and bilateral pleural effusion (Figure1). The patient was diagnosed with DNM, and bilateral chest tube thoracostomy was performed. Empyematous pleural drainage was observed. With transcervical approach of mediastinum drainage was done and approximately 300cc infectious fluid drained. Both mediastinal and pleural fluids were taken for the laboratory investigation. A catheter was inserted in the mediastinal area allowing a daily irrigation of the mediastinum with 500 mg of rifampicin dissolved in saline (2000cc/day), and simultaneous irrigation of both chest tubes with 2000cc/day saline (Figure 2). Broad-spectrum antibiotics were started empirically and modified after the culture and sensitivity results became available. Mediastinal and pleural irrigation was done daily. On the 4th day of treatment, a controlled cervical and chest CT showed the persistence of fluid in the mediastinum. Then, we've decided to re-operate. After simultaneous bilateral exploration with thoracoscopic surgery, mini-thoracotomy debridement of the mediastinum and pleura was performed. The mediastinal space was opened to join the pleural space; 2000-3000ml saline was used to irrigate the thoracic cavity and culture specimens obtained. After surgery, mediastinum and pleural irrigations were continued. Antibiotics were modified after culture and antibiogram results became available. The mediastinal catheter was removed after mediastinal drainage into the thorax tube ceased, and the thorax tubes were removed after drainage seized and culture was negative. The patient after 10 months following surgery is alive and doing well.

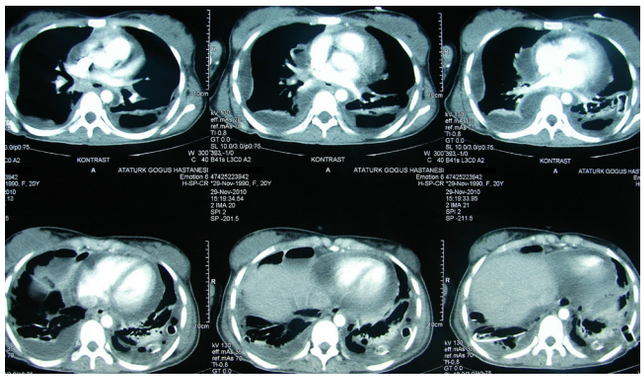

Figure1. Thoracic CT shows bilateral air and fluid levels and bilateral pleural effusion



Figure2. View of the catheter inserted in the mediastinal area

Case Report 2

A 36 year old male patient with fever, shortness of breath and fatigue for 3 days was referred to our center. His general condition was moderate with high fever and respiratory distress due to untreated tooth abscess. Physical examination revealed decreased breath sounds in both lower zones of the lungs. Elevated leucocytes (14,000) and CRP (29.8) was noticed in his laboratory findings. Chest x-ray revealed enlargement of the mediastinum and bilateral pleural effusion. Emergent cervical and thoracic CT revealed air and fluid levels in the cervical region extending to the paracardiac region with bilateral pleural effusion. Bilateral chest tubes thoracostomy and transcervical mediastinum drainage were done. A catheter was inserted into the mediastinal region and daily irrigation with 500mg of rifampicin dissolved in saline (2000cc/day), and simultaneous irrigation of both chest tubes with 2000cc saline were done daily. A broad-spectrum antibiotic was started after fluids were sent for culture. On the 3rd day of treatment, the general condition started deteriorating, he had developed high fever and respiratory distress. Opting for a controlled cervical and thoracic CT which revealed persistence fluid in the mediastinum, we therefore decided to operate. Mediastinal and pleural debridement were done, and the mediastinal space was opened into the pleural space via right thoracoscopic surgery and left mini-thoracotomy (Figure 3). The thoracic cavity was irrigated with 2000-3000ml serum saline and culture specimens obtained. On postoperative day 2 the patient was intubated because his general condition was deteriorating, with a high fever and respiratory distress. Control thoracic CT taken revealed loculated fluid in the paracardiac region on the right side where we performed thoracoscopic surgery, showing insufficient drainage. Via right mini-thoracothomy, the mediastinal pleura was opened and infected material removed from both the mediastinal and pleural space and partial decortication performed. Postoperative medi-

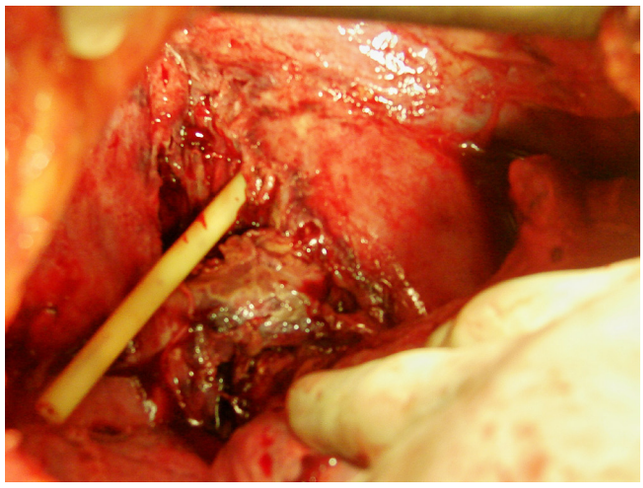

Figure3. Intraoperative view of the catheter inserted in the mediastinal area

astinal and pleural irrigation was continued during postoperative period. The mediastinal catheter was removed after drainage from the mediastinum into the chest tube ceased. On the 34th day of admittance to our clinic, the general condition was better and the patient was discharged from the intensive care unit to the ward. The chest tubes were removed after drainage seized and pleural fluid culture was negative. The patient after 6 months following surgery is alive and doing well.

Discussion

DNM is an acute polymicrobial infection of the mediastinum. Originating as an oropharyngeal or cervical infection, it descends into the mediastinum, pleural space, pericardium and abdomen using the contiguous deep spaces of the neck as portals of entry. It is most frequently seen in developing countries where treatment of dental and oropharyngeal infection is ineffective. It is seen most often after second or third tooth molar abscess, retropharyngeal abscess, peritonsillar abscess and cervical lymphadenitis [5]. In both our cases DNM occurred following molar tooth abscess.

The causative infectious agents are polymicrobial, aerobic and anaerobic microorganisms. Estrera and colleagues have reported that the most common isolated anaerobic bacteria in DNM to be Str. anaerobicus, Bacteroides, and Fusobacterium sp [6]. Sancho and colleagues also reported Bacteroides fragilis (%71) to be the most common anaerobic, and Pseudomonas aeruginosa (%43) as the most common aerobic [7]. In our cases we noticed Pseudomonas aeruginosa to be the common anaerobic, and Bacterioides fragilis as the common aerobic bacteria.

Hasegawa and colleagues classified DNM into 3 groups [7]. Type I DNM is localized to the upper mediastinum above the trachea bifurcation. Generally aggressive mediastinal drainage is not required in Type I DNM. In type IIA DNM, the infection is in the lower anterior mediastinum, while in type IIB DNM involves the lower anterior and extends to the posterior mediastinum. In this group of patients complete mediastinal drainage with debridement is required. Our two cases were type IIB and complete mediastinal drainage and debridement were performed.

Fever and respiratory distress are the most commonly noticed symptoms in DNM. Generally, CRP and leucocytes are elevated, and sepsis develops within a very short period.

Onset of epiglottitis requires emergent operation because of the risk of airway blockage; adult respiratory distress syndrome is a sign of late diagnosis. Patients with respiratory distress need early intubation. To avoid the risk of intubation/ re-intubation difficulties that develop after massive edema of the upper tract or prevent trachea injury, tracheostomy should be performed without delay.

We believe cervicothoracic CT is diagnostic when there is suspicion for DNM. The accumulation of air or fluid in the cervical and mediastinum region, pleural and/or pericardial effusions are important signs in diagnosing DNM. Cervical and thoracic CT are also helpful in the follow up period; they reveal persistent fluid or other infection focuses and also determine whether additional surgical procedure is required or not. In our cases we used cervicothoracic CT in the diagnosing and follow-up period. We decided to re-operate on our second patient based on CT findings.

In the first modern series of patients with DNM published in 1938, Pearse reported that 49% of patients died during their treatment [9]. Base on these results, a standard transcervical and transthoracic approach is recommended for all DNM patients. Corsten and colleagues reported 19% mortality when they combined transthoracic with transcervical mediastinal drainage approach compared to a 47% mortality rate when only transcervical mediastinal drainage was used. Based on this result, they recommended transcervical and transthoracic mediastinal drainage as the standard approach in the treatment of DNM [10]. Marty-Ane and colleagues [11] in a report where they treated 12 DNM patients with early transthoracic mediastinal drainage reported a 16.5% mortality, Freeman and colleagues in a 10 DNM series treated with combined transcervical and transthoracic drainage had no mortality [12]. Papalia and colleagues reported a 23% mortality rate in a series of 13 DNM cases all treated with transcervical mediastinal drainage; in 10 of the cases additional transthoracic approach was done [1]. Iwata and colleagues in a 10 DNM series treated with combined transcervical and transthoracic drainage reported a 20% mortality rate. In their study they continued mediastinopleural irrigation with a daily or twice daily application of 1000-2000 ml saline until the culture result became negative [13]. In addition to the transcervical and transthoracic approach we used in the treatment of our 2 patients, irrigation of both cervical and transthoracic regions was also done. We believe irrigation of the mediastinal and pleural space assists in irrigating the infectious foci and hence increases the success rate in the treatment of DNM.

Late diagnosis and insufficient drainage are responsible for the higher mortality rate in DNM. Only broad- spectrum antibiotherapy is not sufficient in the treatment when mediastinal drainage is not well done. The gold standard of treatment is debridement and drainage of necrotic tissue. The surgical approach in the treatment of DNM is still controversial. There are reports recommending the use of a subxiphoid approach, clamshell incision, median sternotomy, or a thoracoscopic approach. Authors advocating the use of median sternotomy claim the wide exposure of the infection area as an advantage, whiles authors opposing the use of sternotomy claim the risk of sternal osteomyelitis and insufficient exposure of the posterior basal area of the left hemithorax [14]. There is literature reporting the

use of minimal invasive approach of thoracoscopic surgery to be enough and applicable in the treatment of DNM [15]. In our clinical experience thoracotomy was superior over thoracoscopic surgery in terms of mechanical debridement, and with thoracotomy the expected complete mediastinopleural connection was established after failure with thoracoscopic surgery. The most important part of the surgery is to create a connection so that the mediastinal infection drains into the pleural space. When this connection is not established the infected necrotic areas persist and treatment becomes unsuccessful. Transcervical mediastinal irrigation helps drainage of the mediastinal area into the pleural space and excretion from the body via the chest tubes.

Conclusion

In summary, DNM still remains a life-threatening infection, and early diagnosis with appropriate treatment is a must. Transcervical and transthoracic approach are surgical techniques we prefer, and we believe simultaneous mediastinal and pleural irrigation should be considered to be an inseparable part of the treatment. We also support the initial use of thoracoscopic surgery as the first line of surgery and when debridement is insufficiently done or the mediastinopleural connection is not well established, thoracotomy approach should be used without hesitation.

Competing interests

The authors declare that they have no competing interests.

References

1. Papalia E, Rena O, Oliaro A, Cavallo A, Giobbe R, Casadio C, et al. Descending necrotizing mediastinitis: surgical management. Eur J Cardiothorac Surg 2001;20(4):739-42.
2. Erol ME, Ural A, Tekinbaş C, İmamoğlu M, Koşucu M. Nakış İğnesi ile Diş Temizliği Sonrası Gelişen Desendan Nekrotizan Mediyastinit Olgusu. J Clin Anal Med 2012;3(2):218-20.
3. Freeman RK, Vallieres E, Verrier ED, Karmy-Jones R, Wood DE. Descending necrotizing mediastinitis: An analysis of the effects of serial surgical debridement on patient mortality. J Thorac Cardiovasc Surg 2000;119(2):260-7.
4. Metin M, Küçükyağcı N, Turna A, Sayar A, Alzafer S, Sayan MA. Desendan nekrotizan mediyastinit: Diş apsesinin bir komplikasyonu. Toraks Dergisi 2004;5(2):124-6.
5. Zachariades N, Mezitis M, Stavrinidis P, Konsolaki-Agouridaki E. Mediastinitis, thoracic empyema, and pericarditis as complications of a dental abscess: report of a case. J Oral Maxillofac Surg 1988;46(6):493-5.
6. Estrera AS, Landay MJ, Grisham JM, Sinn DP, Platt MR. Descending necrotizing mediastinitis. Surg Gynecol Obstet 1983;157(6):545-52.
7. Sancho LM, Minamoto H, Fernandez A, Sennes LU, Jatene FB. Descending necrotizing mediastinitis: a retrospective surgical experience. Eur J Cardiothorac Surg 1999;16(2):200-5.
8. Hasegawa T, Endo S, Sohara Y. Classification of descending necrotizing mediastinitis. Ann Thorac Surg 2000;69(4):1296.
9. Pearse HE. Mediastinitis following cervical suppuration. Ann Surg 1938;108(4):588-611.
10. Corsten MJ, Shamji FM, Odell PF, Frederico JA, Laframboise GG, Reid KR, et al. Optimal treatement of descending necrotising mediastinitis. Thorax 1997;52(8):702-8.
11. Marty-Ane CH, Alauzen M, Alric P, Serres-Cousine O, Mary H. Descending necrotizing mediastinitis. Advantage of mediastinal drainage with thoracotomy. J Thorac Cardiovasc Surg 1994;107(1):55-61.
12. Freeman RK, Vallieres E, Verrier ED, Karmy-Jones R, Wood DE. Descending necrotizing mediastinitis: An analysis of the effects of serial surgical debridement on patient mortality. J Thorac Cardiovasc Surg 2000;119(2):260-7.
13. Iwata T, Sekine Y, Shibuya K, Yasufuku K, Iyoda A, Lizasa T, et al. Early open thoracotomy and mediastinopleural irrigation for severe descending necrotizing mediastinitis. Eur J Cardiothorac Surg 2005;28(3):384-8.
14. Gorlitzer M, Grabenwoeger M, Meinhart J, Swoboda H, Oczenski W, Fiegl N, et al. Descending necrotizing mediastinitis treated with rapid sternotomy followed by vacum-assisted therapy. Ann Thorac Surg 2007;83(2):393-6.
15. Cho SJ, Kim YD, Hoseok I, Lee SK, Jeong YJ. Treatment of mediastinitis using video-assisted thoracoscopic surgery. Eur J Cardiothorac Surg 2008;34(3):520-4.