Olgu Sunumu
JCAM
Case Report

Complete Right Main Bronchus Rupture in a Child: Report of a Case

Pediatrik Sağ Ana Bronş Rüptürü: Vaka Sunumu

Bronş Rüptürü / Bronchus Rupture

Altuntas Bayram[1], Ceran Sami[2], Sunam Guven Sadi[3], Cinici Ozkan[1]
[1]Department of Thoracic Surgery, Regional Education and Reserach Hospital, Erzurum,
[2]Department of Thoracic Surgery, Meram Medial Faculty, Necmettin Erbakan University, Konya,
[3]Department of Thoracic Surgery, Selcuk University, Medical Faculty, Konya, Turkey

Bu makale, 2005 yılında III. Ulusal Göğüs Cerrahisi Kongresinde poster bildiri olarak sunulmuştur.

Özet

Ana bronş rüptürü ile sonuçlanan künt göğüs travmaları oldukça nadirdir ve muhtemelen yüksek bir hastane öncesi mortaliteye sahiptir.. Bu yaralanmalar, solunum zorluğu ve eşlik eden yaralanmalardan dolayı yüksek oranda mortaliteye sahiptir. Altı yaşında erkek çocuğu, künt toraks travmasından dolayı kliniğimize kabul edildi. Başka bir merkezde sağ pnömotoraks nedeniyle tüp torakostomi uygulanan hasta yetersiz akciğer ekspansiyonu nedeniyle kliniğimize refere edilmiş. Fizik muayenede orta düzeyde interkostal retraksiyon, taşipne ve siyanoz mevcuttu. Geliş anındaki direkt akciğer grafisinde sağda total pnömotoraks vardı ve hilus inferiora yer değiştirmişti. Hastaya rijid bronkoskopi yapıldı ve sağ ana bronşta total rüptür görüldü. Hastaya sleeve üst lobektomi yapıldı. Bronş rüptürlerinde erken tanı ve tedavinin önemini vurgulamayı amaçladık.

Anahtar Kelimeler

Toraks; Travma; Bronş Rüptürü

Abstract

Blunt chest trauma resulting in rupture of a main bronchus is rare and probably have a high prehospital mortality.These injuries are often fatal because of respiratory distress and the high frequency of associated multiple organ injuries. A six-year-old boy was admitted our clinic due to blunt chest trauma. The tube thoracostomy was performed for the right pneumothorax at another surgical center. He was referred to our clinic due to inadequate expansion of the lung. On the physical examination, there was middle intercostal retraction, cyanosis and tachypnoea. The initial chest x-ray showed total pnemothorax on the right side and the hilum replaced by inferiorly. The rigid bronchoscopy was performed and the the rupture of main bronchus was seen. The sleeve upper lobectomy was performed. We aimed to emphasize the important of early diagnosis and treatment in the bronchial ruptures.

Keywords

Thorax; Trauma; Bronchus Rupture

DOI: 10.4328/JCAM.1056 Received: 30.04.2012 Accepted: 15.05.2012 Printed: 01.05.2015 J Clin Anal Med 2015;6(3): 410-411
Corresponding Author: Bayram Altuntas, Regional Education and Reserach Hospital, Department of Thoracic Surgery 25000, Erzurum, Turkey.
E-Mail: draltuntas@hotmail.com

Introduction

Blunt chest trauma resulting in rupture of a main bronchus is rare and probably have a high prehospital mortality [1,2]. These injuries are often fatal because of respiratory distress and the high frequency of associated multiple organ injuries [3]. Symptoms of bronchial rupture include dyspnea, subcutaneous emphysema, and related others injuried organs. In 76% of patients, the injury occurs within 2 cm of the carina and in 43% within the first 2 cm of the right main bronchus.[4]. The pathophysiologic basis of bronchial rupture may be a sudden increase in intraluminal pressure with a closed glottis, compression of the airway between the sternum and vertebrae, or rapid deceleration [5]. The bronchoscopy is one of the best diagnostic methods. The management of bronchial rupture is surgery, like end-to-end anastomosis, rarely pulmonary resections. Herein, we describe a case of complete right main bronchus rupture in 6-year -old boy diagnosed by chest computed tomography and bronchoscopy after blunt chest trauma.

Case Report

A six-year-old boy was admitted our clinic due to blunt chest trauma. The tube thoracostomy was performed for pneumothorax at another surgical center. He was referred to our clinic due to inadequate expansion of the lung. On the physical examination, there was middle intercostal retraction, cyanosis and tachypnoea. Breath sounds were diminished on the right side. The hemogloin, hematocrit and leucocyte values are 9.7 gm/dl, 30.2 % and 13.4x103 cells/ml, respectively

The initial chest x-ray showed total pneumothorax on the right side and the hilum replaced by inferiorly, fallen lung sign (figure 1). Additionally, there was cut-off sign for the right main bronchus on the CT scan. The rigid bronchoscopy was performed and the the rupture of main bronchus was seen . The patient was positioned for the thoracotomy. The lateral thoracotomy was performed. The intermedier bronchus and upper lobe bronchus had ruptured, independently (figure 2). The sleeve upper lobectomy was performed due to granulation of upper lobe bronchus. Postoperative period is eneventful.

Discussion

Bronchial rupture due to blunt trauma in children is more frequent in males than females, most commonly involves the adolescent age group [6]. The “fallen lung” sign on the chest roentgenogram, inadequate expansion of the lung, massive air leak and the atelectatic lung are high specificity for bronchial rupture [7]. Bronchial ruptures usually ocur within 2.0 cm of the carina [4]. Bronchoscopy provides a definitive diagnosis but thoracotomy may necessary in some cases [8]. Chest X-ray is the basic imaging procedure, but CT scan has proven helpful in visualizing the level of the rupture [9].

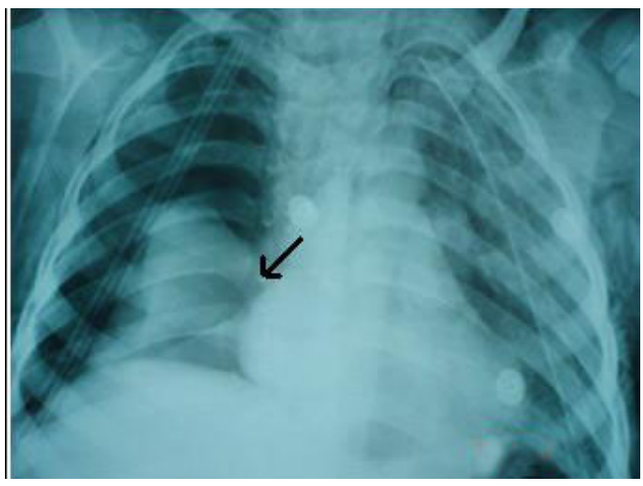

Figure 1. The right hilum replaced by inferiorly (black arrow).

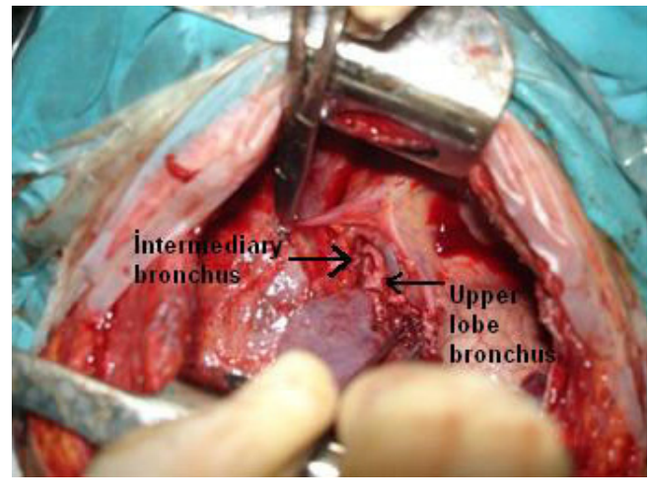

Figure 2. The intermedier bronchus and upper lobe bronchus had ruptured, independently.

In this case report, a-six- year old boy presented with complete right main bronchus rupture. In keeping with the clinical scenario, radiologic findings and physical examination, the initial diagnosis was bronchial rupture. The rigid bronchoscopy was necessary to proven this diagnosis.

Although the choiced treatment is end-to-end anastomosis, we performed to sleeve upper lobectomy. Because, the patient was referred to our clinic three days after trauma, and there was granulation in the upper lobe bronchus. Postoperative period was uneventfull.

The prognosis of bronchial ruptures is often related to the severity of associated injuries. Over the long term, bronchial stenosis after primary repair of a bronchial rupture may be seen [2]. Our patient is in the seventh years, and there was no bronchial stenosis.

In conclusion, rupture of the main bronchus is uncommon. It is serious complication of blunt thorax trauma in childhood. The early diagnosis and surgical intervention can be possible with complete functional and paranchymal preservation of the lung.

Competing interests

The authors declare that they have no competing interests.

References

1. Symbas PN, Justicz AG, Ricketts RR. Rupture of airways from blunt trauma. Treatment of complex injuries. Ann Thorac Surg 1992;54(1):177–83.
2. Yalçınkaya I, Biliciler U. Traumatic bronchial rupture. Eastern Journal of Medicine 1999;4(1):39-41, .
3. Mahajan JK, Menon P, Rao KL, Mittal BR. Bronchial transection: delayed diagnosis and successful repair. Indian Pediatr 2004;41:389–92.
4. Kiser AC, O'Brien SM, Detterbeck FC. Blunt tracheobronchial injuries: treatment and outcomes. Ann Thorac Surg 2001;71:2059-65.
5. Long J, Reynolds E, Wong J, LaSpada J. Traumatic airway disruption in children. J Trauma 2001;51:1200–3.
6. Gwely NN. Blunt Traumatic Bronchial Rupture in Patients Younger than 18 Years. Asian Cardiovasc Thorac Ann 2009;17:598-603
7. Lee RB. Traumatic injury of the cervicothoracic trachea and major bronchi. Chest Surg Clin North Am 1997;7(2):285-304,
8. Kiliç N, Gürpinar AN, Kiriştioğlu I, Doğruyol H. Blunt traumatic rupture of the main bronchus in children. Eur J Surg 2000;166:968-70.
9. Poli-Merol ML, Belouadah M, Parvy F, Chauvet P, Egreteau L, Daoud S. Tracheobronchial injury by blunt trauma in children: is emergency tracheobronchoscopy always necessary? Eur J Pediatr Surg 2003;13:398-402.