The Effect of Erythropoietin on S100 Protein Expression in Cochlea After Acoustic Overstimulation: An Experimental Study

Eritropoetinin Gürültü Uygulaması Sonrası Kokleada S100 Proteini Ekspresyonuna Etkisi: Deneysel Çalışma

Gürültü Sonrası Kokleaya Eritropoetinin Etkisi / Effect of Erythropoietin on Cochlea After Acoustic Overstimulation

Seren Gülşen Gürgen[1], Oğuzhan Gürgen[2], Günay Kırkım[3], Hatice Efsun Kolatan[4], Selhan Gürkan[3], Görkem Eskiizmir[5]
[1]Celal Bayar University, School of Vocational Health Service, Department of Histology and Embryology, Manisa,
[2]Clinic of Otorhinolaryngology, Selçuk State Hospital, Izmir, [3]Dokuz Eylül University, Faculty of Medicine, Department of Otorhinolaryngology, Izmir,
[4]Dokuz Eylül University, Faculty of Medicine, Department of Laboratory of Animal Science, Izmir,
[5]Celal Bayar University, Faculty of Medicine, Department of Otorhinolaryngology-Head and Neck Surgery, Manisa, Turkey

Çalışmamız 10-14 Ekim 2012 tarihleri arasında Antalya'da düzenlenen "34.Türk Ulusal Kulak Burun Boğaz ve Baş Boyun Cerrahisi Kongresi"nde "Eritropoetinin Akustik Travmaya Bağlı Koklear Hasarlanma Üzerine Etkisi: Çok Merkezli Deneysel Bir Çalışma" başlığıyla sözlü olarak sunulmuştur.

Çalışmamız Celal Bayar Üniversitesi Bilimsel Araştırma Projeleri Başkanlığı tarafından desteklenmiştir. [Proje numarası: 2010-052]

Özet

Amaç: Çalışmamızda Eritropoetinin, gürültü ile uyarılmış sıçan spiral ganglion nöronlarında S100 proteini dağılımına etkisinin, immunohistokimyasal yöntem ile araştırılması amaçlandı. Gereç ve Yöntem: Yirmi-iki Wistar albino sıçan üç gruba ayrıldı: sağlıklı kontrol grup (n=7), Serum fizyolojik enjeksiyon grubu (n=7) ve Eritropoetin enjeksiyon grubu (n=8). Serum fizyolojik ve Eritropoetin enjeksiyon gruplarına 3 saat süre ile beyaz gürültü (100 dB SPL) uygulandı. Koklea kesitleri gümüşleme yöntemi ile histokimyasal olarak ve S100 antikoru ile immunohistokimyasal olarak boyandı. Bulgular: Gümüşleme yöntemine göre sağlıklı kontrol grubu spiral ganglion nöronlarında normal yapı ve zayıf bir boyanma gözlendi. Serum fizyolojik enjeksiyon grubu ganglion nöronlarının sitoplazmasında koyu-siyah boyanma ve dejeneratif görünüm belirlendi. Eritropoetin enjeksiyon grubunda ise az sayıda nöronun koyu boyandığı izlendi. S100 immunohistokimyasal boyamasına göre, sağlıklı kontrol grubunda Schwann hücrelerinde ve myelin lamellerde kuvvetli reaksiyon gözlendi ($p<0.05$). Serum fizyolojik enjeksiyon grubunda Schwann hücrelerinde orta şiddetli S100 reaksiyonu izlenirken spiral ganglion nöronlarının diğer bölgelerde zayıf reaksiyon vardı ($p<0.05$). Eritropoetin enjeksiyon grubunda yer yer bazı bölgelerde azalma olsa da, doku genelinde sağlıklı kontrole benzer kuvvetli S100 ekspresyonu tespit edildi. Tartışma: Eritropoetin sıçan kokleasında gürültü ile indüklenmiş SGN dejenerasyonunu, Schwann hücrelerini koruyarak engeleyebilir.

Anahtar Kelimeler

Koklea; Akustik Travma; Eritropoetin; S100; İmmunohistokimya

Abstract

Aim: To investigate the effect of Erythropoietin on acoustically overstimulated rat spiral ganglion neurons (SGNs) using S100 protein immunostaining. Material and Method: Twenty-two Wistar albino rats were divided into three groups: healthy control group (n=7), Saline solution (n=7) and Erythropoietin injection groups (n=8). Saline solution and Erythropoietin injection groups received white noise (100 dB SPL) for 3 hours. Cochlear sections were stained by silver staining technique and immunostained by S100 antibody. Results: Histochemical analysis of silver staining sections revealed normal structure and a weak staining in SGNs of healthy control group. However, dark-black cytoplasmic staining, cellular shrinkage and degeneration were detected in saline injection group. On the other hand, a few weakly stained neurons were observed in erythropoietin injection group. S100 staining demonstrated strong reaction in Schwann cells and myelin sheaths of SGNs in healthy control group ($p<0.05$). In saline solution injection group, Schwann cells showed moderate S100 reaction and other regions of SGNs showed weak reaction ($p<0.05$). In erythropoietin injection group, strong S100 expression almost similar to the healthy control group was determined, although there was an occasional decrease. Discussion: Erythropoetin may prevent noise induced SGN degeneration via protecting the Schwann cells in rat cochlea.

Keywords

Cochlea; Acoustic Trauma; Erythropoietin; S100; Immunohistochemistry

DOI: 10.4328/JCAM.2009 Received: 10.08.2013 Accepted: 31.08.2013 Printed: 01.05.2015 J Clin Anal Med 2015;6(3): 327-331
Corresponding Author: Seren Gülşen Gürgen, Celal Bayar University, School of Vocational Health Service, Uncubozköy Manisa, Turkey.
T.: +90 2362371378 F.: +90 2362320058 E-Mail: serengurgen@gmail.com

Introduction

Intense noise may cause hearing loss depending on the sound intensity and frequency, and individual sensitivity. Intense noise exposure may lead to hearing loss especially by targeting and affecting the cochlea and its structures [1]. The basic mechanisms underlying noise-induced hearing loss are: altered microcirculation, increased free oxygen radical formation and activation of apoptosis [1]. Although the outer hair cells are the most sensitive structures to noise, inner hair cells, spiral ganglia, spiral ligaments and spiral limbus have also been shown to be affected by acoustic trauma [2].

A variety of degenerations may develop in spiral ganglion neurons (SGNs) and primary afferent neurons of the cochlea following sensorineural hearing loss. The most important of these is gradual myelin degeneration in SGN bodies in Rosenthal's canal and peripheral nerves in the osseous spiral lamina after rapid and widespread loss of myelination in Organ of Corti [3]. The degenerative phase is generally completed with a decrease in the number of myelin lamellae surrounding the SGNs. The decrease in myelin lamellae initially begins in peripheral parts and increasingly affects the central regions of auditory nerves [4]. Myelin deficiency has been observed around the SGNs of chronically deafened experimental animals [4,5]. Demyelination leads to a loss of neural membrane resistance which reduces the effectiveness of a neuron in initiating the response to electrical stimulation and transmission of action potential [6]. The myelin of peripheral nervous system is generated by Schwann cells. There are several markers of Schwann cells (such as P75, connexin 29, S100, myelin basic protein, Sox10 and PO) and these are shown in cochlea using immunostaining or in situ hybridization techniques [7]. It has been shown that S100 protein appears as a maturation signal in fetal inner ear membranes, cochlear epithelium and spiral ligaments [8]. S100 proteins are known to be involved in cell-cell communication, cell structure and growth, energy metabolism and intracellular signal transmission. They also play important roles in brain growth and regeneration. Moreover, they play a remarkable role in neuronal differentiation and maturation [7].

Erythropoietin (Epo) is a well-known hematopoietic cytokine and also exhibits a protective effect on nervous system. Erythropoietin and its receptor have been shown to be expressed in neural tissue [9]. In addition, Epo is known to have antioxidant, anti-inflammatory and antiapoptotic effects [9]. The results of studies which examined the effect of Epo on models of cochlear injury, are controversial. In an experimental study, Frederiksen et al. reported that noise-induced hearing loss increased in subjects administered Epo [10]. In contrast, Monge et al. emphasized that Epo has a protective role against auditory hair cell damage in vitro [11]. Therefore, this study was aimed to investigate the amount of myelin degeneration in acoustically overstimulated rats and examine the protective effect of Epo using an immunohistochemical Schwann cell marker S100 protein.

Material and Method

Experimental Animals

Twenty-two female Wistar albino rats weighing 250-350 g and with normal Preyer reflexes were used. All the rats were studied in Experimental Animal Center of Dokuz Eylul University at a constant room temperature (21-22°C) under a 12-hour dark/12-hour light cycle. All experiments were carried out in accordance with the European Communities Council Directive of 24 November 1986 (86/609/EEC) and were approved by the Animal Care Committee of Celal Bayar University. Otoscopic examinations were performed on all animals before the first injection. Animals with no outer/middle ear disease and normal auditory brainstem responses were included in the study. Rats were divided into three groups; (i) a saline solution injection group (SS) administered 0.09% NaCl solution intraperitoneally (i.p.) (n=7), (ii) an Epo injection group administered recombinant human erythropoietin (rhEpo) (n=8) i.p. at a dosage of 2000 IU/kg [12] and (iii) a healthy control group without any injection and not exposed to noise (n=7). Both Epo and saline injections of the same volume (1 ml) were performed 24 hours before and 1 hour before the noise exposure, and afterwards every 24 hours for the following seven days.

Noise Application

White noise at 100 dB SPL was applied to the Epo and SS injection groups for 3 hours. White noise generated by a sound generator including an Interacoustics AC 40 clinical audiometer was reinforced with a specially manufactured amplifier. During exposure to noise, which took place in a sound-proof cabin, each animal was kept awake. Two loudspeakers (Spekon-Audio, Control 80) were placed immediately above the cages. The intensity of sound was routinely measured from the central point of the cage roof with a Brüel & Kjær sound level meter. Care was taken to ensure that any change in sound intensity at the edges of the cage should not exceed 5 dB.

Histochemical Examination

Seven days after noise application, the temporal bones of rats were removed under deep general anesthesia for histopathological examination. After tissues were fixed in neutral formaldehyde for 24 hours, they were stored in EDTA solution for decalcification. Paraffin blocks were subsequently prepared and serial sections of 5µ in thickness taken. One part of the serial sections was stained by silver impregnation technique in order to determine the presence of damage in SGNs. In this technique, argyrophilic staining demonstrated the degenerated neurons [13]. Briefly, neurons and neural axon processes were stained dark-black; however, non-degenerated neurons were stained light yellow.

Immunohistochemical Staining Technique

The other part of the serial sections was set aside for immunohistochemical staining. After being deparaffinized in xylene by incubation at 60°C for one night, they were dehydrated in decreasing alcohol series. Thereafter, they were boiled in citrate buffer (10 mM, pH 6.0) in a microwave for 15 min. They were kept in hydrogen peroxide for 15 min in order to prevent endogenous peroxidase activity. Sections were then incubated for 10 min in blocking serum (Ultra V Block, NeoMarker, Fremont, CA, USA). Sections were incubated for 60 min at room temperature and in a humid environment with primary antibody S100 (Labvision, CA, USA). Antigen antibody complex was identified with biotinylated secondary antibody and streptavidin-peroxidase comp-

lex (20 min). Labeling was performed using AEC (Labvision, CA, USA). Sections were counter stained with Mayer's hematoxylin and covered with mounting medium. Photographs were taken with a microscope with attached camera Olympus CX41 (Germany). Immunohistochemical analysis was performed on cochlea cross-sections for all animals using image-analyzing software (Leica Q Win V3 Plus Image). Control samples were processed in an identical manner, but incubation with the primary antibody was omitted (data not shown). Two observers blinded to experimental information evaluated the immunolabeling scores independently. Ten areas were selected at random at X100 magnification on each preparate and the H-score calculated according to the intensity of staining by the amount of staining percentage. Intensity was scored semi-quantitatively; (0, no staining), 1 (+, weak immunoreactivity), 2 (+ + , moderate immunoreactivity) and 3 (+ + +, strong immunoreactivity). Percentage of staining was calculated as cell/structures with immunoreactivity over total cell/structures; 1 (0 – 10%, focal), 2 (11 – 50%, regional) and 3 (51-100%, diffuse). Intensity and amount scores for each field were calculated using the formula Σ Pi.(i+1) (Pi= percentage of staining, i= intensity of staining). The results were collected and a single value obtained for each slide.

Statistical Analysis

The data obtained were analyzed on SPSS 15.0. Study groups histological values, numbers, percentages and means were taken and Kruskall Wallis, a non-parametric test, was performed. Groups were compared using the Mann Whitney U test. The results were given as mean ± standard deviation. p values lower than 0.05 were accepted to be significant.

Results

A normal SGN structure and weak staining were observed in cochlea sections of the healthy control group (Figure 1A). Dark-black (argyrophilic) staining in the cytoplasm of ganglion neurons, shrinkage in cells and a generally degenerative appearance were notable in SS injection group (Figure 1.B). The number of these cells (31.14 ± 1.57) was also significantly higher compared to the healthy control group (3.14 ± 1.06) ($p<0.05$) (Table 1, Figures 1.A, 1.B). In Epo injection group, some ganglion neuron cells exhibited mild argyrophilic staining, and there was a significant decrease in number of these cells (9.14 ± 1.34) (Figure 1.C) ($p<0.05$). The score of SGN degeneration between the groups based on silver staining technique were summarized in Table 1 and Figure 2.

In S100 immunohistochemical staining, immunoreactivity ranging from moderate to strong was observed in Organs of Corti, inner and outer hair cells and outer phalangeal cells in healthy control and Epo injection groups (Figures 3.A1,C1). However, moderate S100 expression was determined in all cells of Organ of Corti in SS injection group (Figure 3.B1). In contrast, strong S100 expression was observed in spiral ganglia, and particularly in Schwann cells and myelin lamellae around the neurons in healthy control group (Figure 3.A2). Moderate expression in Schwann cells and weak expression in other structures were determined in SS injection group (Figure 3.B2). Strong staining, almost similar to healthy control group despite a slight decrease, was observed in S100 immunoreactions in lamellae of myelin around some neurons and in Schwann cells in Epo injection group (Figure 3.C2).

The comparison of healthy control and SS injection groups revealed significantly higher expression in healthy control group

Table 1. Degenerative ganglion values in the group at silver staining

	Healthy		SS		Epo		p value		
							H-SS	H-Epo	SS-Epo
Degenerative Ganglion	3.14 1.06	±	31.14 1.57	±	9.14 1.34	±	0.000	0.000	0.000

p<0.05 (Kruskall Wallis test). The values are presented as Mean±Standard Deviation.

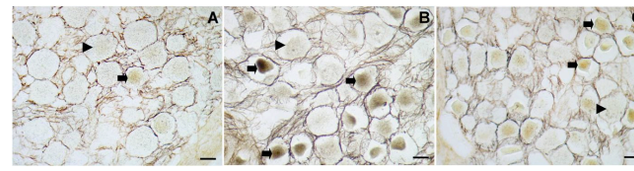

Figure 1: ▶: healthy neuron cell body, ➡: Argyrophilic stained degenerated neuron body Healthy group (A), SS group (B), Epo group (C) Spiral ganglion, silver staining method (X1000) Bar = 5 µm.

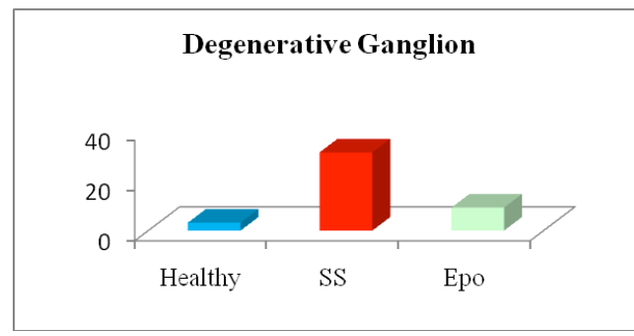

Figure 2. Comparison of degenerative neurons in spiral ganglia by groups.

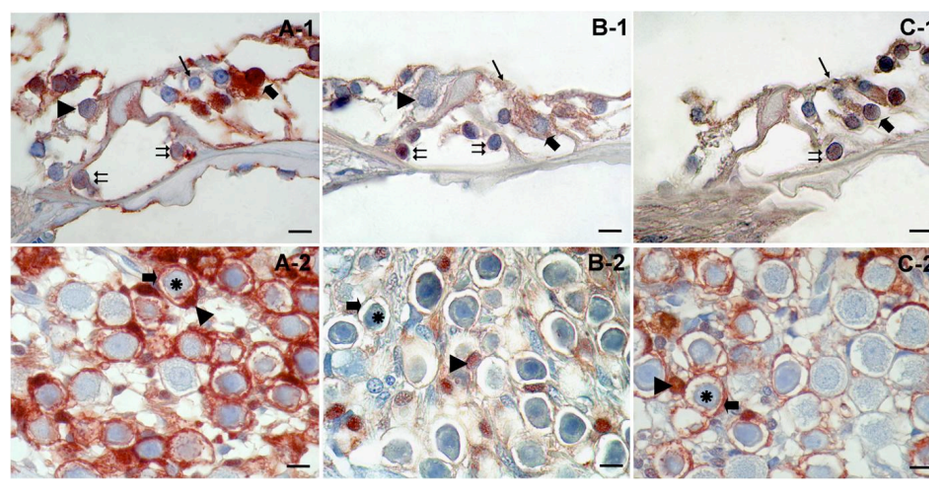

Figure 3. ▶: Inner hair cell, →: Outer hair cells, ➡: Phalangeal cells, ⇉: Outer pillar cells, ⇇: Inner pillar cells, Healthy group (A1), SS group (B1), Epo group (C1) Organ of corti. ✱: Neuron body, ➡: Myelin lamellae, ▶: Schwann Cell, Healthy group (A2), SS group (B2), Epo group (C2) Spiral ganglion S100 immunostaining (X1000). Bar = 5 µm."

in Schwann cells (95.00 ± 2.30) and myelin around the neurons (83.00 ± 2.16) than in SS injection group (37.85 ± 3.02 and 27.70± 2.14) ($p<0.05$). When Epo and SS injection groups were compared according to S100 expression in Schwann cells and myelin, a statistically significant difference in the favor of Epo injection group was determined (65.14 ± 3.02 and 53.00 ± 2.16) ($p<0.05$). In terms of outer phalangeal cells, S100 expression was highest in healthy control group (74.00 ± 2.16). The mean values of outer phalangeal cell S100 expression in three groups were almost similar to each other. H-score values according to S100 expression in outer phalangeal cells, myelin lamellae and Schwann cells were summarized in Tables 2 and Figure 3 and 4.

Discussion

Acoustic trauma is known to have a hazardous effect on SGNs, the primary auditory neurons [2]. In addition, several studies have reported swelling and neural damage in dendrites of SGNs following exposure to loud noise [14,15,]. In our experimental study, acoustic overstimulation induced degeneration of SGNs, cellular and nuclear condensation, and decrease in number of neurons was obviously determined (Figure 3). These results are similar to the reported studies [2,14,15].

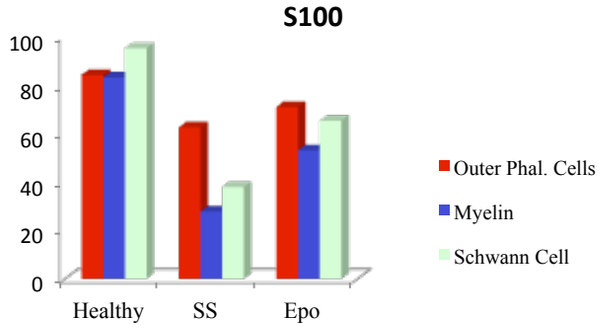

Figure 4. Outer phalangeal cells, myelin and S100 expression in Schwann cells by groups

Table 2. Two-way comparisons of S100 immunohistochemical H scores in the healthy, SS and Epo groups

	Healthy	SS	Epo	p value		
				H-SS	H-Epo	SS-Epo
Outer Phalangeal Cells	84.00 ± 2.16	62.42 ± 1.71	70.85 ± 1.34	0.002	0.002	0.04
Myelin	83.00 ± 2.16	27.70± 2.14	53.00 ± 2.16	0.002	0.002	0.002
Schwann Cell	95.00 ± 2.30	37.85± 3.02	65.14 ± 3.02	0.002	0.002	0.002

H: Healthy, $p<0.05$ (Mann Withney U test). The values are presented as Mean±Standard Deviation.

Myelin is involved in various functions associated with signalization, support and regulating neuronal activities under normal and pathological conditions [16]. The deficiency of myelin around the nerve cell bodies may cause remarkable deceleration in electrical transmission, despite of permitting electrical or metabolic exchange among cells [16]. Nerve transmission in SGN decreases significantly when cochlear myelination is comprised, or in case of deafness [17]. The auditory nerve is covered by myelin, which is mainly synthesized by Schwann cells in peripheral nervous system, while the myelin in central nervous system is generated by oligodendrocytes [17]. Schwann cells can survive despite SGN degeneration persisting in noise induced hearing loss [17].

In this experimental study, the effects of intense noise on SGNs, Schwann cells and myelin was evaluated using S100 protein. This study is the first in which the immune distribution of S100 protein, a Schwann cell and myelin marker, was examined in rat cochlea administered Epo as a protector against acoustic trauma. The morphological studies have shown the importance of Schwann cells after hearing loss. Dodson and Mohuiddin emphasized the presence of large numbers of satellite cells and myelins around surviving SGNs in ototoxic hearing loss [18]. Leake and Hradek observed a large number of satellite and Schwann cells grouped together in long-term sensorineural hearing loss with no surviving neurons and reported that these cells persisted even long after the degeneration of SGNs [4]. The mechanism how Schwann cells survive despite SGN degeneration is not completely known, although this is believed to be associated with mature Schwann cells [19]. In the current study, S100 immunoreaction was strong in healthy control group, particularly in Schwann cells and myelin lamellae. On the other hand, remarkable decrease in Schwann cells of SS injection group was detected, although they were not negative. This also suggested that Schwann cells survive despite intense noise, and this enables some SGNs to survive. In healthy control group, a relatively strong S100 expression in outer phalangeal cells in Organ of Corti, similar to that in Schwann cells was also detected. This suggested that S100 might also be regarded as a survival signal molecule for outer phalangeal cells [20]. The fact that outer phalangeal cells were stained in an intensity varying from moderate to strong in Epo injection group, despite decreasing expressions in SS injection group, demonstrated that these cells may play a role in the protection of outer hair cells against acoustic trauma and application of Epo may enhance their chances of survival.

The protective effect of Epo has been shown through in vitro and in vivo studies involving ischemic, hypoxic, metabolic and neurotoxic damage to the central and peripheral nervous systems [12]. Erythropoietin plays an active role in several stages of injury in neural tissue, such as prevention of free radical production, regulation of neurotransmission, reversal of vasospasm, triggering of angiogenesis, inhibition of apoptosis and regulation of inflammation [21]. This study obviously shows, for the first time in literature, that Epo may have a protective effect on spiral ganglion neurons following exposure to intense noise.

Erythropoietin exhibits its effect by binding to its receptor. Receptor activation stimulates cell proliferation by activating the intracellular signal transmission mechanism and inhibits apoptosis [22]. Monge et al. reported that Epo receptor mRNA is expressed in cochlea, and that gentamicin-associated hair cell loss can be prevented with the administration of Epo [23]. In addition, another study performed on rat cochlea cultures showed that Epo significantly reduces ischemia-related apoptosis and necrosis [24]. In contrast, there is only one study concerning the protective effect of Epo against noise-related hearing loss [10]. Although Frederiksen et al. emphasized the Epo indu-

ced increase of ischemia in cochlea, other studies described the anti-ischemic and angiogenesis-stimulating effects of Epo [24]. In addition, in the trials of Frederiksen et al., Epo was applied to the experimental subjects after noise exposure and administered topically. Erythropoietin was applied systemically (by the intraperitoneal route) in only one trial of that study; however just only 1 hour before noise exposure [10]. The neuroprotective effect of Epo is exhibited through receptor activation and takes place through RNA and protein synthesis; therefore, it has to be administered at least 8 hours before [25]. In this study, Epo treatment was initiated intraperitoneally 24 hours before the application of noise and was maintained for 7 days. Our results obviously showed that Epo may significantly reduce the degenerative changes in SGNs and losses associated with Schwann cell death in spiral ganglia when administered in this schedule.

The current study demonstrated that Schwann cells of Epo injection group exhibited a more powerful S100 expression than SS injection group (Table 2). This suggested that the application of Epo was effective for the protection of Schwann cells against noise, and that it also protected the SGNs. These findings were compatible with the silver staining technique, regarded as a marker of neuronal degeneration. The application of Epo caused significant decrease in the number of neurons suffering degeneration when compared with the SS injection group. These results showed that Epo may have a positive effect on SGNs to survive after acoustic trauma by supporting the Schwann cells.

In conclusion, the positive changes in Schwann cells and SGNs in the group exposed to noise and given Epo had significantly different when compared with the group administered SS. Erythropoietin treatment initiated 24 hours before the application of noise and maintained for 7 days had a positive effect on Schwann cells and SGN survival. The clinical importance of this study is that rhEpo, which has been safely and widely used for years in humans, may also represent a treatment option for acoustic trauma. It will therefore point the way for future researches.

Funding Acknowledgement

This study was supported by a grant from the Celal Bayar University Research Fund, Manisa, Turkey. [Project no: 2010-052].

Competing interests

The authors declare that they have no competing interests.

References

1. Hu BH, Henderson D, Nicotera TM. Involvement of apoptosis in progression of cochlear lesion following exposure to intense noise. Hear Res 2002;166(2):62-71.
2. Eskiizmir G, Yücetürk AV, Inan S, Gürgen SG. Acute spiral ganglion cell degeneration following acoustic overstimulation: an experimental study. ORL J Otorhinolaryngol Relat Spec 2011;73(1):24-30.
3. Hardie NA, Shepherd RK. Sensorineural hearing loss during development: morphological and physiological response of the cochlea and auditory brainstem. Hear Res 1999;128(1-2):147–65.
4. Leake PA, Hradek GT. Cochlear pathology of long term neomycin induced deafness in cats. Hear Res 1988;33(1):11–33.
5. Shepherd RK, Hardie NA. Deafness induced changes in the auditory pathway: implications for cochlear implants. Audiol Neurootol 2001;6(6):305–18.
6. Smith KJ, McDonald WI. The pathophysiology of multiple sclerosis: the mechanisms underlying the production of symptoms and the natural history of the disease. Philos Trans R Soc Lond B Biol Sci 1999;354(1390):1649–73.
7. Donato R. S100: a multi genic family of calci-um-modulated proteins of the EF-hand type with intra cellular and extra cellular functional roles. Int J Biochem Cell Biol 2001;(7)33:637-68.
8. Foster JD, Drescher MJ, Hatfield JS, Drescher DG. Immunohistochemical localization of S-100 protein in auditory and vestibular end organs of the mouse and hamster. Hear Res 1994;74(1-2):67–76.
9. Thomasen PC, Wagner N, Frederiksen BL, Asal K, Thomsen J. Erythropoietin and erythropoietin receptor expression in the guinea pig inner ear. Hear Res 2005;203(1-2):21-7.
10. Frederiksen BL, Thomasen PC, Lund SP, Wagner N, Asal K, Olsen NV et al. Does erythropoietin augment noise induced hearing loss? Hear Res 2007;223(1-2):129-37.
11. Monge NA, Gassmann M, Bodmer D. Erythropoietin but not VEGF has a protective effect on auditory hair cells in the inner ear. Cell Mol Life Sci 2009;66(22):3595-9.
12. Brines ML, Ghezzi P, Keenan S, Agnello D, de Lanerolle NC, Cerami C et al. Erythropoietin crosses the blood-brain barrier to protect against experimental brain injury. Proc Natl Acad Sci USA 2000;97(19):10526-31.
13. Gallyas F, Guldner FH, Zoltay G, Wolff JR. Golgi-like demonstration of "dark" neurons with an argyrophilia. III method for experimental neuropathology. Acta Neuropathol 1990;79(6):620–8.
14. Wright CG. Neural damage in the guinea pig cochlea after noise exposure. A light microscopic study. Acta Otolaryngol 1976;82(1-2):82–94.
15. Wang Y, Hirose K, Liberman MC. Dynamics of noise-induced cellular injury and repair in the mouse cochlea. J Assoc Res Otolaryngol 2002;3(3):248–68.
16. El-Badry MM, Ding DL, McFadden SL, Eddins AC. Physiological effects of auditory nerve myelinopathy in chinchillas. Eur J Neurosci 2007;25(5):1437–46.
17. Shepherd RK, Roberts LA, Paolini AG. Long-term sensorineural hearing loss induces functional changes in the rat auditory nerve. Eur J Neuro 2004;20:3131–40.
18. Dodson HC, Mohuiddin A. Response of spiral ganglion neurones to cochlear hair cell destruction in the guinea pig. J Neurocytol 2000;29(7):525–37.
19. Mirsky R, Jessen KR. Schwann cell development, differentiation and myelination. Curr Opin Neurobiol 1996;6(1):89–96.
20. Zetes DE, Tolomeo JA, Holley MC. Structure and mechanics of supporting cells in the guinea pig organ of Corti. PLoS One 2012;7(11):e49338.
21. Koshimura K, Murakami Y, Sohmiya M, Tanaka J, Kato Y. Effects of erythropoietin on neuronal activity. J Neurochem 1999;72(6):2565-72.
22. Yoshimura A, Misawa H. Physiology and function of the erythropoietin receptor. Curr Opin Hematol 1998;5(3)171-6.
23. Monge A, Nagy I, Bonabi S, Schmid S, Gassmann M, Bodmer D. The effect of erythropoietin on gentamisin-induced auditory hair cell loss. Laryngoscope 2006;116(2):312-6.
24. Andreeva N, Nyamaa A, Haupt H, Gross J, Mazurek B. Recombinant human erythropoietin prevents ischemia-induced apoptosis and necrosis in explant cultures of the rat organ of corti. Neurosci Lett 2006;396(2):86-90.
25. Morishita E, Masuda S, Nagao M, Yasuda Y, Sasaki R. Erythropoietin receptor is expressed in rat hippocampal and cerebral cortical neurons, and erythropoietin prevents in vitro glutamate-induced neuronal death. Neurosci 1997;76(1):105-16.