Is Helicobacter Pylori a Possible Etiopathogenic Factor in Chronic Tonsillitis?

Helikobakter Pilori Kronik Tonsillitin Potansiyel Etyolojik Ajanı Mıdır?

Helikobakter Pilori ve Kronik Tonsillit / Helicobacter Pylori and Chronic Tonsillitis

Elmas Ozgun[1], Deniz Tuncel[1], Ayca Tan[2], Aynur Albayrak[3], Sehnaz Emil Sayhan[4], Nurten Bozlak[1]
[1]Nevsehir Dr.I.Sevki Atasagun State Hospital, Department of Pathology, Nevsehir,
[2]Dr.Lutfi Kırdar Kartal Training and Research Hospital, Department of Pathology, Istanbul,
[3]Ankara Diskapi Yildirim Beyazit Training and Research Hospital, Department of Pathology, Ankara,
[4]Denizli Servergazi State Hospital, Department of Pathology, Denizli, Turkiye

This paper was presented in 24th European Congress of Pathology as a poster presentation

Özet

Amaç: Helikobakter pilori kronik gastritin etyopatogenezinde önemli bir role sahiptir. Helikobakter Pilori'nin mide dışı rezervuar olarak tonsillektomi materyallerinde kronik tonsillit gelişimi açısından bir etyolojik faktör olup olmadığını araştırdık. Gereç ve Yöntem: Bu çalışma kapsamında kronik tonsillit tanısı almış 100 bilateral tonsillektomili hasta değerlendirildi. Mikroorganizmanın kolonizasyonu ışık mikroskobu altında hematoksilen-eosin ve giemsa boyaları ile araştırıldı. Bulgular: Helikobakter pilori, olguların 33'ünde (%33) bir taraf tonsilde ve 15'inde (%15) her iki taraf tonsillerde saptanırken, toplamda 48 (%48) olguda pozitivite izlendi. 52 olguda kolonizasyon görülmedi (% 52). Tartışma: Çalışmamızda, tonsillerin histopatolojik incelemesinde anlamlı Helikobakter Pilori kolonizasyonunun kronik tonsillite dair etyolojik faktörlerden biri olabileceği gösterilmiştir.

Anahtar Kelimeler

Helikobakter Pilori; Tonsillektomi; Tonsil; Tonsillit; Giemsa

Abstract

Aim: Helicobacter pylori is the major gastric pathogen which has an important role in the etiopathogenesis of chronic gastritis. We investigated the presence of Helicobacter pylori as an extragastric reservoir in the tonsillectomy specimens to display if it is an etiologic factor in the development of chronic tonsilitis. Material and Method: In the current study, 100 cases with chronic tonsilitis were examined in bilateral tonsillectomy specimens. The colonization of the microorganism have been evaluated with hematoxylin-eosin and giemsa stains under the light microscope.Results: Helicobacter pylori has been detected in 33 cases (33%) on one side of the bilateral tonsillectomy specimens while it has been seen in 15 cases (15%) on both sides which demonstrated positivity in 48 cases (48%) in total. No colonization has been observed in the remaining 52 cases (52%). Discussion: Due to the considerable positivity in our study, the histopathologic evaluation of tonsillary Helicobacter pylori colonization may be instrumental in the etiologic association with chronic tonsillitis.

Keywords

Helicobacter Pylori; Tonsillectomy; Tonsil; Tonsillitis; Giemsa

DOI: 10.4328/JCAM.2020 Received: 13.08.2013 Accepted: 20.08.2013 Printed: 01.05.2015 J Clin Anal Med 2015;6(3): 335-338
Corresponding Author: Ayca Tan, Denizli Devlet Hastanesi, Denizli, Türkiye.
T.: +905055883747 F.: +90 2582639311 E-Mail: draycatan@gmail.com

Introduction

Helicobacter pylori (H. pylori) is a well-known pathogen which is recognized as the most frequent infection of individuals. More than half of the world's population is being infected [1]. H. pylori plays an important role in the etiology of gastritis, gastric and duodenal ulcers [2]. Since it is also significant in the etiology of gastric adenocarcinomas ve MALT lymphomas, the microorganism has been described as a carcinogen by the World Health Organization [3]. It spreads by oral-oral or faecal-oral way [4]. According to these routes of transmission, there are reported studies on the colonization of H. pylori in upper respiratory tract and oral mucosa [5-7]. In the recent years, adenotonsillar tissue has being started to be considered as one of the reservoir for the microorganism [8].

The aim of the current study is to demonstrate the tonsillary tissue as an extra gastric reservoir for H. pylori in the tonsillectomy specimens and to clarify wheither it may take place in the etiology of chronic tonsillitis.

Material and Method

From the authors' institutional files, the pathologic material, including the reports and routine formalin-fixed, paraffin-embedded, hematoxylin and eosin (H&E) stained 100 cases from the years 2011 and 2012 were reviewed. All cases were detected among bilateral tonsillectomy specimens for which the available tissues for histochemical staining could be retrieved were histologically chronic tonsillitis. Patients' age, gender were taken from the reports.

Histochemical staining: Histochemical staining for giemsa was performed on the 5-µm, formalin-fixed, paraffin-embedded sections to detect H. pylori. Giemsa staining was performed according to the standard procedure as mentioned below:

First the sections were brought to distilled water, then stained with diluted Giemsa's stain made up fresh, rinsed in distilled water, differentiated with 0.5% aqueous acetic acid, then dehydrated rapidly and cleaned and mounted.

A case diagnosed as chronic gastritis with H. pylori colonization was used for the positive control. The presence of H. pylori was investigated on the mucosal surfaces in both H&E and giemsa stained sections.

Results

Clinical findings: Out of 100 cases, the patients' age range was between 2 to 44 of which 48 were males (48%) and 52 were females (52%). H. pylori was not identified clearly in the histopathological evaluation of H&E sections. On giemsa-stained sections, out of 100 cases, the microorganism H. pylori-like microorganisms was detected on 48 (48%) cases on the mucosal surfaces of the tonsillary tissues (Figure 1, 2). H. pylori positive gastric mucosa has been used as a positive control (Figure 3).

Out of 48-H. pylori detected cases, 25 were females, 23 were males. Among all the selected female patients, in 48.08% (25/52) and among the male patients in 47,92% (23/48) H. pylori was identified.

Among the 48 H. pylori detected cases, in 31,25% (15/48) of them, the microorganism was recognised in both tonsills while in 68,75% (33/48) cases, it was determined on one of them (Table 1). Statistical analysis revealed no correlation between the identification of H. pylori and the age or gender of the cases. In the current study, statistically there was no significant difference by chi-quare test between female and male who showed H.

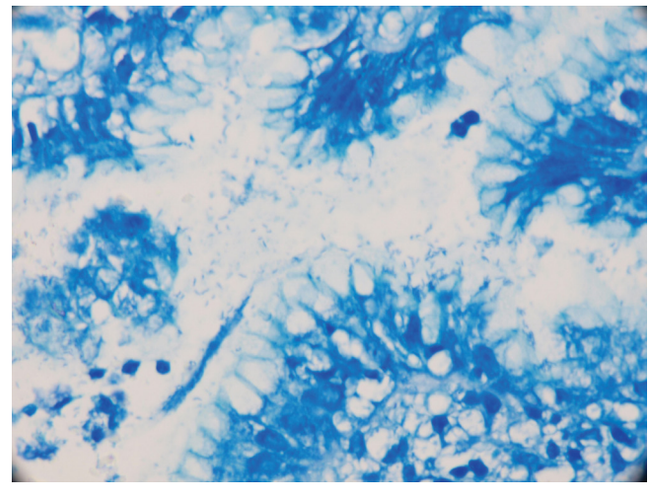

Figure 1. H.pylori infected gastric mucosa used as positive control, Giemsa, X200



Figure 2. H.pylori like microorganism on the mucosal surface of the tonsillary tissue, Giemsa, X40

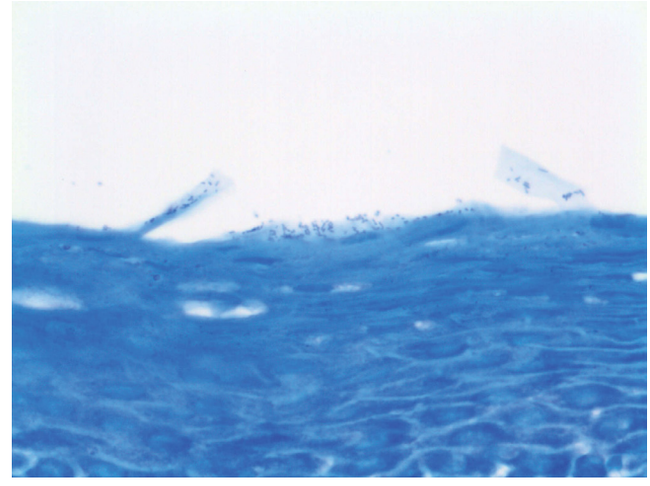

Figure 3. H.pylori like microorganism on the mucosal surface of the tonsillary tissue, Giemsa, X200

Table 1. Characteristics of H.pylori results in the studied individuals

	H.Pylori ++	H.Pylori +	H.Pylori -
Female	8	17	28
Male	7	16	24
	15	33	52

Pylori colonization (p=0,853).

Discussion

Chronic tonsillitis is a common upper respiratory tract disease mainly in children. Due to the possible local or distant complications, tonsillectomy is often indicated. The etiology of chronic tonsillitis is still unclear. Because it may affect the treatment methods, it is extremely important to clarify the etiology. There have been studies reported in the recent years [7-10].

H. pylori is a gram-negative, spiral-shaped microorganism that mainly exists in the gastric mucosa [11 12]. Bacteria produces the urease enzyme which changes urea into carbon dioxide and ammonia. Ammonium covers the acidic environment in the stomach [11]. The infection usually occurs in the early childhood and remains permanently in the host if not treated [1].

The prevelance of the infection is higher in the low socioeconomical and crowded populations [13]. Infected individuals have three times greater risk for gastric ulcer and two and a half times greater risk for gastric carcinoma [14]. H. pylori has been detected from faeces [15], gastric juice, vomit, saliva and denthal plague [5 16]. Oral-oral route is the most common route of transmission [17].

There are direct and indirect methods of detecting H. pylori. The main indirect method is serology. The most significant direct methods are urease test, culture, polimerase chain reaction (PCR). Minocha et al. has reported a study about the importance of the colonization of H. pylori in tonsillary tissue. The decrease of the prevelence of gastric H. pylori has been pointed out in the cases with tonsillectomy [18].

Aygenc et al and Rubin et al have mentioned a significant H. pylori seropositivity in squamous cell carcinomas of the head and neck region in their studies while Grandis et al declared no obvious seropositivity in their study [19-21].

Bitar et al. investigated the colonization of H. pylori in the adenoid specimens by rapid urease test (RUT), histology (giemsa and Warthin-Starry staining) and "nested polymerase chain reaction (nPCR)". Out of 25 adenoid specimens, 21 showed RUT positivity. In 8 cases, cocobasil has been recognised by giemsa staining and in 4 of the cases H. pylori like bacteria have been detected with Warthin-Starry staining. No genomic material has been identified by nPCR [22].

Vayisoglu and Aslan et al. reported articles using RUT and pathologic examination on adenotonsillectomy specimens. Neither of them revealed H. pylori colonization [9 10].

Cirak et al reported an article on detecting the colonization of H. pylori using PCR. Out of 15 cases of tonsillectomies 10, out of 10 cases of adenoidectomies 3 of them revealed H. pylori positivity [23]. In the current study, out of 100 cases, 48 cases showed H. pylori like bacteria on the tonsillary mucosal surfaces with giemsa histochemical staining.

H. pylori hasn't been detected in Di Bonaventura et al and Skinner et al studies with the use of neither culture, immunohistochemically nor used CLO (campylobacter-like organisms) test [24 25]. Kizilay et al. investigated H. pylori colonization in the laryngeal cancer specimens with the use of H&E or giemsa. No colonization has been identified [6].

The results of the reported articles reveals contraversies on this issue. It seems like in the oral mucosa, due to the numerous bacterias producing urease, urease test and CLO test do not show reliable results for the detection of H. pylori. Diagnostic tools for H. pylori like H&E, giemsa, Warthin Starry is not very helpful for the oral mucosa due to the complexity [5 7].

Dowsett et al and Lukes et al reported that culture is the best way to detect H. pylori in the oral cavity. However the present complicated microflora of the oral cavity, lack of microaerophilic environment, more than 7 days of incubation support overgrowth of other oral species which limits the effectivity of culture. PCR eliminates the difficulties in culture and permits amplification of H. pylori-specific region of DNA. This helps the detect more H. pylori in the oral tissue. On the other hand, the results of studies that used PCR for recognizing oral H. pylori were inconstant with detection rate ranging between 0-90% [5 7]). All these support that PCR and culture are needed to be used both PCR and culture together [7].

Conclusion

In our study, colonization of H. pylori has not been detected histopathologically. On the other hand, a significant number of cases showed H. pylori positivity with giemsa. According to those results, it is important to keep in mind the possibility of H. pylori as an etiologic agent for chronic tonsillitis. Due to the complexity of the oral mucosa, other diagnostic tools are needed to confirm the diagnosis.

Competing interests

The authors declare that they have no competing interests.

References

1. Azevedo NF, Guimarães N, Figueiredo C, Keevil CW, Vieira MJ. A new model for the transmission of Helicobacter pylori: role of environmental reservoirs as gene pools to increase strain diversity. Crit Rev Microbiol 2007;33(3):157-69.
2. Balaban D, Peura D. Helicobacter pylori associated with peptic ulcer and gastritis. In: Lamont J, ed. Gastrointestinal infections. Diagnosis and management. New York: Marcel Dekker Inc;1997:29-69.
3. Cancer IAfRo. Infection with Helicobacter pylori. In: Cancer IAfRo, ed. Schistosomes, liver flukes and Helicobacter pylori. Lyon: World Health Organisation, IARC;1994:177-202.
4. Brown LM. Helicobacter pylori: epidemiology and routes of transmission. Epidemiol Rev 2000;22(2):283-97.
5. Dowsett SA, Kowolik MJ. Oral Helicobacter pylori: can we stomach it? Crit Rev Oral Biol Med 2003;14(3):226-33.
6. Kizilay A, Saydam L, Aydin A, Kalcioglu MT, Ozturan O, Aydin NE. Histopathologic examination for Helicobacter pylori as a possible etiopathogenic factor in laryngeal carcinoma. Chemotherapy 2006;52(2):80-2.
7. Lukes P, Astl J, Pavlik E, Potuzníková B, Sterzl I, Betka J. Helicobacter pylori in tonsillar and adenoid tissue and its possible role in oropharyngeal carcinogenesis. Folia Biol (Praha) 2008;54(2):33-9.
8. Vilarinho S, Guimarães NM, Ferreira RM, Gomes B, Wen X, Vieira MJ, et al. Helicobacter pylori colonization of the adenotonsillar tissue: fact or fiction? Int J Pediatr Otorhinolaryngol 2010;74(7):807-11.
9. Aslan S, Yilmaz I, Bal N, Sener M, Butros R, Demirhan B, et al. Investigation of Helicobacter pylori in tonsillary tissue with Pronto Dry test and pathologic examination. Auris Nasus Larynx 2007;34(3):339-42.
10. Vayisoglu Y, Ozcan C, Polat A, Delialioglu N, Gorur K. Does Helicobacter pylori play a role in the development of chronic adenotonsillitis? Int J Pediatr Otorhinolaryngol 2008;72(10):1497-501.
11. Guarner J. The spectrum of gastric disease associated with Helicobacter pylori and other infectious gastritides. Curr Gastroenterol Rep 2004;6(6):441-6.
12. Mitchell HM. The epidemiology of Helicobacter pylori. Curr Top Microbiol Immunol 1999;241:11-30.
13. Azevedo NF, Huntington J, Goodman KJ. The epidemiology of Helicobacter pylori and public health implications. Helicobacter 2009;14 Suppl 1:1-7.
14. Everhart JE. Recent developments in the epidemiology of Helicobacter pylori. Gastroenterol Clin North Am 2000;29(3):559-78.
15. Makristathis A, Pasching E, Schutze K, Wimmer M, Rotter ML, Hirschl AM. Detection of Helicobacter pylori in stool specimens by PCR and antigen enzyme immunoassay. J Clin Microbiol 1998;36(9):2772-4.
16. Banatvala N, Lopez CR, Owen R, Abdi Y, Davies G, Hardie J, Feldman R. Helico-

bacter pylori in dental plaque. Lancet 1993;341(8841):380.
17. Peters C, Schablon A, Harling M, Wohlert C, Costa JT, Nienhaus A. The occupational risk of Helicobacter pylori infection among gastroenterologists and their assistants. BMC Infect Dis 2011;11:154.
18. Minocha A, Raczkowski CA, Richards RJ. Is a history of tonsillectomy associated with a decreased risk of Helicobacter pylori infection? J Clin Gastroenterol 1997;25(4):580-2.
19. Aygenc E, Selcuk A, Celikkanat S, Ozbek C, Ozdem C. The role of Helicobacter pylori infection in the cause of squamous cell carcinoma of the larynx. Otolaryngol Head Neck Surg 2001;125(5):520-1.
20. Grandis JR, Perez-Perez GI, Yu VL, Johnson JT, Blaser MJ. Lack of serologic evidence for Helicobacter pylori infection in head and neck cancer. Head Neck 1997;19(3):216-8.
21. Rubin JS, Benjamin E, Prior A, Lavy J. The prevalence of Helicobacter pylori infection in malignant and premalignant conditions of the head and neck. J Laryngol Otol 2003;117(2):118-21.
22. Bitar MA, Soweid A, Mahfouz R, Zaatari G, Fuleihan N. Is Helicobacter pylori really present in the adenoids of children? Eur Arch Otorhinolaryngol 2005;262(12):987-92.
23. Cirak MY, Ozdek A, Yilmaz D, Bayiz U, Samim E, Turet S. Detection of Helicobacter pylori and its CagA gene in tonsil and adenoid tissues by PCR. Arch Otolaryngol Head Neck Surg 2003;129(11):1225-9.
24. Di Bonaventura G, Catamo G, Neri M, Neri G, Piccolomini R. Absence of Helicobacter pylori in tonsillar swabs from dyspeptic patients. New Microbiol 2000;23(4):445-8.
25. Skinner LJ, Winter DC, Curran AJ, Barnes C, Kennedy S, Maguire AJ, et al. Helicobacter pylori and tonsillectomy. Clin Otolaryngol Allied Sci 2001;26(6):505-9.