Achondroplasia Presenting with Pneumonia in a Two Months Old Boy

Pnömoni ile Başvuran 2 Aylık Bir Çocukta Akondroplazi

Pnömoni ile Başvuran Akondroplazi / Achondroplasia Presenting with Pneumonia

Huseyin Bilgin[1], Murat Serhat Aygun[2], Ece Selma Solak[1], Fatih Akin[1], Sukru Arslan[1]
[1]Department of Pediatrics, [2]Department of Radiology, Konya Training and Research Hospital, Konya, Turkey

Özet

Akondroplazi sık görülen bir kondrodisplazi olup otozomal dominant kalıtılır, ancak % 85 sıklıkla yeni mutasyonlar görülür. Akondroplazi, fibroblast growth faktör reseptör 3 mutasyonuna bağlı oluşan enkondral displazi sonucunda gelişir. İki aylık çocuk öksürük ve ateş nedeniyle hastanemize sevk edilmiştir. Kraniofasial olarak kafa büyük görünümde olup frontal çıkıntı ve burun kökü çöküklüğü izlenmiştir. X-ray incelenmesinde dar lumbar interpediküler mesafe, normal gövde uzunluğu, kısa-geniş pelvis, mikromelik üst ekstremite ve rizomelik alt ekstremite görülmüştür. Klinik ve radyolojik olarak pnömoniye sekonder kalp yetmezliği ile beraber akondroplazi tanısı konmuştur. Kısa ekstremite ve respiratuar bozukluk ile başvuran çocuklarda akondroplazi metatropik displazi ve kampomelik displaziden ayırtedilmelidir. Akondroplazide diğer boy kısalıkları ile benzer bulgular görülebilir ve daha iyi hasta bakımı ve aile danışmanlığı için akondroplaziye benzer hastalıklardan ayırıcı tanıda pediatri, radyoloji ve tıbbi genetiği içeren ekip çalışmasına ihtiyaç vardır.

Anahtar Kelimeler

Akondroplazi; İnfant; Pnömoni; Kısaekstremite

Abstract

Achondroplasia is one of the common chondrodysplasias with an inheritance is autosomal dominant, but in around 85% the phenotype is the result of a new mutation. Achondroplasia develops as a result of dysplasia of enchondral formation due to the mutation of fibroblast growth factor receptor 3. A 2-month-old boy was referred to the our hospital with cough and fever. Craniofacially the head appeared large and also frontal bossing and depressed nasal bridge was demonstrated. Narrow lumbar interpedicular distances, normal trunk length, short-wide pelvis, micromelic upper extremities and rhizomelic lower extremities were seen on x-ray examination. The clinically and radiographically diagnosis of achondroplasia with heart failure secondary to pneumonia was performed. Achondroplasia, presenting with respiratory disorders and short limb should be differentiated from metatropic dysplasia and campomelic dysplasia. Achondroplasia may had similar findings with other dwarfism and differentiate diagnosis from other achondroplasia like diseases needs team work which includes pediatry, radiology and medical genetic for better patient care and family counseling.

Keywords

Achondroplasia; Infant; Pneumonia; Short Limb

DOI: 10.4328/JCAM.1007 Received: 10.04.2012 Accepted: 01.07.2012 Printed: 01.07.2015 J Clin Anal Med 2015;6(4): 558-560
Corresponding Author: Huseyin Bilgin, Konya Training and Research Hospital, Department of Pediatry, 42080 Konya, Turkey.
T.: +903323236709 E-Mail: hubilgin@hotmail.com

Introduction

Achondroplasia is one of themost common chondrodysplasias with a prevalence rate ofaround 1 in 26 000 live births [1]. Inheritance is autosomaldominant, but in around 85% the phenotype is the result ofa new mutation. Achondroplasia develops as a result of dysplasia of enchondral formation due to the mutation of fibroblast growth factor receptor 3. Clinical features of achondroplasia include short stature, long-narrow trunk, shortening of the proximal segments of limbs, large head with frontal bossing, mid-face hypoplasia, joint hyperextensibility, ''trident-shaped'' hands, lumbar lordosis, and hypotonia [2]. Achondroplasia is also characterized by central nervous system defects, including compression at the cervicomedullary junction and hydrocephalus, and respiratory disorders, including central apnea, obstructive apnea, and restrictive lung disease [2].

We report a case of pneumonia leading to heart failure in an infant with achondroplasia.

Case Report

A 2-month-old boy was referred to the our hospital withcough and fever. The boy was born at 36 weeks' gestation after anuncomplicated pregnancy. Birth weight was 2660 g. He was the second child of a non-consanguineous parents. He had a history of pneumonia in the newborn period. At the time of conception, the father was 25 years of age and the mother 25 years. There was no family history of achondroplasia.

His physical examination revealed: weight: 3600 grams (3-10 percentile); height 47 cm (3rd percentile); head circumference: 36 cm (10th percentile); pulse rate: 122/min; respiratory rate:68/min; blood pressure: 75/45 mm/Hg and temperature: 37 °C. Craniofacially the head appeared large withfrontal bossing and depressed nasal bridge. The handswere short and broad with fingers. Respiratory system examination showed bilateral crackles. The rest of the physical examination was unremarkable.

Laboratory examinations including complete blood count, serum electrolytes, liverfunction tests were all within normal limits. Echocardiography revealed a small patent ductusarteriosus with left ventricular dysfunction. X-ray examination showed narrow lumbar interpedicular distances, normal trunk length, short-wide pelvis, rhizomelic lower extremities (femur and ulna appropriate with 26 and 30 gestational age, respectively) and micromelic upper extremities (humerus and radius appropriate with 26 gestational age) (figure 1A-B-C). There were no findings that are suggestive of mental retardation or hearing difficulty.

The clinically and radiographically diagnosis ofachondroplasia with heart failure secondary to pneumonia was performed.

Discussion

Achondroplasia is the most common form ofshort-limbed dwarfism. It is mostly autosomaldominant in transmission, but with a high rate ofspontaneous mutation. Achondroplasia is characterizedby shortening and thickening of the longbones with metaphyseal flaring and cupping. Thephalanges are short, broad, and cupped. The iliacbones are short and rectangular with narrow sacrosciaticnotches and short, wide pubic and ischial bones. There are bullet-shapedvertebral bodies with posterior scalloping andnarrowing of lumbar interpedicular distances.

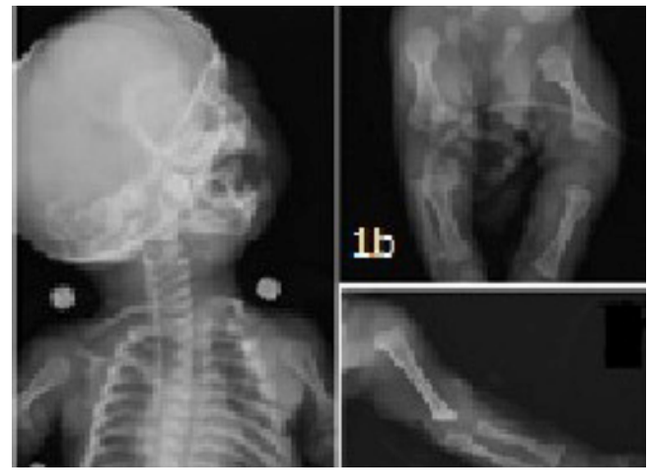

Figure 1. X-ray examination: Shows narrow lumbar interpedicular distances (A), normal trunk length, Shows rhizomelic lower extremities (B) and Shows micromelic upper extremities (C).

The intervertebral disks are widened, resulting innormal trunk length, and the thorax is slenderdue to the short ribs with flared anterior ends.The head is large, with frontal bossing and a depressednasal bridge [3]. Our patient had large head with frontal bossing, narrow lumbar interpedicular distances and depressed nasal bridge. The hands were short and broad with fingers. His upper extremities weremicromelic and lower extremities rhizomelic. There was no evidence of bullet-shaped vertebral bodies, bowing legs, kyphosis or scoliosis.

Metatropic dysplasia was first delineated by Maroteaux et al. in 1966, and the name is derived from the Greek term metatropos, meaning ''changing patterns.'' Genetic heterogeneity based on clinical and radiographic variability has been proposed, including a nonlethal dominant form and both lethal and nonlethal autosomal-recessive forms. Patients often present with shortened limbs and a long, narrow trunk in the newborn period that evolves into a severe, progressive kyphoscoliosis, frequently requiring surgical correction. Affected individuals have a distinctive facies with a prominent forehead and squared-off jaw [4]. Other significant clinical findings include a high incidence of odontoid hypoplasia, cervical myelopathy, also in some cases, stenosis leading to significant neurologic sequelae, as well as coccygeal tail, wafer-like vertebral bodies in newborns, a halberd-shaped pelvis, irregular calcanei and tali, brachydactyly with delayed carpal ossification, and flared or ''mushroomed'' proximaland distal metaphyses of the femora leading to a ''dumbbell- shaped bone''. The peculiar changes distinguish achondroplasia from metatropic dysplasia are largely normal trunk length, short ribs, bullet shaped vertebral bodies, short-broad hands and short-wide pelvis.

Campomelic dysplasia is a rare, often lethal, autosomal dominant osseous malformation syndrome. This skeletal dysplasia is characterized by bowing of the femur and tibia, short 1st metacarpals, hypoplasticscapulae, non-mineralization of the pedicles of the thoracic vertebra, presence of 11 pairs of ribs, narrow iliac wings, and poor ossification of the pubis. The main facial features are a large head, flat nasal bridge, low-set and malformed ears, small jaw, and a cleft palate. A narrow chest, congenital dislocation of the hip, and bilateral talipesequinovarus are often common [5]. A male-to-female autosomal sex reversal characterizes this syndrome in two-thirds of the af-

fected karyotypic males. Expression can be very variable. For instance, campomelia is present in 90% of the cases. Cardiac defects and hydronephrosis have been reported in one-third of the patients. Moreover, in nearly 95% of the cases, death occurs in the neonatal period due to breathing problems related to small chest size [5].In our patient, there was no evidence of low set ears, small jaw, hip dislocation, talipesequinovarus, macrocephaly, cleft palate, leg bowing, hypoplastic scapulae, short 1st metacarpals, non-mineralization of the pedicles of the thoracic vertebra, 11 pairs of ribs, narrow iliac wings, poor ossification of the pubis and narrow bell-shaped chest.

Achondroplasia, presenting with respiratory disorders and short limb should be differentiated from metatropic dysplasia and campomelic dysplasia. Achondroplasia may had similar findings with other dwarfism and differentiate diagnosis from other achondroplasia like diseases needs team workwhich includes pediatry, radiology and medical genetic for beter patient care and family counseling.

Competing interests

The authors declare that they have no competing interests.

References

1. Oberklaid F, Danks DM, Jensen F, Stace L, Rosshandler S. Achondroplasia and hypochondroplasia. Comments on frequency, mutation rate, and radiological features in skull and spine. J Med Genet 1979;16(2):140-6.
2. HortonWA,Hall JG, Hecht JT. Achondroplasia. Lancet 2007;370:162-72.
3. Tolo VT. The lower extremity. In: Morrissy RT, Weinstein SL, eds. Lovell and Winter's pediatric orthopaedics. Vol II. 4th ed. Philadelphia, Pa: Lippincott- Raven; 1996.p.1047–75.
4. Kannu P, Aftimos S, Mayne V, Donnan L, Savarirayan R. Metatropic dysplasia: Clinical and radiographic findings in 11 patients demonstrating long-term natural history. Am J Med Genet 2007;143(21):2512–22.
5. Mansour S, Offiah AC, McDowall S, Sim P, Tolmie J, Hall C. The phenotype of survivors of campomelic dysplasia. J Med Genet 2002;39(8):597–02.

How to cite this article:
Bilgin H, Aygun MS, Solak ES, Akin F, Arslan S. Achondroplasia Presenting with Pneumonia in a Two Months Old Boy. J Clin Anal Med 2015;6(4): 522-4.