A Giant Pseudoaneurysm Early After Bentall Operation

Bentall Operasyonu Sonrasında Erken Dev Psödoanevrizma

Dev Psödoanevrizma / A Giant Pseudoaneurysm

Zafer Isilak[1], Serkan Cay[1], Mehmet Incedayi[2], Murat Yalcin[1], Mehmet Uzun[1]
[1]Department of Cardiology, [2]Department of Radiology, Gulhane Military Medical Academy, Haydarpasa Hospital, Istanbul, Turkey

Özet

Bental operasyonu aort kapak ve asendan aortanın bir bütün olarak replasmanıdır. Bental operasyonu sonrası psödoanevrizma gelişmesi sıklıkla cerrrahi teknik ile ilişkilidir. Özellikle postoperatif erken dönemde böyle cerrahi prosedürlere maruz hastalar çok dikkatli değerlendirilmelidir. Bental prosedürü sonrası yaşamı tehdit eden psödoanevrizma gelişiminde seri tanısal ekokardiyografik ve radyolojik muayeneler hayati bir öneme sahiptir.

Anahtar Kelimeler

Psödoanevrizma; Bental Operasyonu; Çok Kesitli Bilgisayarlı Tomografi

Abstract

Bentall operation is the complete replacement of the aortic valve and the ascending aorta. Pseudoaneurysm seen after the Bentall procedure is frequently associated with surgical technique. Especially in the early postoperative period, patients undergoing such major surgery should be evaluated more carefully. Serial echocardiographic and radiological examinations have a vital role to detect life-threatening pseudoaneurysm developing after Bentall procedure.

Keywords

Pseudoaneurysm; Bentall Operation; Multislice Computed Tomography

DOI: 10.4328/JCAM.1012 Received: 12.04.2012 Accepted: 06.06.2012 Printed: 01.07.2015 J Clin Anal Med 2015;6(4): 538-539
Corresponding Author: Zafer Isilak, GMMA, Haydarpasa Hospital, Department of Cardiology, Tibbiye Street, 34668 Uskudar, Istanbul, Turkey.
T.: +90 2165423480 F.: +902163487880 GSM:+905336073292 E-Mail: drzaferisilak@gmail.com

Introduction

The Bentall operation is the complete replacement of the aortic valve and the ascending aorta. Pseudoaneurysm after the Bentall procedure is a rare complication. In this paper, we present a case of Bentall operation, in whom a pseudoaneurysm has been developed.

Case Report

A 62-year-old male patient was referred to our department with a possible diagnosis of infective endocarditis for echocardiographic examination. Bentall operation had been applied to patient because of an ascending aortic aneurysm and aortic valve insufficiency 1.5 months ago in another center. Postoperative 4th week control was reported as normal, but fatigue and shortness of breath had developed during the last 15 days. Physical examination revealed the metallic sound of the heart valve. ECG was normal except sinus tachycardia. The transthoracic echocardiography revealed normal left ventricular diameter and function. Transesophageal echocardiography (TEE) was performed due to insufficient echo windows. TEE revealed a normally functioning metallic valve in the aortic position and a giant pseudoaneurysm (PsA) with thrombosed areas reaching 12 cm in diameter around the ascending aorta graft material (Fig 1 and 2). However, a direct communiation between the true and false lumen could be displayed in TEE examination. There were no dehiscence and/or vegetations. An emergency multi-slice chest tomography was performed. A giant PsA with thrombosed areas reaching up to 12 cm in diameter was detected. This mass extended from the aortic valve ring to the distal suture of the prosthetic graft in the ascending aorta. An active contrast passage was also seen at the junction between the aortic graft and the native aorta (Fig 3 and 4.), and this leakage formed the giant PsA wrapping all around the aortic graft. An emergency re-operation was decided. The patient was referred to the center that the surgery was performed.

Discussion

Bentall operation, complete replacement of the aortic valve and the ascending aorta, was firstly described by Bentall and De Bono [1]. Various complications ranging from 8 to 10% such as pseudoaneurysm and dehiscence after the Bentall procedure associated with surgical technique can be seen. PsA formation may be seen in different time periods including early and late (up to 10 years) postoperative periods [2-3]. In our patient, PsA was detected in the early postoperative period. Especially in the early postoperative period, patients undergoing such major surgery should be evaluated more carefully. A serial diagnostic echocardiographic and radiological examinations should be performed to detect life-threatening pseudoaneurysms developing after Bentall procedure. The rapid diagnosis of PsA formation was established by TEE and confirmed by chest tomography in our patient.

Competing interests

The authors declare that they have no competing interests.

References

1. Bentall H, De Bono A. A technique for complete replacement of the ascending aorta. Thorax 1968;23:338-9.
2. Omeroglu SN, Mansuroglu D, Goksedef D, Cevat Y. Ultrafast computed tomography in management of post-bentall aortic root pseudoaneurysm repair. Tex Heart Inst J 2005;32:91-4.
3. Arslan Z, Tavlaşoğlu M, Güler A, Şahin MA, Güler L. Medtronic freestyle aortic root bioprosthesis implantation for the infective endocarditis on aortic root. J Clin Anal Med 2013; DOI: 10.4328/JCAM.780.

How to cite this article:
Isilak Z, Cay S, Incedayi M, Yalcin M, Uzun M. A Giant Pseudoaneurysm Early After Bentall Operation. J Clin Anal Med 2015;6(4): 502-3.

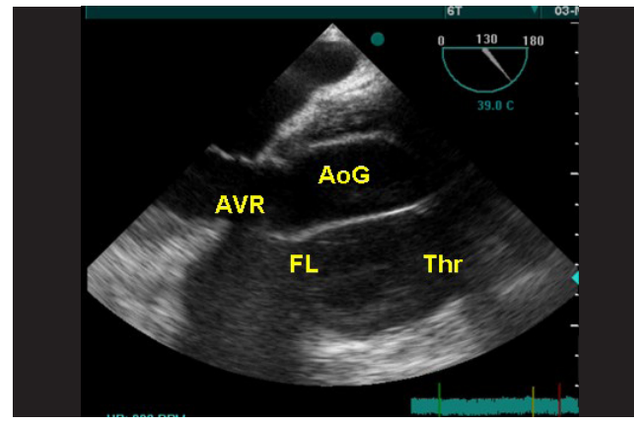

Figure 1. TEE showed partially thrombosed pseudoaneurysm around the aortic graft in long-axis view. (Abbreviations: AVR: Aortic Valve Replacement, AoG:Aortic greft, Thr: Thrombus, FL:False Lumen, TL:True Lumen)

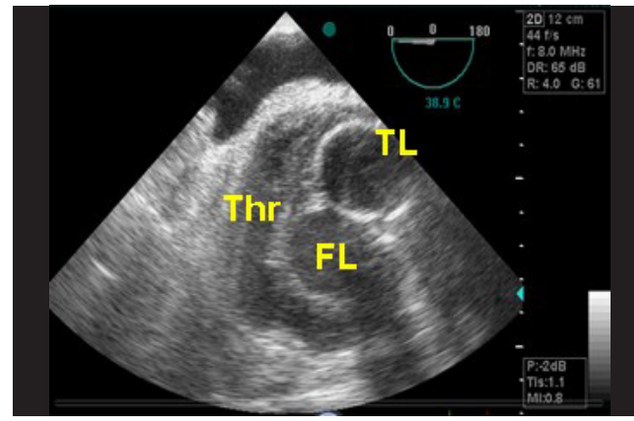

Figure 2. TEE showed both true and partially thrombosed false lumen in short-axis view. (Abbreviations: AVR: Aortic Valve Replacement, AoG:Aortic greft, Thr: Thrombus, FL:False Lumen, TL:True Lumen)

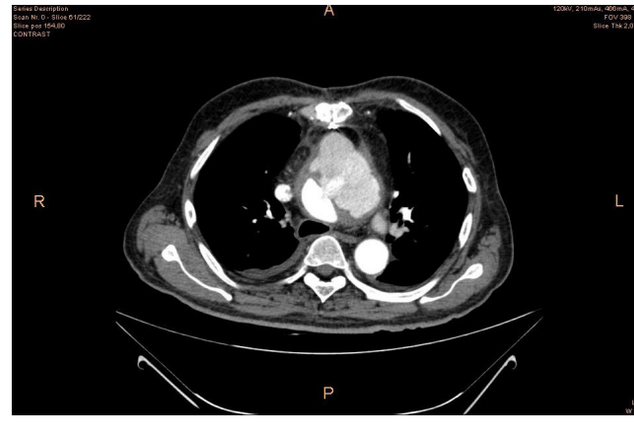

Figure 3. CT showed contrast leakage from the junction between the native aorta and the graft to pseudoaneurysm pouch.

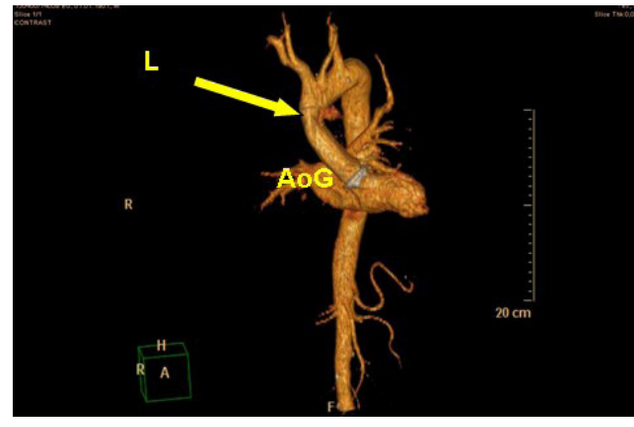

Figure 4. Reconstructed multi-slice CT showed contrast leakage from the junction between the native aorta and the graft.(AoG:Aortic greft, L: Leak)