Bilateral Giant Scrotal Hernia Treated with Intraabdominal Mesh Repair, Component Separation, and Reduction Scrotoplasty

Katmalarına Ayırma, İntraabdominal Yama ve Redüksiyon Skrotoplasti ile Tedavi Edilen Bilateral Dev Skrotal Herni Olgusu

Bilateral Dev Skrotal Herni için Katmanlarına Ayırma / Component Separation for Bilateral Giant Scrotal Hernia

Duray Seker[1], Celil Ugurlu[1], Ibrahim Unal[2], Engin Olcucuoglu[1], Hakan Kulacoglu[1]
[1]Department of Surgery, [2]Department of Plastic and Reconstructive Surgery,
Diskapi Yildirim Beyazit Teaching and Research Hospital, Ankara, Turkey

This case was presented as a poster in the 32. Congress of the European Hernia Society in Istanbul, Turkey, 6-9 October 2010.

Özet

Bu yazıda, bilateral dev skrotal fıtığı olan 59 yaşındaki erkek hasta bildirilmiştir. Skrotal fıtıkların toplam hacmi, intraabdominal volümün yaklaşık %50 kadardı. İntraabdominal volümün genişletilmesi amacıyla ilerleyici pnömoperiton denendi, ancak hasta tolere edemedi. Bunun üzerine, katmanlarına ayırma tekniği yardımıyla tek seansta transabdominal preperitoneal yama onarımı planlandı. Fıtık keselerinde ince barsak ansları, sigmoid kolon ve omentum vardı. Fıtık onarımı için standart polipropilen yama kullanıldı. Bilateral katmanların ayırma işlemi sonrasında karın orta hatta kapatıldı. Orta hat insizyonunu ve ayırma kesilerini kapatacak şekilde kısmen emilebilen hafif yama yerleştirildi. Cerrahinin son safhası olarak redüksiyon skrotoplasti plastik cerrahi uzmanı tarafından uygulandı. Ameliyat sonrasında 2 gün yoğun bakım ünitesinde kalan, ancak mekanik ventilasyon desteğine ihtiyaç durmayan hasta 19. günde taburcu edildi.

Anahtar Kelimeler

Dev Fıtık; Scrotal Herni; Katmanların Ayırma; Yama

Abstract

We report a 59 year-old male patient with bilateral giant scrotal hernia. The total volume of the scrotal hernias was almost 50% of the intraabdominal volume. Progressive pneumoperitoneum was tried to enhance intraabdominal volume before the repair, however the patient could not tolerate it. Therefore, he was scheduled for a single-stage transabdominal preperitoneal mesh repair and midline closure facilitated with component separation. Hernia sac content was small intestinal loops, sigmoid colon, and omentum. Standard polypropylene meshes were used for preperitoneal hernia repairs. Bilateral component separations were done and the midline was closed. A large sheet of partly absorbable lightweight composite mesh was laid on the abdominal wall to cover the midline and separation areas. Reduction scrotoplasty was employed by plastic surgeon as the latest stage of the surgery. The patient stayed in the ICU for 2 days but did not need mechanical ventilation, and was discharged on postoperative 19th day.

Keywords

Giant Hernia; Scrotal Hernia; Component Separation; Mesh

DOI: 10.4328/JCAM.1092 Received: 14.05.2012 Accepted: 15.06.2012 Printed: 01.07.2015 J Clin Anal Med 2015;6(4): 546-548
Corresponding Author: Hakan Kulacoglu, Dışkapı Yıldırım Beyazıt Eğitim ve Araştırma Hastanesi, Genel Cerrahi Kliniği, Ankara, Türkiye.
F.: +90 3123186690 E-Mail: hakankulacoglu@hotmail.com

Introduction

Giant inguino-scrotal hernia is one of the annoying problems in general surgery not only because of difficulty in its repair but also due to risk of postoperative intraabdominal compartment syndrome. Several treatment options have been described. Single-stage repairs are replacing two-stage repairs lately. Some centers have used abdominal wall component separation technique to avoid postoperative hypertension [1; 2]. We herein present a case of bilateral giant scrotal hernia treated with transabdominal preperitoneal mesh repair, component separation, and reduction scrotoplasty.

Case Report

59 year-old male patient was admitted with incarcerated bilateral giant inguino-scrotal Hernia (Figure 1). Preoperative



Figure 1. Bilateral giant inguino-scrotal hernias in upright position

CT scan showed that most of small intestinal loops are in the hernia sac together with omentum and part of large intestine (Figure 2). It was calculated that the total volume of the scrotal

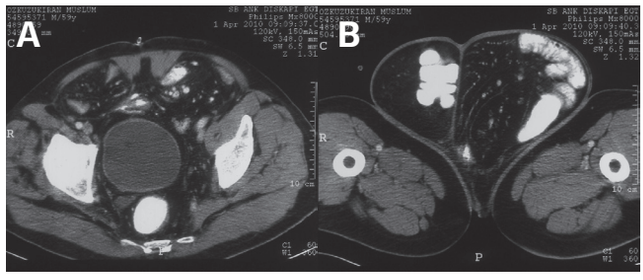

Figure 2. CT features: Hernia sac is as large as half of intraabdominal cavity(A). Very large scrotal hernia sacs containing intestinal segments(B).

hernias is almost 50% of the intraabdominal volume. Therefore, progressive pneumoperitoneum was tried to enhance intraabdominal volume before the repair. However the patient could not tolerate it and was scheduled for a single-stage intraabdominal mesh repair with component separation.

A midline laparotomy was done. Hernia sac content was small intestinal loops, sigmoid colon, and omentum. The content was pulled back into the abdominal cavity. Peritoneum covering inguinal floor was opened bilaterally and the sacs were resected totally. Standard polypropylene meshes were used for preperitoneal hernia repairs and the peritoneal flaps were closed. Bilateral component separations were done and the midline was closed with continuous polydiaxanone suture. A large sheet of partly absorbable lightweight composite mesh was laid on the abdominal wall to cover the midline and separated areas (Figure 3-A). Reduction scrotoplasty was employed by plastic surgeon as the latest stage of the surgery (Figure 3-B).

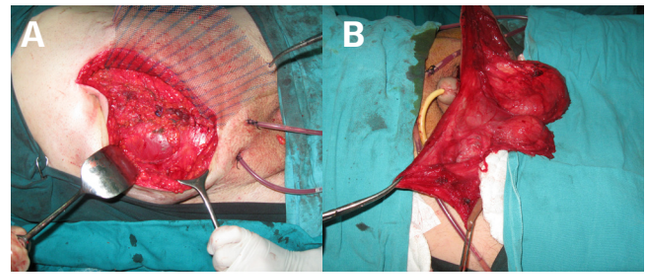

Figure 3. Operative procedures: A lightweight composite mesh is used onlay after separation of the abdominal wall layers (A), Scrotum is wide opened and a reduction scrotoplasty is performed (B).

Serum CRP level, intraabdominal pressure (IAP) and blood gas analysis were followed closely. Serum CRP increased to 100 and 125 on 5th and 7th days. It decreased to 21 on day 18th. IAP was 21 cm H2O immediately after the operation. It was 14 cm H2O at postoperative 6th hour and 16 at 12th h. IAP decreased to 12 cm H2O at 48th hour. No respiratory acidosis was recorded. He stayed in the ICU for 2 days but did not need mechanical ventilation. However he needed intermittent nasal oxygen supply. PO2 was 66.9 on day-3. It reached to normal range at the postoperative 5th day. A spontaneous serous drainage was met after 7th day. It responded well to conservative approach with twice daily dressings within one month. The patient was discharged on postoperative 19th day. He is doing well with no recurrences after 1 year (Figure 4-B).

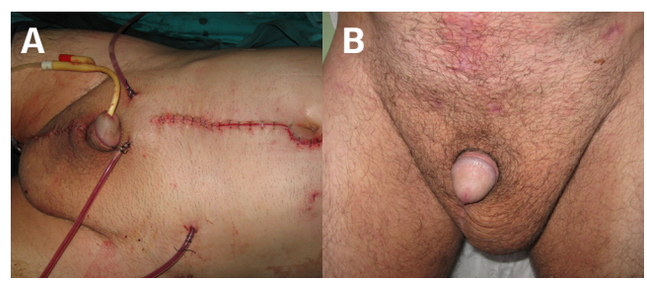

Figure 4. Operation was completed (A), A good cosmetic result is obtained at 12th week (B).

Discusssion

Giant inguino-scrotal hernias are rare. This term is used when the lower end of the hernia reaches mid-thigh to knee while the patient is standing [3-5]. Patients may present with cutaneous problems like eczema, candidiasis, skin gangren or ulcer [6]. Repair of these giant hernias is difficult and needs competence. Most of the intestine and omentum may be in the hernia sac. It carries certain risks to reduce this large content into a diminished abdominal cavity. The major problem is postoperative intraabdominal hypertension. Patients frequently have comorbidities and perioperative care is of great importance.

A giant hernia can rarely be cured with a typical repair via an inguinal approach. Mainly two treatment options are in use: debulking procedures with organ resections before repair [4; 5; 7-12] and techniques that enhance intraabdominal volume [1; 2; 11]. Hybrid techniques are also in use and, in fact, surgical procedures reported in the literature differ from each other. Or-

chiectomy may also be needed in some cases [4; 12].

Debulking procedures transform a hernia repair case into a much larger gastrointestinal surgery. Small and large bowels are resected, and anatomoses are left insitu. Cathastrophic cases secondary to anastomotic dehiscence have been reported [9]. Prosthetic materials are used for repairs after entering gastrointestinal tract, and this add a particular risk of infection.

Progressive pneumoperitoneum originally described by Goni Moreno [13] for loss of domain has also been used for giant scrotal hernias [8; 14]. Air is given daily via a catheter and it requires days to weeks to get the desired intraabdominal volume. Hernia can be cured with preperitoneal mesh placement via a laparotomy or with Nyhus or Stoppa repairs afterwards [10; 12]. Recently Tanaka et al. developed a tomographic calculation and recommended progressive pneumoperitoneum in cases where hernia sac volume is more than 25% of abdominal cavity volume [15]. Nevertheless some patients do not tolerate progressive pneumoperitoneum because of respiratory distress or intolerable pain. In the present case, pneumoperitoneum was tried twice, but the patient developed cyanosis and complained of serious pain in spite of preemptive analgesics and intravenous mild sedation. Maybe nitrous oxide is a better choice for creating a painless pneumoperitoneum as Caldironi et al. recommended [14]. One more point should be underlined that a debulking procedure may still be required in some cases in spite of preoperative progressive pneumoperitoneum (5).

Component separation was first described by Ramirez et al [16]. It is used for abdominal closure in cases with loss of domain and repair of large incisional hernias. Recently this technique has been used to cure giant scrotal hernias [1; 2]. Bilateral abdominal muscle components are separated approximately 10 cm on either side. This reduces intraabdominal pressure following midline closure. The hernia can be repaired with a preperitoneal approach without an additional incision or via an inguinal incision. We preferred transabdominal preperitoneal mesh repair in the present case and cover the midline closure and the separated areas with a large lightweight mesh.

Postoperative care is as important as preoperative preparation and surgery in these cases. Respiratory support and delayed extubation may be required after general anesthesia in spite of above technical measures. Some authors claimed to employ local anesthesia for repair that may be possible in unilateral cases [4]. Bilateral hernias is not only more difficult regarding surgery but also may create a distinct risk for respiratory problems. Suter and Martinet reported that 20-25% drops are seen in forced vital capacity (FVC) and forced expiratory volume in 1 second (FEV 1.0) after bilateral preperitoneal hernia repairs [17]. This is especially the case for the patient with chronic respiratory or cardivascular disorders. Supplemental oxygen is usually required, whereas some patients need prolonged ICU stay, continuous pulmonary airway pressure (CPCP) and even mechanical ventilation [5; 9; 10]. In the present case, mechanical ventilation was not required however nasal oxygen was given for 5 days and the patient was discharged after a long stay. Therefore one should keep this point in mind before deciding a repair and not try it if the institution has not have an ICU.

A secondary problem in these cases is redundant scrotal skin. First, it is a cosmetic problem. Second, a large seroma or hematoma can develop more easily in scrotum, and they need a long time to recover if no reductive procedure is performed. Moreover, patient may feel that he has not been cured completely unless the redundant scrotal skin is excised. Therefore, a reduction scrotoplasty following hernia repair is recommended [4; 5; 10]. In the present case, only a mild scrotal endurance was recorded for two weeks and a good cosmetic result was provided eventually.

In conclusion, there seems to be no standard way to cure giant scrotal hernias. Every single reported case on repair of a giant scrotal hernia teaches us something. Component separation technique is one of the good solutions to facilitate a single-stage repair and avoid intraabdominal compartment syndrome. However this kind of patients may still require postoperative respiratory support and are candidates for delayed discharge.

Competing interests

The authors declare that they have no competing interests.

References

1. Valliattu AJ, Kingsnorth AN. Single-stage repair of giant inguinoscrotal hernias using the abdominal wall component separation technique. Hernia 2008;2(3):329-30.
2. Ek EW, Ek ET, Bingham R, Wilson J, Mooney B, Banting SW, Burt J. Component separation in the repair of a giant inguinoscrotal hernia. ANZ J Surg 2006;76(10):950-2.
3. Hodgkinson DJ, McIlrath DC. Scrotal reconstruction for giant inguinal hernias. Surgical Clinics of North America 1980;64(2):307-3.
4. Sturniolo G, Tonante A, Gagliano E, Taranto F, Lo Schiavo MG, D'Alia C. Surgical treatment of the giant inguinal hernia. Hernia 1999;3(1):27-30.
5. Vasiliadis K, Knaebel HP, Djakovic N, Nyarangi-Dix J, Schmidt J, Büchler M. Challenging surgical management of a giant inguinoscrotal hernia: report of a case. Surg Today 2010;40(7):684-7.
6. Vano-Galvan S, Guisado-Vasco P, Jaén P. Giant inguinoscrotal hernia. Aust Fam Physician 2009;38(4):222-3.
7. Mehendal FV, Taams KO, Kingsnorth AN. Repair of a giant inguinoscrotal hernia. Br J Plast Surg 2000;53(6):525-9.
8. El Saadi AS, Al Wadan AH, Hamerna S. Approach to a giant inguinoscrotal hernia. Hernia 2005;9(3):277-9.
9. Monestiroli UM, Bondurri A, Gandini F, Lenna G, Vellini S, Danelli P. Giant inguinoscrotal hernia. Tech Coloproctol 2007;11(3):283-4.
10. Patsas A, Tsiaousis P, Papaziogas B, Koutelidakis I, Goula C, Atmatzidis K. Repair of a giant inguinoscrotal hernia. Hernia 2010;14(3):305-7.
11. Mayagoitia JC, Suárez D, Arenas JC, Díaz de León V. Preoperative progressive pneumoperitoneum in patients with abdominal-wall hernias. Hernia 2006;10(3):213-7.
12. Kovachev LS, Paul AP, Chowdhary P, Choudhary P, Filipov ET. Regarding extremely large inguinal hernias with a contribution of two cases. Hernia 2010;14(2):193-7.
13. Goni Moreno IG. The rational treatment of hernias and voliminous chronic evantrations: preparation with progressive pneumoperitoneum. In: Nyhus LM, Condon RED editors. Hernia. 2nd ed. Philadelphia: Lippincott; 1985.p.536-60.
14. Caldironi MW, Romano M, Bozza F, Pluchinotta AM, Pelizzo MR, Toniato A, Ranzato R. Progressive pneumoperitoneum in the management of giant incisional hernias: a study of 41 patients. Br J Surg 1990;77(3):306-7.
15. Tanaka EY, Yoo JH, Rodrigues AJ Jr, Utiyama EM, Birolini D, Rasslan. A computerized tomography scan method for calculating the hernia sac and abdominal cavity volume in complex large incisional hernia with loss of domain. Hernia 2010;14(1):63-9.
16. Ramirez OM, Ruas E, Dellon AL. "Component separation" method for closure of abdominal-wall defets: an anatomic and clinical study. Plast Reconstr Surg 1990;86(3):519-26.
17. Suter M, Martinet O. Postoperative pulmonary dysfunction after bilateral inguinal hernia repair: a prospective randomized study comparing the Stoppa procedure with laparoscopic total extraperitoneal repair [TEPP]. Surg Laparosc Endosc Percutan Tech 2002;12(6):420-5.

How to cite this article:
Seker D, Ugurlu C, Unal İ, Olcucuoglu E, Kulacoglu H. Bilateral Giant Scrotal Hernia Treated with Intraabdominal Mesh Repair, Component Separation, and Reduction Scrotoplasty. J Clin Anal Med 2015;6(4): 510-2.