Angioedema due to Pomegranate: Original Image

Nara Bağlı Anjiyoödem: Orijinal Görüntü

Nar / Pomegranate

Meliha Fındık[1], Cemil Kavalcı[1], Gülsüm Kavalcı[2]
[1]Department of Emergency Medicine, Faculty of Medicine, Başkent University, Ankara, Türkiye.
[2]Clinic of Anesthesiology and Reanimation, Yenimahalle State Hospital, Ankara, Türkiye.

A 35-year-old female patient presented to our emergency department with redness on the cheeks and edema in her mouth, lips and eyelids It was learned from the history that her symptoms were begun 15 minutes after eating a pomegranate.

In her medical history there was no any illness and drug use. On physical examination, she was alert. She has a regular heart rate of 78 bpm, her blood pressure was 120/75 mmHg and respiration rate was 12 breathes per minute. Redness was present her cheeks. Edema was present around her mouth and eyelids (Figure 1).

The patient was placed on a cardiac monitor, an intravenous line was established and 6 lt/min oxygen was started. 40 mg methylprednisolone and 50 mg diphenhydramine were administered intravenously. The patient was placed in our observation unit for 8 hours and was discharged without any further problems.

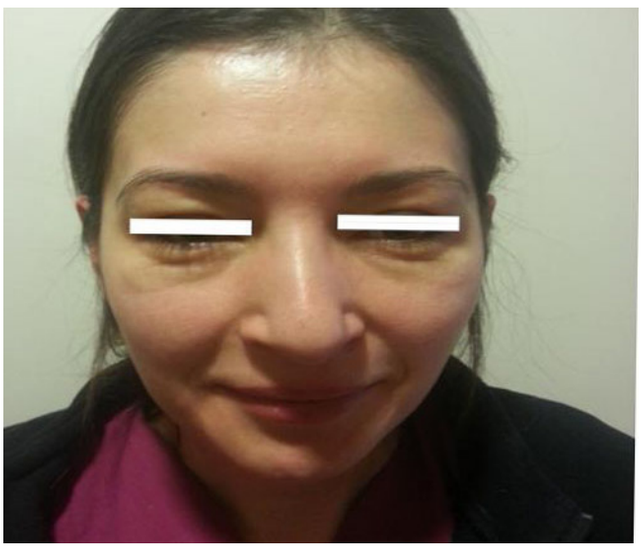

Figure 1. Edema in her mouth and eyelids of patient.

DOI: 10.4328/JCAM.2476 Received: 09.04.2014 Accepted: 17.04.2014 Publihed Online: 01.07.2015 J Clin Anal Med 2015;6(4): 579
Corresponding Author: Cemil Kavalcı, Department of Emergency Medicine, Faculty of Medicine, Başkent University, Ankara, Türkiye.
GSM: +905055762819 E-Mail: cemkavalci@yahoo.com