A Case of Conjunctival Melanoma Presenting with Breast Metastasis

Meme Metastazı ile Başvuran Konjuktival Melanom Olgusu

Melanom Meme Metastazı / Melanoma Breast Metastasis

Mustafa Canhoroz[1], İsmail Yoğurt[2], Şahsuvar Gökgöz[3], Uğur Topal[4], Özkan Kanat[5]
[1]Department of Medical Oncology, Fırat University Faculty of Medicine,
[2]Department of Internal Medicine, [3]Department of General Surgery, [4]Department of Radiology, [5]Department of Medical Oncology,
Uludag University Faculty of Medicine, Turkey

Özet

Meme kitlelerinin çoğunluğu memeden kaynaklanan kitlelerdir. Meme metastazı nadir karşılaşılan bir durumdur. Meme derisi ve parankimi çeşitli tümörler için metastaz yeri olabilmektedir. Özellikle lösemi, akciğer kanseri ve malign melanom memeye metastaz yapabilen tümörlerdendir. Meme metastazı ilk semptom olabilmekle birlikte primer malignitesi olanlarda takipte ortaya çıkabilmektedir. Primer malign melanom tanısı olan hastalarda meme metastazı arasındaki süre ortalama 62 (13-178) ay olarak belirlenmiş. 7 vakalık bir çalışmada hematolojik nedenler (HL, NHL, Lösemi) ön planda iken 1 vakada malign melanom saptanmış. Memeye metastaz yapmış 15 vakalık malign melanoma serisinde sıklıkla primer tümör üst ekstremite ve gövde yerleşimli saptanmış. 256 vakalık bir konjunktival malign melanom serisinde mortalite sıklığı tümör derinliği >4 mm olanlarda belirgin yüksek saptanmış. 45 vakalık bir başka seride de tümör çapının > 10 mm olması yüksek mortalite ile ilişkili bulunmuş. Sonuç olarak primer malignitesi olan hastalardaki meme kitlesinin mutlaka primer- metastaz, malign-benign ayrımını için histopatolojik değerlendirilme yapılması gerekmektedir.

Anahtar Kelimeler

Malign Melanom; Meme Metastazı; Konjuktival Melanom

Abstract

Most breast masses arise from the breast. Metastasis to the breast is fairly uncommon, but can occur in breast skin and parenchyma. In particular, leukemia and lung cancers, and MM may metastasize to the breast. Breast metastasis might be the first symptom or may occur during the course of other malignancies. Our case presented with a fixed mass in the upper-medial quadrant of her left breast during regular follow-up visits. The mean time to breast metastasis in patients with MM is 62 months (13-178). In our case this time was 48 months. In a case series with 7 patients hematological malignancies (Hodgkin lymphoma, non-Hodgkin lymphoma, and leukemia) were the leading cause of breast metastasis, whereas in only 1 case the cause was MM. In another case series of 15 MM patients with metastasis to the breast, the primary tumor was frequently localized to the upper extremities and trunk. In a report of 250 conjunctival MM cases the mortality rate was significantly higher in patients with tumors >4 mm in vertical thickness. In another 45-case MM series tumors with a diameter >10 mm were associated with higher mortality rates. In our case the thickness of the tumor was 5 mm. In conclusion, histopathological evaluation should be mandatory in patients with known primary malignancies in order to differentiate new primary tumors, metastases, and benign tumors.

Keywords

Malign Melanoma; Breast Metastasis; Conjuctival Melanoma

DOI: 10.4328/JCAM.1137 Received: 06.06.2012 Accepted: 02.07.2012 Printed: 01.09.2015 J Clin Anal Med 2015;6(5): 682-683
Corresponding Author: Mustafa Canhoroz, Department of Medical Oncology, Fırat University, 23100, Elazığ, Turkey.
T.: +905052379326 F.: +904242388096 E-Mail: mcanhoroz@gmail.com

Introduction

Malignant melanoma (MM) arises from melanocytes, which give the skin its color. MM is the most serious skin cancer [2]. Ocular MM is a rare subtype; in 95% of cases ocular MM arises from the uvea, versus the conjunctiva in 5% [3]. Breast cancer is the leading cause of cancer-related mortality in females. MM metastasis to the breast is uncommon [1]. We report here a case of conjunctival melanoma presenting with breast metastasis.

Case Report

In December 2006, a 46-year-old female with a negative history of systemic disease presented with eye twitching. A dark red-violet mass located on the superior palpebral conjunctiva was observed on examination. The mass was excised along with 7-8 mm of adjacent tissue. Pathological examination showed a 1.5 × 0.5 × 0.3 cm malign melanoma with negative surgical margins. Detailed skin examination did not show any malignant or premalignant lesions.

The patient was treated with topical interferon therapy for 2 years. During regular follow-up visits no residual or recurrent lesion occurred. In December 2010 the patient presented with a fixed mass in the upper-medial quadrant of her left breast. Breast ultrasonography showed 3 lobulated contoured masses, including some cystic areas located at the 1 o'clock, 2 o'clock, and 4 o'clock positions, which were 14 mm × 8 mm, 31 mm × 13 mm, and 14 mm × 8 mm, respectively (Figure 1). Following a malignant needle biopsy result, she underwent mastectomy and axillary dissection (Figure 2). Histopathologic examination showed metastases of MM. Repeat skin examination did not show a metastatic source. During post-operative staging multiple liver metastases were also noted. The patient was given palliative temozolomide (150 mg/m2) + cisplatin (60 mg/m2) for 6 cycles. The disease remained stable for 7 months, and then progression of the liver metastases was observed and the patient was given paclitaxel (175 mg/m2) + carboplatin (6 AUC) for 4 cycles. Two months later new progression was detected and systemic chemotherapy was stopped. The patient was followed-up with best supportive care, but died 11 months post surgery.

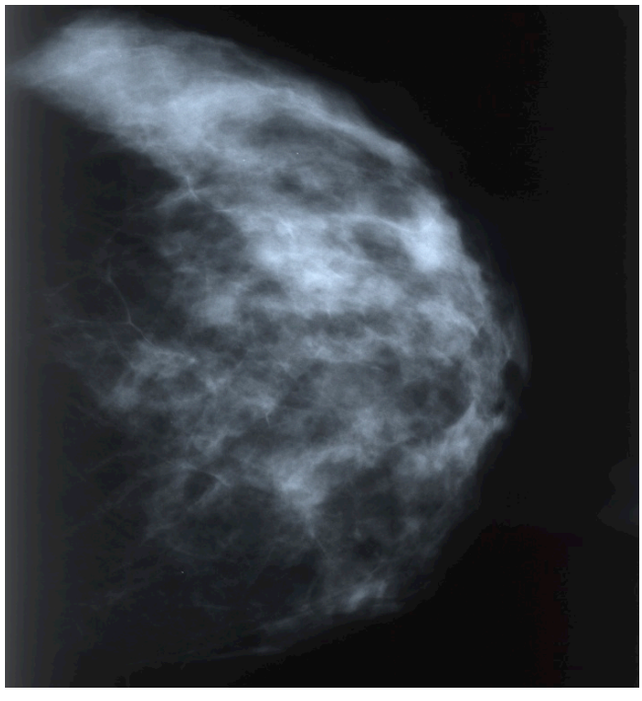

Figure 1. Mammographic image

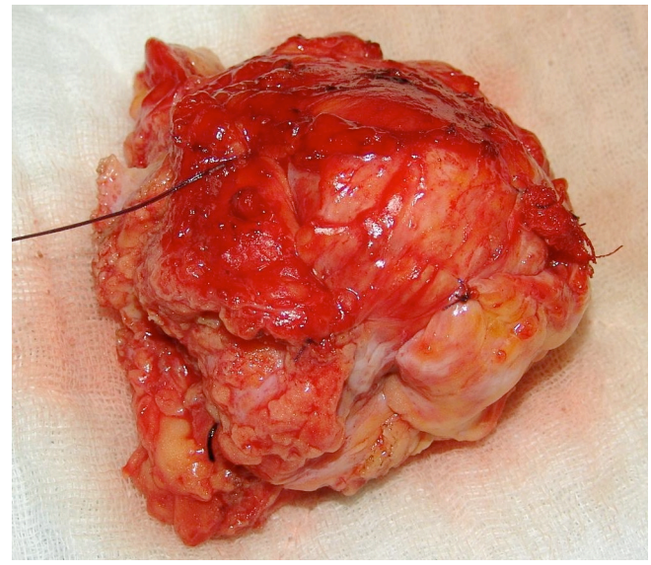

Figure 2. Macroscopic appearance of the tumor

Discussion

Most breast masses arise from the breast. Metastasis to the breast is fairly uncommon, but can occur in breast skin and parenchyma [1]. In particular, leukemia and lung cancers, and MM may metastasize to the breast [1]. Breast metastasis might be the first symptom or may occur during the course of other malignancies [1]. Our case presented with a fixed mass in the upper-medial quadrant of her left breast during regular follow-up visits.

The mean time to breast metastasis in patients with MM is 62 months (13-178) [3]. In our case this time was 48 months. In a case series with 7 patients hematological malignancies (Hodgkin lymphoma, non-Hodgkin lymphoma, and leukemia) were the leading cause of breast metastasis, whereas in only 1 case the cause was MM [1]. In another case series of 15 MM patients with metastasis to the breast, the primary tumor was frequently localized to the upper extremities and trunk [2]. In a report of 250 conjunctival MM cases the mortality rate was significantly higher in patients with tumors >4 mm in vertical thickness [3]. In another 45-case MM series tumors with a diameter >10 mm were associated with higher mortality rates [4]. In our case the thickness of the tumor was 5 mm.

In conclusion, histopathological evaluation should be mandatory in patients with known primary malignancies in order to differentiate new primary tumors, metastases, and benign tumors [4].

Competing interests

The authors declare that they have no competing interests.

References

1. Smymiotis V, Theodosopoulos T, Marinis A, Goula K, Psychogios J, Kondi-Pafiti A. Metastatic disease in the breast from nonmammary neoplasms. Eur J Gynaecol Oncol 2005;26(5):547-50.
2. Arora R, Robinson WA. Breast metastases from malignant melanoma. J Surg Oncol 1992;50(1):27-9.
3. Paridaens AD, Minassian DC, McCartney AC, Hungerford JL. Prognostic factors in primary malignant melanoma of the conjunctiva: a clinicopathological study of 256 cases. Br J Ophthalmol 1994;78(4):252-9.
4. Seregard S, Kock E. Conjunctival malignant melanoma in Sweden 1969-91. Acta Ophthalmol (Copenh) 1992;70(3):289-96.

How to cite this article:
Canhoroz M, Yoğurt İ, Gökgöz Ş, Topal U, Kanat Ö. A Case of Conjunctival Melanoma Presenting with Breast Metastasis. J Clin Anal Med 2015;6(5): 633-4.